

## Rectal Impalement with Bladder Perforation: An Unusual Injury

Shameer Deen, Rajiv Manek, Abhinav Mittal, K. M. Garg

Department of General Surgery

Mahatma Gandhi Medical College and Hospital

Mahatma Gandhi University of Health Sciences and Technology

Sitapura, Jaipur, Rajasthan, INDIA

---

**Abstract:** Impalement injury of the rectum with bladder perforation has been rarely reported. A high index of clinical suspicion is required to make the diagnosis of bladder perforation while assessing patients presenting with rectal impalement. Despite delay our case was successfully treated by staged surgery.

**Introduction:** Impalement injury is a specific type of trauma defined as a penetrating wound caused by an object with a blunt tip and is mostly related to falls, sexual activity and slipping with a strong external force. Combined rectal and bladder injuries after impalement remain a rare condition because of deep bladder position within the bony pelvis. Here in we present a case of successfully treated impalement recto-vesical injury.

**(Keywords:** Bladder Perforation, Laparotomy, rectal impalement)

---

### I. Introduction

#### Case report:

A 20 year old Hindu male, Mason helper was admitted to MGMCH, Jaipur on 14 Sept. 2014 with H/o forced sitting on a projecting iron rod 24 hours back. The iron rod was disengaged by the patient himself by doing standing maneuver followed by minimal bleeding per anum. Patient was hospitalized in nearby nursing home the same day and was catheterized and kept on conservative regime, but there was no urine in urobag even after 20 hours, so the catheter was removed which resulted in generalized pain all over abdomen and vomiting but patient still was unable to pass urine. After about 24 hrs of sustaining impalement injury he was referred to a higher centre and attended our emergency department in restless condition with pain all over the abdomen and non-passage of urine. On examination his pulse rate was 100 beats per minute with signs of dehydration and generalized peritonitis. Per rectal examination revealed an injury on anterior rectal wall about 3" from anal verge admitting finger pulp with blood on examining finger. Upright abdominal X-ray revealed free gas under both domes of diaphragm and ultrasonography abdomen showed evidences of free fluid in abdomen including Morrison's pouch.

Patient was resuscitated and after relevant investigations was taken for emergency surgery. Lower midline laparotomy revealed fecal contamination of peritoneal cavity along with intraperitoneal rupture of urinary bladder on posterior wall near dome. The index finger introduced in this injury detected another extraperitoneal injury in urinary bladder near neck.

Further when another hand finger introduced through rectal injury meeting of both fingers was possible. No injury in small bowel was detected. Repair of extraperitoneal bladder injury was done in two layers and extraperitoneal rectal injury loosely approximated by interrupted vicryl sutures. Suprapubic urinary diversion was done through intraperitoneal urinary bladder wound and diverting sigmoid colostomy done.

Patient had an uneventful post-operative recovery. Suprapubic catheter was removed at 4 weeks after normal RGU. Patient underwent closure of sigmoid colostomy after 3<sup>1/2</sup> months and was perfectly well when last seen at 2 weeks follow-up after closure of colostomy.

#### Comments:

Rectal impalement involves foreign body trauma which may enter directly or through the perineal region, resulting in intra or extraperitoneal rupture of the rectum and other organs, mainly of genitourinary tract. Knowing the mechanism, nature of impaling object, and direction of impact is important in predicting the potentially affected organs<sup>1</sup>.

The patient in context presented at our center approximately 48 hours after sustaining injury, due to ignoring of evidences of recto-vesical injury (i.e bleeding per anum at time of disengagement of iron rod and urinary trouble with hematuria.) and was thought to be an innocent penetrating injury initially at primary care level.

The other authors have also stated that special attention should be focused on the history of the patient<sup>2</sup> for the diagnosis of rectal impalement. If perforation is suspected, the rectum is examined under general anaesthetic with a finger and a speculum, particular attention being directed to the anterior wall<sup>3</sup>. Similarly a

high index of clinical suspicion is required to make a diagnosis of bladder perforation also while assessing patients presenting with rectal impalement<sup>4</sup>.

In case of complaints like abdominal pain and presence of tenderness on abdominal examination, an abdominal x-ray has to be performed to look for free gas under the diaphragm. Further radiologic and endoscopic investigations such as retrograde cystography, RU or cystoscopy for detecting abnormal communication between bladder and rectum may need to be done<sup>4</sup>. However, lack of physical findings or absence of radiographic findings does not exclude intra-abdominal injury or bladder perforation. It may be explained by the natural elasticity of the bladder wall and interlacing fibres of the detrusor which can prevent contrast extravasation.

Emergency laparotomy revealed fecal contamination of peritoneal cavity along with intra peritoneal rupture of posterior wall of urinary bladder near dome with no injury to small bowel detected. The route of fecal peritonitis in our patient was retrograde from rectal injury through urinary bladder to general peritoneal cavity. However, the extent of injury was limited due to the feet resting on the ground (Illustration 1 and 2). But careful evaluation of rectum, urinary bladder, vagina and abdominal visceral organs for occurrence of simultaneous injuries is being suggested<sup>5</sup>.

*Pubmed* search of literature found 12 reports with combined rectal and bladder injuries due to rectal impalement. The main reported symptoms referring to bladder perforation were urine drainage through rectum 35.7%, hematuria 21.4%, and inability to void 14.3%, while 28.6% did not declare any urinary symptoms at admission<sup>4</sup>.

Treatment standards for surgical management of combined penetrating rectum and bladder injuries remain undefined. The standard treatment of penetrating rectal trauma is inadequate in combined penetrating rectal and genitourinary tract injuries<sup>6</sup>. It is undeniable that diverting colostomy is highly recommended in the management of such type of injuries<sup>4</sup>.

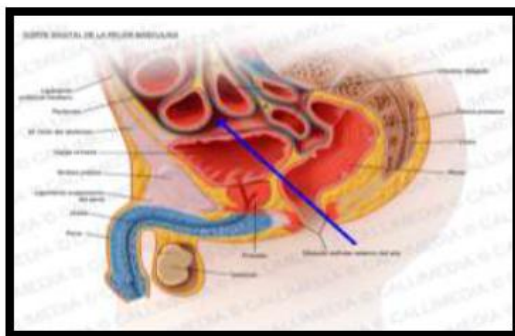


Illustration 1 : Showing route of impalement injury

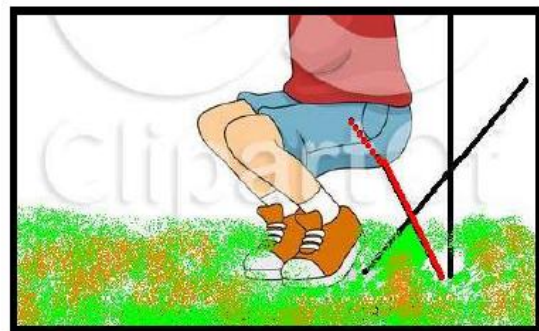

Illustration 2 : Showing extent of injury limited by feet resting on the ground

The experience of management of penetrating rectal injuries in civilian population continues to be based upon destructive injuries encountered during wartime conflict. The severity of tissue destruction in most civilian rectal injuries is minimal and the tenets of rectal injury management based upon wartime experience do not apply to nondestructive penetrating rectal injuries. Hence, Gonzalez et al (2006)<sup>7</sup> in their experience have suggested need for multi institutional randomized prospective study to assess the non-diversion approach to the management of these non-destructive penetrating rectal injuries.

Similarly treatment of bladder perforation is not standardized. A foley catheter for urinary decompression seems to be sufficient to treat extra-peritoneal bladder perforation, while laparotomy with defect suture is indicated when the diagnosis of intra-peritoneal bladder perforation is maintained. Control cystography should be performed after 10-14 days of urinary bladder drainage, and the catheter may be removed if there is no extravasation<sup>4</sup>. Because of the higher incidence of postoperative complications (fistula, urinoma, abscess) in the combined rectal and genitourinary gunshot injuries it has been suggested that these cases may benefit from placement of an omental interposition flap between the rectal and bladder repairs<sup>8,9</sup>. However, in low velocity injuries such as impalement this additional maneuver of placement of omental interposition flap between rectal and bladder repairs is not required.

A high index of clinical suspicion is required to make the diagnosis of bladder perforation while assessing patients presenting with rectal impalement. Painstaking preoperative assessment is the clue of successful management. Despite delay in treatment, our case was successfully treated by precise detection and restoration of organ damage and staged surgery.

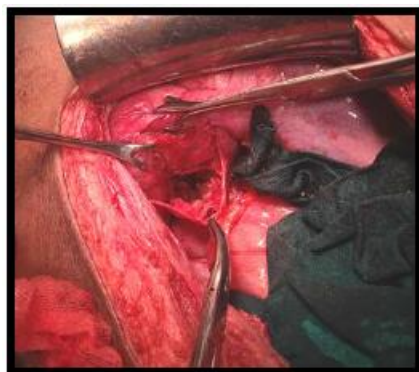

Photo 1: Intraoperative view showing bladder and rectal injuries.

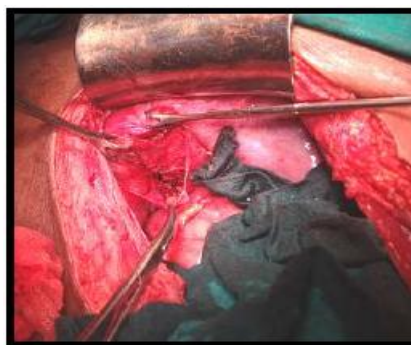

Photo 2: Intraoperative view showing repair of extraperitoneal bladder and rectal injuries.

### References

- [1]. Jona JZ. Accidental anorectal impalement in children. *PediatrEmerg Care.* 1997;13:40-3 (PubMed:9061736).
- [2]. Mammadov E, Altan A, Mehmet E and Sinan C. Self induced penetrating rectal perforation by foreign body: an unusual event in childhood. *Ann Pediatric Surg* 2011;7:25-26.
- [3]. Bailey & Love's: Short Practice of surgery 25<sup>th</sup> edition, edited by Norman S Williams, Christopher JK Bulstrode & P. Ronan O'Connell. 2008 Edward Arnold (Publishers) Ltd. London. Part 11. Abdominal chapter 68- the rectum. Page 1222.
- [4]. Benielloun EB, Youness Ahalal, Khalid Khatala et al. Rectal impalement with bladder perforation: A review from a single institution. *Urol Ann*, 2013 Oct-Dec; 5(4):249-254.
- [5]. Afshar MA, Mangele F and Nakheai A. A rare case of Anorectal injury with ruptured bladder and rectum but normal anal sphincter. *J clin case Rep* 2012, 2:14-1000204.
- [6]. Franko ER, Evatary RR, Schwalb DM. Combined penetrating rectal and genitourinary injuries: A challenge in management. *J Trauma.* 1993;34:347-53 (PubMed: 8483173)
- [7]. Gonzalez R, Herbert Phelan, Moustaffa Hassan et al. Is fecal diversion necessary for nondestructive penetrating extraperitoneal rectal injuries? *J Trauma.* 2006; vol 61(4):815-819.
- [8]. Crispin P, Kansas B, Pieri P et al. Immediate postoperative complications of combined penetrating rectal and bladder injuries. *J Trauma* 2007;62(2):325-329.
- [9]. Kuy SR, Codner PA, Guralnick M et al. Combined rectovesicular injuries from low velocity Penetrating trauma in an adult. *WMJ* 2013;112 (1):32-34.
- [10]. Shingo Oya, Kanji Miyata, Norihiro Yuasa et al. Impalement injury to left buttock with massive bleeding : a case report. *Nagoya J Med. Sci.* 2013;75,147-152.
- [11]. Kim S, Linden B, Cendron M, Puder M. Pediatric anorectal impalement with bladder rupture: Case report and review of the literature. *J Pediatric Surg* 2006;41:E 1-3