

Fetal Anomaly: Pentalogy of Cantrell

Sunita Nayak¹, Suren Prasad Dash², Muktikanta Khatua³

¹Tutor, Department of Anatomy, SCB Medical College, Cuttack, Odisha, India

²Consultant Radiologist, Sahara Diagnostics, Courtpeta Square, Berhampur, Odisha, India

³Assistant Surgeon, District Head Quarter Hospital, Koraput, Odisha, India

Abstract: Pentalogy of Cantrell (PC) is a lethal multiple congenital anomalies syndrome characterized by the presence of midline supraumbilical abdominal wall defect, lower sternal defect, diaphragmatic pericardial defect, anterior diaphragmatic defect and various cardiovascular malformations. This case report presents a female fetus at 17 weeks of conception who was diagnosed with Cantrell's Pentalogy by ultrasound. Ultrasonography showed that the fetal chest wall and anterior abdominal wall were not closed. Fetal heart was outside the chest cavity (Ectopia cordis); Liver and intestines were outside the abdominal cavity floating inside amniotic fluid (Omphalocele). Fetal spine showed multiple angulations (Kyphoscoliosis). No other anomalies were seen. The parents agreed for Medical Termination of Pregnancy. The abortus showed the five anatomical defects known for the complete form of Pentalogy of Cantrell. The mother was stable after abortion and was discharged uneventfully.

Keywords: Diaphragmatic defects, Ectopia Cordis, Omphalocele, Pentalogy of Cantrell, Thoraco-abdominal wall defect

I. Introduction

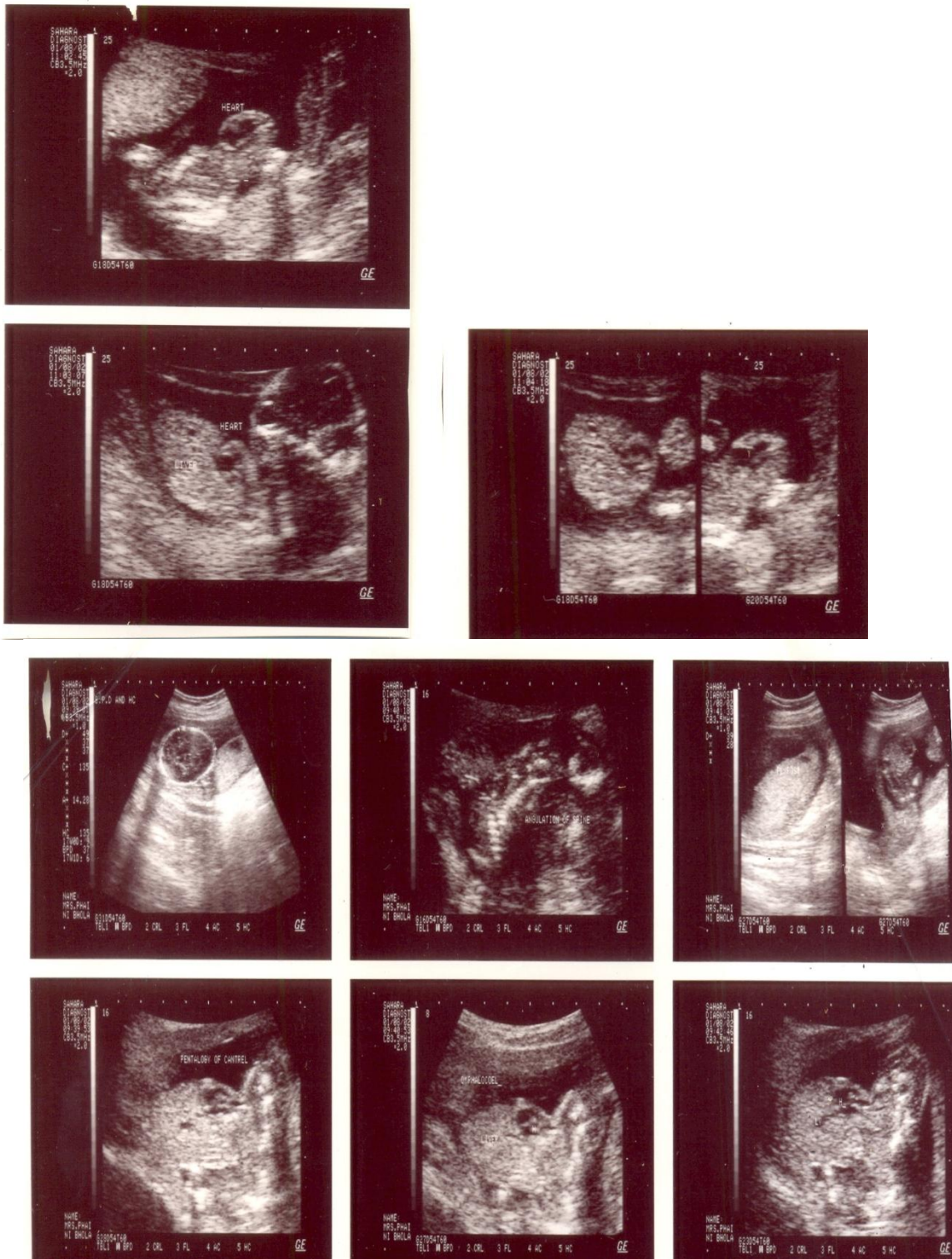
Cantrell in 1958 first described the full spectrum of PC and he reported 5 cases with this anomaly. A pentad of findings that included a defect of the lower sternum, a midline supraumbilical thoracoabdominal wall defect, a deficiency of the diaphragmatic pericardium, a deficiency of the anterior diaphragm and congenital cardiac anomalies was reported in these cases. The syndrome occurs sporadically with variable degrees of expression [1-3]. Many associated anomalies have been reported in fetuses with Pentalogy of Cantrell like cranial and facial anomalies, clubfeet, malrotation of the colon, hydrocephalous and anencephaly [4]. Prenatal diagnosis of PC is possible by ultrasonography depending on the size and extent of the defects.

II. Case Presentation:

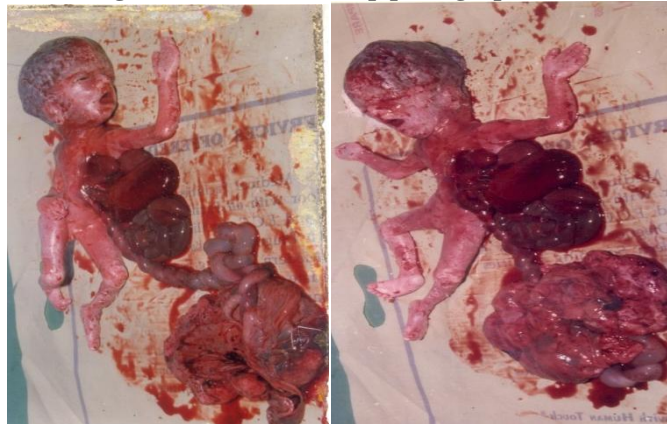
The patient was 18 years old primi at 17 weeks of gestation and of average body built. She had regular ANC starting from the 6th week of GA. She was given folic acid and doxylamine during her 1st trimester but patient had not taken regularly. She was immunized with one dose of Inj. T.T only and was not taking folic acid, iron and calcium regularly. She had normal abdominal girth as per Gestational age. She had no other complains during her Ante-Natal-Checkups. There was no history of hypertension, diabetes mellitus, renal disease or TB. There was no significant drug history also. She had regular menstrual history of 28-30 days cycle with 3-4 days of bleeding.

On examination, she had Pulse Rate of 86/min and Respiratory Rate of 42/min. Her weight was 45 kgs. Pallor present but Pedal edema absent, Heart and chest –NAD. Per Abdominal examination showed: Height of uterus normal and corresponded to GA; Liquor approximately normal and Fetal movement was felt. Investigation report said: Hb % - 13.2mg/dl; FBS -92mg.dl; VDRL-Non reactive; Blood group –‘O’ Rh+ve; Urine R/M – NAD. USG was done at -17 weeks which revealed: Single Intrauterine live fetus with cephalic presentation; AFI –Adequate; B.PD- 3.7 cm -17Weeks 01 day; HC – 13.5cm -17 weeks 00 day; AC – Could not be measured; FL - 1.6cm- 14 weeks 03 days; CGA=16 weeks 01 day. The anomalies detected were as follows: the fetal chest wall and anterior abdominal wall were not closed. Fetal heart was outside the chest cavity (Ectopia cordis); Liver and intestines were outside the abdominal cavity floating inside amniotic fluid (Omphalocele). Fetal spine showed multiple angulations (Kyphoscoliosis). No other anomalies were seen.

Fig. 1 shows the USG 2D images of Pentalogy of Cantrell



The pregnancy was terminated. Patient was stable (Post abortion) and was discharged uneventfully. The abortus findings were consistent with Ultrasonography findings.

Fig. 2 shows the follow up photographs:

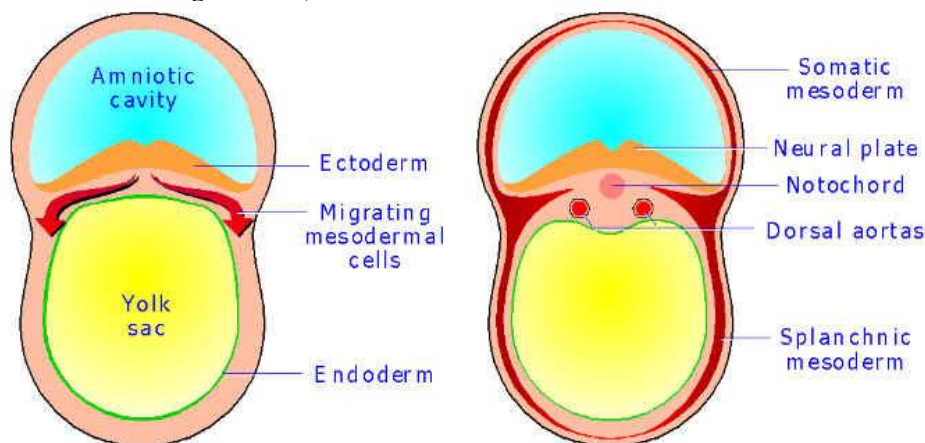
III. Discussion

Pentalogy of Cantrell is a rare congenital thoraco-abdominal disruption, first described by Cantrell et al with five characteristics: 1) Ectopia cordis and intracardiac anomalies; 2) Lower sternal defect; 3) Midline supraumbilical thoraco-abdominal wall defect; 4) Anterior diaphragmatic defect; 5) Defect of diaphragmatic part of pericardium that results in relation between pericardial cavity and peritoneum [1]. Prevalence of pentalogy of Cantrell (PC) is about 1 per 65,000 live births and classified as a developmental defect of midline anterior body wall. Complete form of pentalogy of Cantrell is a severe and rare syndrome but incomplete forms with combination of two or three defects were reported frequently [5]. Intracardiac anomalies that are almost always seen are VSD (in 100% of cases), ASD (52%), Pulmonary Stenosis (33%) and Tetralogy of Fallot (20%) [2].

3.1 Embryogenesis:

The sternum, abdominal wall, pericardium and part of the diaphragm arise from somatic mesoderm while the myocardium arises from splanchnic mesoderm. An event occurring prior to differentiation of the mesoderm into these two layers could produce defects in all of the involved structures as seen in pentalogy of Cantrell. Although a specific etiology is unknown, the timing of the event or insult would be between 14 and 18 days after conception [3]. The proposed embryogenesis postulates a failure of the lateral mesodermal folds to migrate to the midline (fig. 3), causing the sternal and abdominal defects; failure of the septum transversum to develop; causing defects in the anterior diaphragm and pericardium [6].

Fig. 3 During the third week of development, newly formed mesodermal cells migrate into the area of the germ disk, between the ectoderm and endoderm



3.2 Differential Diagnosis:

Isolated form of ectopia cordis, isolated abdominal wall defect, gastroschisis, amniotic band syndrome or body stalk anomaly. The syndrome should be considered with any diagnosis of omphalocele or ectopia cordis. If a diagnosis is made by ultrasound, chromosomal analysis is recommended. Associations with trisomy 18, trisomy 13, disrupted vessel defects and Turner's syndrome have been reported [7, 8]. Mutation of TAS gene which mapped at Xq25-q26.1 area is mentioned to have a role in fusion of sternum, multiple cardiac,

diaphragmatic and anterior wall defects. Carmi et al reported some cases of encephalocele and cleft lip with or without cleft palate, in association with abdominal wall defects such as pentalogy of Cantrell. In some cases of PC, aggregation of fluid in the chest and neck cavity was reported as a result of venous congestion because of cardiac failure, increased mediastinal pressure due to diaphragmatic herniation or Omphalocele. Abnormalities of the extremities are also reported in few cases. One study reported arthrogryposis, left thumb defect and shortening of left upper limb together with exencephaly. Peixoto-Filho et al mentioned that clubfoot was seen in few cases. Careful imaging should be done to rule out associated anomalies. Fetal echocardiography is indicated to evaluate the extent of any intracardiac abnormalities [8].

3.3 Ultrasonographic Diagnosis:

Intrauterine diagnosis of this pentalogy is impossible before 12th week of gestation, since herniation of bowel out of abdomen is a normal event in fetal development at this time, but after that ultrasonography is a useful method even in the first trimester. The sternal defect can range from absence of the xiphoid process to cleaving, shortening, or absence of the entire sternum. The abdominal defect can range from a wide rectus muscle diastasis to a large omphalocele. The most common intracardiac defects are atrial septal defect, ventricular septal defect, and tetralogy of Fallot. Both 2D and 3D obstetric ultrasonography are recommended, but 3D ultrasonography is not necessary in first trimester. Other diagnostic methods including CT-Scan and MRI can be used for confirmation.

3.4 Prognosis:

Prognosis of pentalogy of Cantrell depends on the severity of intra and extra cardiac defects, pulmonary hypoplasia, extent of abdominal wall defect, cerebral anomalies and diaphragmatic herniation. The mean survival rate without any interventional surgery is about 36 hours [9]. Studies showed that even with care, monitoring in professional centers and multiple corrective surgeries, they had high morbidity and mortality rate and long time prognosis is poor.

IV. Conclusion

In view of the poor prognosis, termination of pregnancy can be considered if ultrasonic diagnosis is made before viability. In patients choosing to continue the pregnancy, there is no data indicating improved or changed outcome with cesarean delivery [10]. After delivery, repair of the omphalocele should not be delayed. Repair of the sternal, diaphragmatic, and pericardial defects can be attempted at the same time. Surgical correction is often difficult secondary to hypoplasia of the thoracic cage and inability to enclose the ectopic heart. Some affected infants have respiratory insufficiency secondary to pulmonary hypoplasia. Recognition and treatment of any intracardiac anomaly is important, as congenital heart disease is a source of major morbidity in infants surviving the neonatal period.

References

- [1]. Toyama WM: Combined congenital defects of the anterior abdominal wall, sternum, diaphragm, pericardium, and heart: a case report and review of the syndrome. *Pediatrics* 50:778-792, 1972.
- [2]. Baker ME, Rosenberg ER, Trofatter KF et al: The in utero findings in twin pentalogy of Cantrell. *J Ultrasound Med* 3:525-527, 1984.
- [3]. Cantrell JR, Haller JA, Ravitch MM: A syndrome of congenital defects involving the abdominal wall, sternum, diaphragm, pericardium, and heart. *Surg Gynecol Obstet* 107:602-14, 1958.
- [4]. Fox JE, Gloster ES, Mirchandani R: Trisomy 18 with Cantrell Pentalogy in a Stillborn Infant. *American Journal of Medical Genetics* 31:391-394, 1988.
- [5]. Amir Hossein Jafarian,^{a,*} Abbas Ali Omid,^a Alireza Fazel,^b Hamed Sadeghian,^a and Bahareh Joushan^c *J Res Med Sci.* 2011 Jan; 16(1): 105–109
- [6]. Sabrina D. Craig, MD, Martin S. Gillieson, MD, Curtis L. Cetrulo, MD 1992-07-21-17 Pentalogy of Cantrell © Craig
- [7]. Haynor DR, Shuman WP, Brewer DK: Imaging of fetal ectopia cordis: roles of sonography and computed tomography. *J Ultrasound Med* 3:25-27, 1984.
- [8]. Bryke CR, Breg WR: Pentalogy of Cantrell. from Buyse, M.L., *Birth Defects Encyclopedia*. Blackwell Scientific Publications 1375-76, 1990
- [9]. Abu-Yousef MM, Wray AB, Williamson RA, Bonsib SM: Antenatal Ultrasound Diagnosis for Variant of Pentalogy of Cantrell. *J Ultrasound Med* 6:535-538, 1987.
- [10]. Ghidini A, Sirtori M, Romero R, Hobbins JC: Prenatal Diagnosis of Pentalogy of Cantrell. *J Ultrasound Med* 7:567-572, 1988.