

## Capillary Haemangioma or Pyogenic Granuloma of Nasal Septum in an Adolescent Male: A Diagnostic Dilemma- Case Report and Review of Literature

Dr. Anuja Bhargava<sup>1</sup>, Dr. Rajeev Krishna Gupta<sup>2</sup>, Dr. Sayyad Yasir Yazdani<sup>3</sup>,  
Dr. Satveer Singh Jassal<sup>4</sup>.

<sup>1</sup> (Assistant professor, Department of ENT, Era's Lucknow Medical college, Lucknow, India)

<sup>2,3,4</sup>. (Resident, Department of ENT, Era's Lucknow Medical college, Lucknow, India)

**Abstract:** Nasal lobular capillary haemangioma is benign, vascular lesion commonly affecting skin, mucosa of oral cavity, tongue and rarely nasal cavity mucosa. It commonly occurs following traumatic or hormonal changes particularly in pregnancy. We present a case of young male who presented with left nasal mass along with episodes of left nasal bleed for 3 months. Mass was excised and sent for histopathological examination, which confirmed it to be lobular capillary haemangioma. Our case gathers significance due to its presentation in an adolescent male and we stress to keep capillary haemangioma as differential diagnosis in a bleeding nasal mass.

**Keywords:** Lobular capillary haemangioma; Pyogenic granuloma; Nasal obstruction.

### I. Introduction

Haemangioma is a developmental malformation of blood vessel and are of mainly 3 types: (1) Capillary haemangioma (2) Venous or cavernous haemangioma (3) Arterial and plexiform haemangioma. Lobular Capillary haemangioma commonly affects skin, mucosa of oral cavity, tongue and rarely nasal cavity mucosa [1,2]. In nasal cavity the commonest site is nasal septum [3,4]. Possible etiological factors include microtrauma from nasal packing, prolonged intubation, hormonal changes particularly in pregnancy. Nasal lobular capillary haemangioma can occur in children of 10 months to adults in their 7<sup>th</sup> decade with mean age of occurrence being around the 4<sup>th</sup> decade. It occurs more often in females around 4<sup>th</sup> decade. The incidence increases by about 5% during pregnancy [5]. We present a case of 16 year old male who presented with left nasal mass along episodes of left nasal bleed for 3 months.

Patients of lobular capillary haemangioma present with episodes of nasal bleed and varying degrees of nasal obstruction depending on size of mass. Treatment includes excision of mass along with surrounding mucoperichondrium. Diagnosis is confirmed by HPE of excised specimen. These lesions show benign capillary proliferation with distinct lobular architecture and the stroma may be fibro-myxoid/oedematous with acute and chronic inflammation.

### II. Case Report

A 16 yr old male from rural area of Lucknow presented to our OPD with progressive, painless, left nasal mass along with episodes of left nasal bleed for 3 months. There were 1 to 2 episodes of nasal bleed/week and each episode about 30ml of blood was lost. There was history of nasal pricking. There was no history of excessive sneezing, itching and nasal instrumentation.

Local examination revealed a reddish brown mass in left nasal cavity occluding more than half of nasal cavity [Fig 1]. The mass was soft to firm in consistency, sessile, non-pulsatile, non-tender and bleeds on manipulation. Rest of ENT examination was within normal limit. There was no significant lymphadenopathy. Routine Haematological investigation were within normal limits. Contrast enhanced CT Scan of Nose and PNS revealed a soft tissue enhancing mass in left nasal cavity [Fig 2].

Mass was excised along with 1 cm margin of nasal mucosa and haemostasis was achieved by cauterization and anterior nasal packing. Pack was removed after 24 hrs. Diagnosis of Lobular Capillary haemangioma was confirmed on HPE [Fig 3]. Post-operative period was uneventful. Patient was followed for 3 months with no signs of recurrence.

### III. Discussion

Lobular Capillary Haemangioma also known as pyogenic granuloma, is a benign vascular lesion. The term Pyogenic granuloma is a misnomer as it is neither infectious nor granulomatous. Lobular capillary haemangiomas were first described by Poncet and Dor in the year of 1897 where they referred to these tumors as small vascular tumors in the fingers of 4 patients [6]. First case of Lobular Capillary Haemangioma of the nasal cavity was described in 1940 by Frank I, and Blahd M. In 1980, Mills et al. termed pyogenic granuloma as lobular

capillary haemangioma due to its characteristic microscopic features[1]It should be considered in differential diagnosis of unilateral bleeding lesion in nasal cavity.

It is commonly seen in oral cavity especially on gingival but rarely in nasal cavity[2].Common etiological factors are local trauma to skin or mucous membrane ,hormonal factors which includes pregnancy, females on oral contraceptive pills.

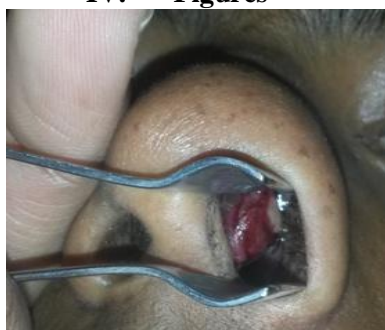Clinical presentation includes unilateral epistaxis with obstructive reddish brown mass in nasal cavity as described in previous literatures[7,8]Pathologically,the lesion is characterized by varying sized capillaries in a lobular arrangement,often surrounded by a central caliber vessel[3]

Differential diagnosis includes Wegener's granulomatosis, Rhinosporidiosis, Haemangiosarcomas, Angiosarcomas, Kaposi's Sarcomas,Proliferating pilomatricoma, Bacillary angiomatosis, Malignant melanoma (particularly in children), Pseudo-Kaposi's sarcoma (acroangio-dermatitis) and Recurrent intravascular papillary endothelial hyperplasia (Masson's lesion). [9]

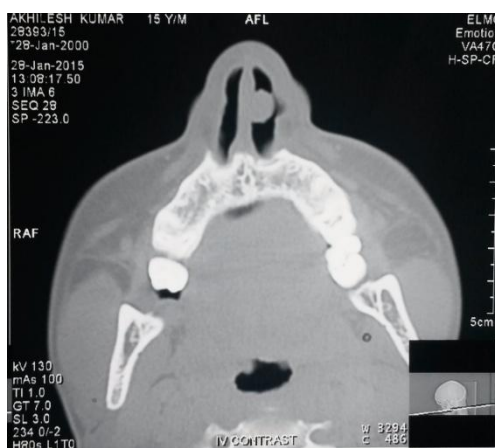Pyogenic granuloma is commonly seen in anterior aspect of nasal septum,though it has been reported from other endonasal sites which includes the vestibule,middle turbinate and posterior part of septum[3,4].Malignant transformation of this lesion has not been reported and recurrence is uncommon[10]

Treatment of lesion is excisional biopsy with surrounding cuff of mucoperichondrium.Diagnosis is confirmed by histopathological examination of excised sample.

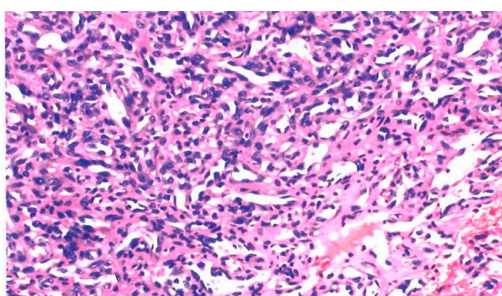
#### IV. Figures



**Fig 1** Left sided Nasal mass seen on anterior rhinoscopy



**Figure 2** Nasal mass seen on CT nose and PNS



**Figure 3** HPE slide of excised sample diagnostic of capillary haemangioma

## V. Conclusion

This case is reported due to its potential for misdiagnosis. A high index of suspicion with proper history and thorough examination can help in making diagnosis. It can be confirmed on HPE of excised sample. It can be concluded that lobular capillary haemangioma should be kept in the differential diagnosis of patient presenting with nasal mass and bleeding.

## References

- [1]. Mills SE, Cooper PH, Fechner RE: Lobular capillary haemangioma; the underlying lesion of pyogenic granuloma. A study of 73 cases from the oral and nasal mucous membrane. *Am J Surg Pathol* 1980, 4:470-479.
- [2]. Ozcan C, Apa DD, Gorurk: Paediatric lobular capillary hemangioma of the nasal cavity. *Eur Arch Otorhinolaryngol* 2004, 261:449-451.
- [3]. Kartaran H, Uraldi C, Ark N, Aktas D: Lobular capillary hemangioma of the middle turbinate. *Acta Otolaryngol* 2006, 126:442-444.
- [4]. Neves-Pinto RM, Carvalho A, Araujo E, Alberto C, Basilio-De-Oliveira, De Carvalho GA: Nasal septum giant pyogenic granuloma after a long lasting nasal intubation; Case report. *Rhinology* 2005, 43:66-69.
- [5]. Park YW. Nasal granuloma gravidarum. *Otolaryngol Head Neck Surg* 2002; 126: 591-2.
- [6]. Poncet A, Dor L, Botryomycose Humaine *Rev Chir (Paris)* 1897;18:996.
- [7]. Puxeddu R, Berlucchi M, Ledda GP, Parodo G, Farina D, Nicolai P: Lobular capillary hemangioma of the nasal cavity: A retrospective study of 40 patients. *Am J Rhinol* 2006, 20:480-484.
- [8]. Sheen TS, Ko JY, Hsu YH: Pyogenic granuloma – an uncommon complication of nasal packing. *Am J Rhinol* 1997, 11:225-227.
- [9]. Lee HM, Lee SH, Hwang SJ. A giant pyogenic granuloma in the nasal cavity caused by nasal packing. *Eur Arch Otorhinolaryngol* 2002;259:231-3.
- [10]. Genç S, Sürkçuoğlu S, Karabulut K, Acar B, Tunçel U, Degerli S: Giant Lobular Capillary Hemangioma of the Nasal Septum. *Turk J Med Sci* 2009, 39:325-328.