

Cholesteatoma in Klippel-Feil Syndrome; A Case Report

Dr. Pinpo Teron¹, Dr. Sandeep Vijay², Dr. Debajit Sarma³

¹(Assistant Professor, Department of E.N.T., Head & Neck Surgery, Assam Medical College & Hospital, India)

²(Postgraduate Trainee, Department of E.N.T., Head & Neck Surgery, Assam Medical College & Hospital, India)

³(Registrar, Department of E.N.T., Head & Neck Surgery, Assam Medical College & Hospital, India)

Abstract: Klippel-Feil syndrome (KFS) is characterized by a short neck with decreased movements and low posterior hairline. It occurs due to the failure of segmentation of cervical vertebrae during development. Deafness is a well known associated feature and may be of sensorineural, conductive or mixed type. Several otological abnormalities have been noted with these patients for e.g. external ear anomalies, cochlear anomalies and ossicular chain deformities. We hereby present a case report on Klippel-Feil Syndrome; a 25 year old female with restricted neck movements, LMN Facial palsy, absent pinna & chronic ear discharge with radiological findings such as Cholesteatoma, absent bony vestibule, semicircular canals, and cochlea and with Partial Atlanto-Occipital fusion & Hemivertebra at various levels (D3-D6) Canal-Wall down mastoidectomy procedure was undertaken with intraoperative Cholesteatoma debris & destruction of ossicles seen.

Keywords- Cholesteatoma, Klippel-Feil Syndrome

I. Introduction

Klippel-Feil syndrome (KFS) is characterized by short neck with decreased movements and low posterior hairline; it occurs due to failure of segmentation of cervical vertebrae during development. Incidence of this syndrome is 1 in 40,000 and 3 types are recognized:

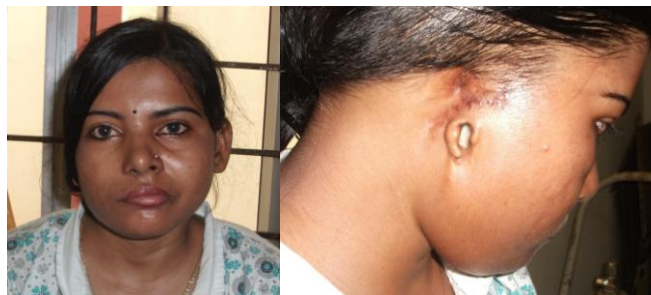KFS TYPE	CLINICAL FEATURES	INHERITANCE	MUTATION
I	Massive cervical fusion, may involve upper thoracic vertebrae	Autosomal Dominant	GDF6 gene on chromosome 8q22
II	Fusion at 1 or 2 interspaces, maybe associated with other vertebral anomalies- for e.g. Hemivertebrae	Autosomal Recessive	MEOX1 gene on chromosome 17q21
III	Fusion of cervical and lower thoracic vertebrae	Autosomal Dominant	GDF3 gene on chromosome 12p13

The inheritance and associated anomalies (Sprengel shoulder, cleft palate, cardiac, renal abnormalities, developmental delay etc) vary with the type of KFS. Deafness is a well known associated feature and may be of sensorineural, conductive or mixed type. Several otological abnormalities have been noted with these patients for e.g. external ear anomalies, cochlear anomalies and ossicular chain deformities.

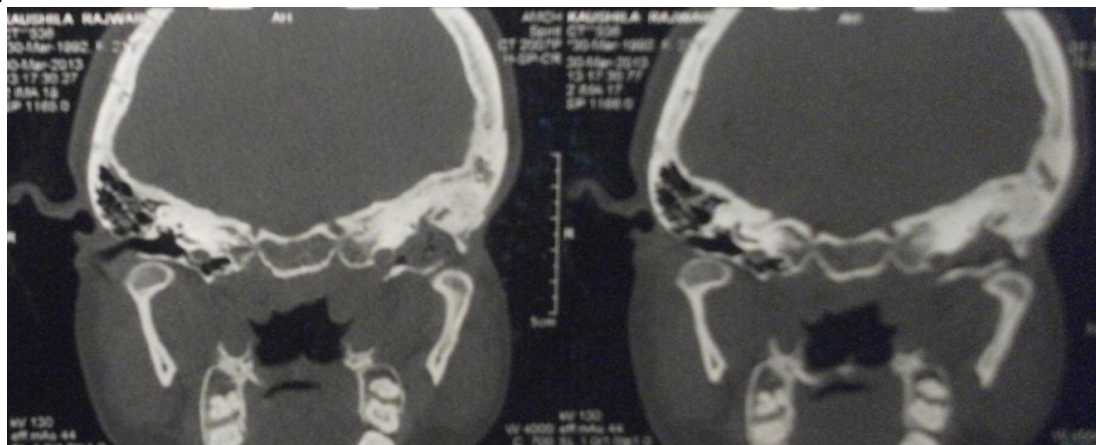
II. Case Report

A 21 year old female presented with intermittent episodes of foul smelling, mucoid discharge from right ear since childhood with absent hearing and no episodes of pain, tinnitus, and vertigo. The patient had undergone ear surgery 10 years ago of which no details are available.

On Examination: she revealed a short neck with right lower motor neuron type of facial palsy. Also absent pinna on right side and a scar of previous surgery 3cm posterolateral to the external auditory canal was present. The external auditory canal was found to be narrowed with no remnants of tympanic membrane seen. Cholesteatomatous debris was found in the middle ear on microscopic examination.

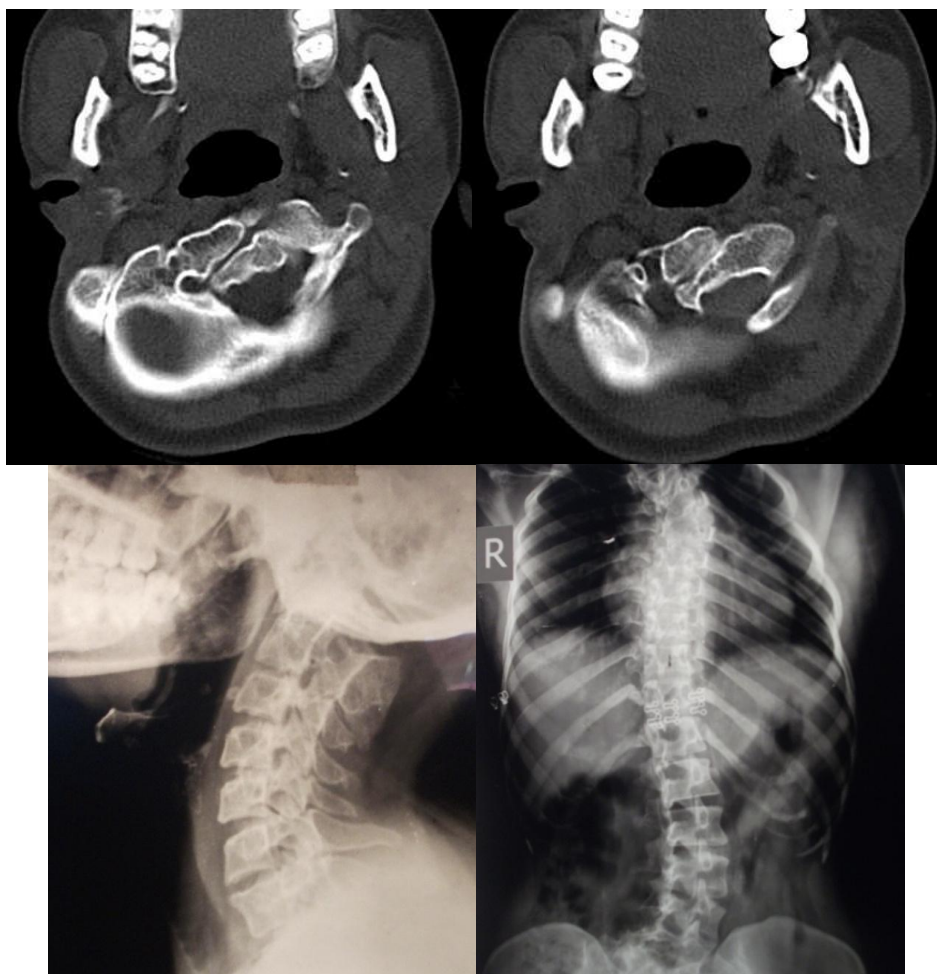


CT Scan of Tympanomastoid region revealed Right chronic otitis media of unsafe type (Cholesteatoma) with right sided chronic mastoiditis, Absent bony vestibule, semicircular canals, cochlea and Absent pinna on right side.



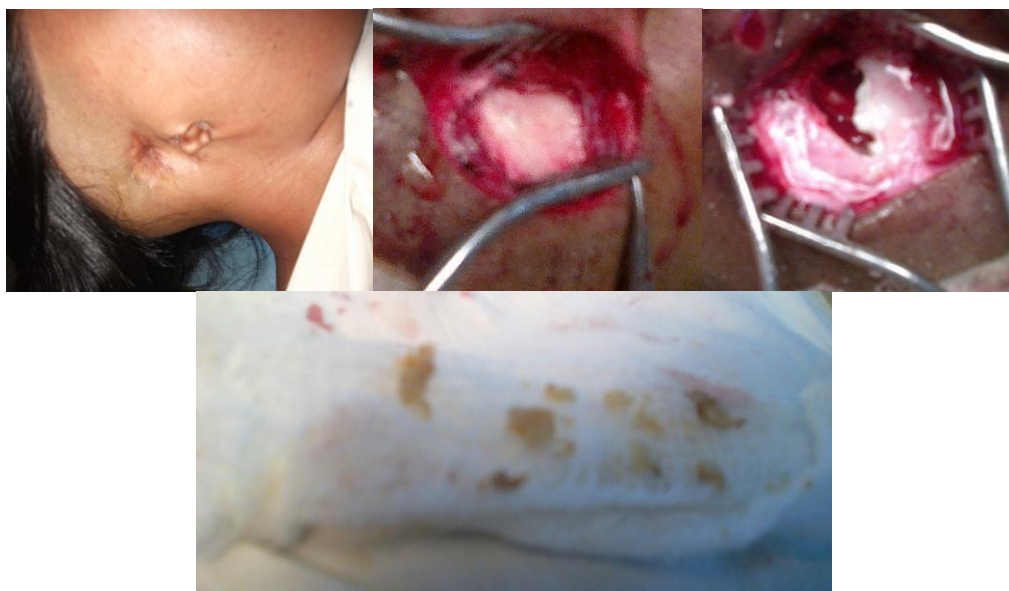Radiological evaluation of the Spine showed:

- Partial Atlanto-Occipital Assimilation with Basilar Invagination of odontoid process with mild anterior rotatory atlantoaxial subluxation
- Scoliotic deformity of upper dorsal spine noted with convexity towards left
- Hemivertebra noted at various levels of upper dorsal spine (D3-D6)
- Angulation of posterior end of ribs noted at left side at D3-D4 levels
- Left lateral wedging of D2 vertebra noted
- Rotational deformity of DL Spine noted with increasing severity caudally (Nash Moe Grade 4)



As fusion of vertebrae is restricted to the Atlanto-Occipital joint, the patient was classified as **Type 2 KFS**.

Surgery: Mastoid Exploration of the right ear was done. Cholesteatomatous debris was found to occupy the whole of mastoid and middle ear cavities. No remnants of ossicles or tympanic membrane were found. As posterior canal wall was already found to be lowered, the diseased material was removed and cavity left open for further inspection and cleansing.



Postoperative period was uneventful.

Orthopedic & Neurologic consultations were taken to rule out any progressive deformities and impending deficits.

III. Discussion

In 1912, Maurice Klippel and Andre Feil described a syndrome that is clinically characterized by a short neck with restricted mobility and a low hairline. It is believed to be caused by faulty segmentation of the mesodermal somites, occurring between 3rd and 4th week of embryonic development. Although usually sporadic, some cases are Autosomal Dominant. Female to male ratio is estimated to be 1.3:1.

The most common type of KFS seen is Type 1. Type 2 probably is more common in the population but patients have minimal clinical manifestations and are diagnosed only by radiography.

A number of anomalies are associated with KFS including cardiac and renal anomalies, developmental delay, and limb defects. Scoliosis is a frequent finding, seen in up to 60%.

The diagnosis of Klippel-Feil syndrome rests on radiographic demonstration of fused cervical or cervicothoracic vertebrae, hemivertebrae, or atlanto-occipital fusion.

Audiological abnormalities are also common with reports of association with hearing loss to be up to 50%. All types of hearing problems have been described in the syndrome but bilateral sensorineural loss is most common. The next most common problem is mixed hearing loss followed by conductive hearing loss. Several otological abnormalities have been noted with these patients ranging from nonspecific external ear abnormalities to severe developmental anomalies of the cochlea.

- External ear anomalies include narrow external auditory meati, preauricular skin tags, and small ears.
- Inner ear changes include absent vestibules and semicircular canals. Cochlear abnormalities include total absence of the cochlea, decreased number of coils, and a Mondini anomaly.
- Ossicular chain abnormalities are also described. These include deformed or absent ossicles, malformed or fixed stapes, and fusion of components.

Audiological abnormalities are present in a significant number of patients with KFS. Establishing the degree and type of hearing loss should be an integral part of the management of such patients.

Follow up with repeat audiological assessment should also be considered.

Patients with KFS may need to attend specialty clinics, including orthopedics, cardiology, nephrology, or neurology. It is important for others involved in their care to be aware of the strong association with hearing problems and ensure formal audiological testing is undertaken.

Some cases with profound hearing impairment need further assessment to ascertain the feasibility of cochlear implantation or whether other modes of auditory rehabilitation such as surgical intervention can be undertaken.

IV. Conclusion

Klippel-Feil Syndrome is a rare clinical entity that shows multiple system abnormalities. Type 2 KFS doesn't necessarily present with the typical severe restriction of neck movements, hence it is important to identify this condition when a patient presents with congenital ear defects.

Apart from restoring the hearing impairment it is also necessary to correct the orthopedic ailments (cervical spine instability, spinal stenosis) to prevent neurologic deficits in future.

References

- [1]. J M McGaughran, P Kuna, V Das. Audiological Abnormalities in Klippel-Feil Syndrome. Arch Dis Child; 79:352-355
- [2]. Robert N Hensinger, John E Lang, Dean Macewan. Klippel-Feil Syndrome, A Constellation of Associated Anomalies. J Bone Joint Surg Am; 56:1246-1253
- [3]. Yildirim N, Arslanoglu A, Sahan M. Klippel-Feil Syndrome and Associated Ear Anomalies. Am J Otolaryngol; 29:319-25
- [4]. R T Miyamoto, H Y Yune. Klippel-Feil Syndrome and Associated Ear Deformities. The American Journal of Otology; 5(2):113-9.