

The use of non-rigid connectors in fixed partial dentures with pier abutment: A Case report.

Dr. Monjula Das¹, Dr. Silpi Jalan², Dr. Kadambari Bharali³

¹(Reader, Department of Prosthodontics, Regional Dental College, Guwahati)

²(Lecturer, Department of Prosthodontics, Regional Dental College, Guwahati)

³(Post Graduate Student, Department of Prosthodontics, Regional Dental College, Guwahati)

Abstract: The occlusal forces applied to a fixed partial denture are transmitted to the supporting structures through the pontic, connectors and retainer. Rigid connectors between pontics are preferred way of fabricating most fixed partial dentures as they provide desirable strength and stability to the prosthesis. But it has been theorized that forces are transmitted to the terminal retainers as a result of the middle abutment acting as a fulcrum, causing failure of the weaker retainer. It has also been suggested that the intrusion of the abutments under the loading could lead to failure between any retainer and its respective abutment. To reduce this hazard, the use of nonrigid connector has been recommended as it acts as broken-stress mechanical union of retainer and pontic, instead of usual rigid connector.

Key Words: Connector, Pier abutment, Mortise, Tenon, Non-rigid connector

I. Introduction

The occlusal forces applied to a fixed partial denture are transmitted to the supporting structures through the pontic, connectors, and retainers. Factors that influence the longevity of a fixed partial denture and its abutment include occlusion, span length, bone loss, and quality of periodontium. Biomechanical factors such as overload, leverage, torque, and flexing induce abnormal stress concentration in a fixed partial denture. Stress concentration is found in the connectors of the prosthesis and in the cervical dentin area near the edentulous ridge¹. Connectors, the portion of a fixed dental prosthesis that unites the retainer(s) and pontic are considered as heartthrob of abutments, since under occlusal load maximum stresses are concentrated on them. Selection of the right type of can make a real difference between success and failure. We are more accustomed to the use of rigid connector in clinical practice since its placement requires minimum technical and laboratory expertise².

But the real problem arises when we encounter a pier abutment². Natural tooth located between terminal abutments that serve to support a fixed or removable dental prosthesis is known as pier abutment³. Restoration of 2 missing teeth and an intermediate pier abutment with a rigid fixed partial denture is not an ideal treatment. When an occlusal load is applied to the retainer on the abutment tooth at 1 end of a fixed partial denture with a pier abutment, the pier abutment may act as a fulcrum. Thus, tensile forces may then be generated between the retainer and abutment at the other end of the restoration. Anterior or posterior abutments may experience extrusive forces during fulcrum action, and resultant tensile force at the retainer to abutment interface may result in potential loss of retention for these restorations⁴. It has been reported that rigid fixed partial dentures with pier abutments are associated with higher debonding rates than short-span prostheses. Thus, these restorations may result in marginal leakage and caries. Nonrigid connectors are suggested as a solution to these difficulties⁴.

Indications of non-rigid connector

The indications for the use of nonrigid connector in fixed prosthodontics are⁵:

1. The existence of Pier abutment, which promote a fulcrum-like situation that can cause the weakest of the terminal abutments to fail and may cause the intrusion of the pier abutment.
2. The existence of the malaligned abutment, where parallel preparation might result in devitalisation. Such situation can be solved by the use of Intracoronal attachments as connectors.
3. The presence of mobile teeth, which need to be splinted together with fixed prosthesis
4. Long span, fixed partial dentures which can be distort due to shrinkage and pull of porcelain on thin sections of framework and thus, affect the fitting of the prosthesis on the teeth. The nonrigid connectors are mainly used to relieve stress on the abutment and to accommodate malaligned fixed partial denture.

Types of Non-Rigid Connectors

The four types of nonrigid connectors are the:

1. Dovetail(key-keyway) or Tenon-Mortise type connectors.

2. Cross-pin and wing type connector.
3. Split type connector.
4. Loop type connector

This clinical report describes the prosthodontic management of an edentulous span on both sides of a pier abutment, with fixed partial denture having a non-rigid connector.

II. Case Report

A 40 year old female patient was referred to the Department of prosthodontics, Regional Dental College, Guwahati, Assam with the chief complaint of the inability to masticate and unpleasant aesthetics. The intraoral examination revealed missing maxillary right first premolar and first molar. Intra oral periapical radiograph showed good bone support for all the teeth to be used as abutment.

The treatment options available to the patients were:

- a. Implant in edentulous spaces.
- b. Fixed partial denture with rigid connector.
- c. Fixed partial denture with non-rigid connector.

The patient did not agree for the implant due to surgical intervention and financial constrains. The treatment of the patient with Fixed Partial Denture with rigid connector would have resulted in detrimental effect on abutments as well as the final prosthesis. Hence, it was decided to do restoration with fixed partial denture with nonrigid connector of Tenon-Mortise type.)

Technique

Step by step procedure:

1. The tooth preparation of canine, second premolar and molar was done for metal-ceramic fixed partial denture and non-rigid connector between the second premolar and first molar. The distal of the second premolar was prepared to accommodate a non-rigid connector (Fig 1).
2. Putty-wash impression (3 M ESPE) was made (Fig 2)for the preparation of the working model. It was poured in high-strength die stone (Kalabhai Karson Pvt.Ltd.).
3. Provisional restoration was cemented(Fig 3).
4. Fixed partial denture with non-rigid connector was prepared. First, the anterior segment of canine, first premolar and second premolar withthe keyway (Mortise) on its distal aspect was fabricated. Then the second and the first molars with key (Tenon) on its mesial aspect was fabricated in wax and then cast.
5. Accurate alignment of mortise is crucial, it must be parallel to path of placement of distal retainer. This is accomplished with a dental surveyor.
6. After casting, metal try-in of the individual units were done to verify proper seating(Fig 4). Then ceramic layer was added (Fig.5).
7. At the time of cementation, mesial segment was placed first followed by cementation of distal segment (Fig 6,7,8).

III. Figures

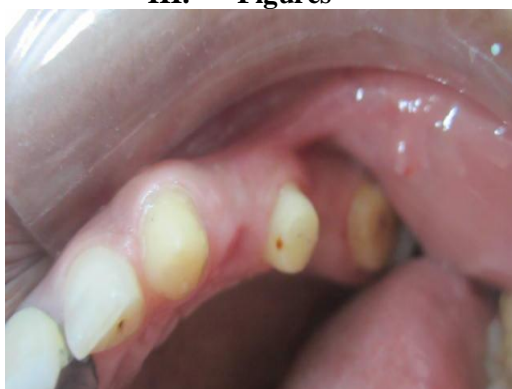

Figure: 1 Tooth Preparation

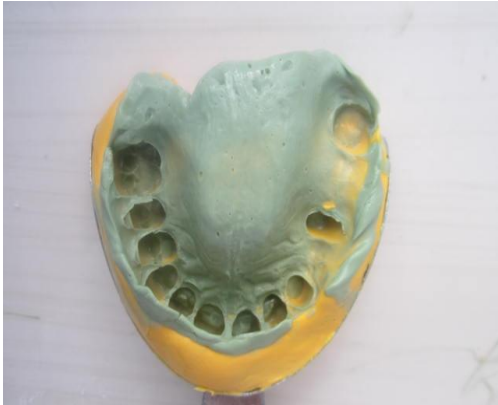

Figure: 2 Final Impression

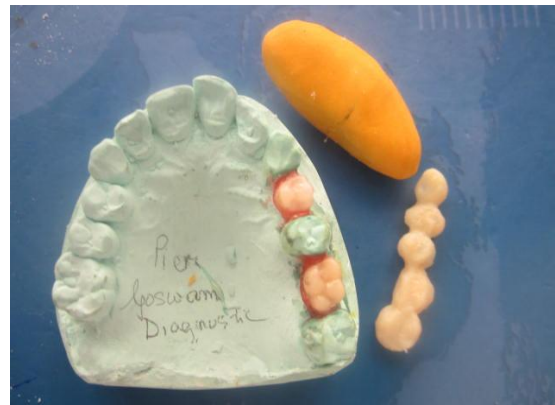

Figure : 3 Temporization

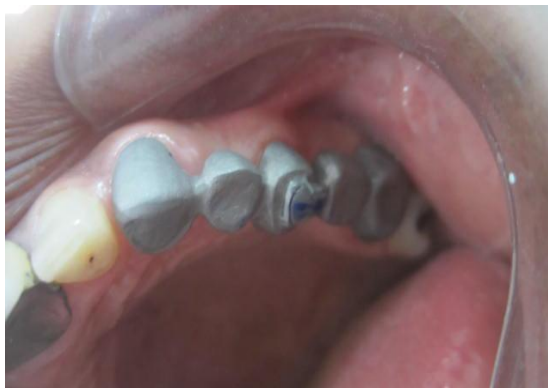

Figure : 4 Metal Try-In

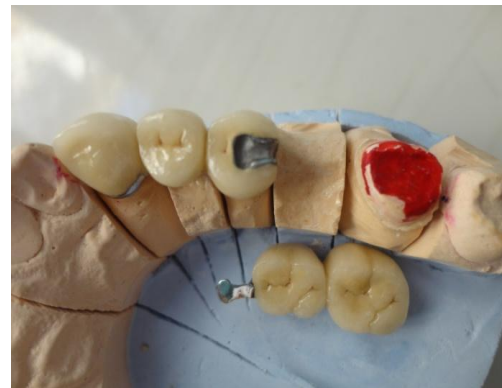


Figure: 5 Ceramic Layered

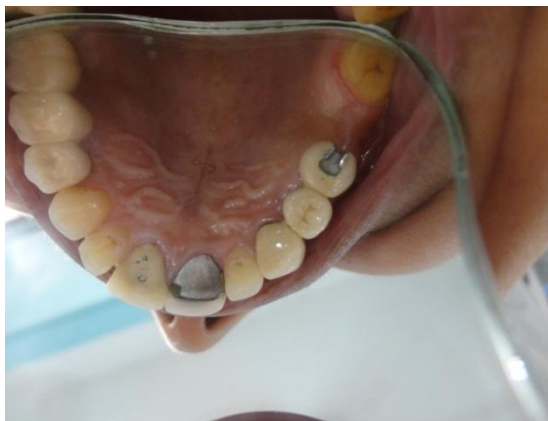

Figure : 6 Cementation of the mesial segment

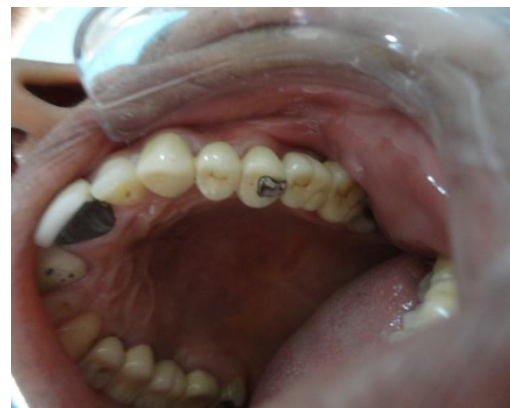

Figure : 7 Final Cementation



Figure: 8 Patient with cemented prosthesis

IV. Discussion

Non-rigid connector provides the opportunity to provide the break type of connection in fixed partial denture. There is a conflicting opinion on where to place the non-rigid connector. Markley⁶ suggested placement on one of the terminal abutments and not at the pier abutment. Adams⁷ suggested placing the connector at the distal side of pier, and if desired, adding one more at the distal side of the anterior retainer, while Gill⁸ suggested placing it at one side or both sides of the pier. Carl E.Misch⁹ recommended that in conventional fixed prostheses, the "male" portion of a nonrigid attachment usually is located on the mesial aspect of the posterior pontic, whereas the "female" portion is in the distal aspect of the natural pier abutment tooth. This prevents mesial drift from unseating the attachment. However, an implant does not undergo mesial drifting, and the nonrigid connector location is more flexible. For a natural pier abutment between two implants, a stress breaker is not indicated. In this case report, the nonrigid connector was placed on the distal side of the pier abutment which was beneficial. Since the long axis of the posterior teeth usually leans slightly in a mesial direction, vertically applied occlusal forces produce further movement in this direction. This would nullify the fulcrum effect and the patix/male of the attachment would be seated firmly in place when pressure is applied distally to the pier. Shillingberg¹⁰ suggested placing the connector at the distal aspect of pier abutment. This position was also supported by finite element analysis study done by Oruc et al⁴. The contraindications of using a nonrigid connector in a posterior 5-unit fixed partial denture with a pier are as follows:

1. Significant mobility of abutments.
2. If the span between the abutments is longer than one tooth.
3. If the distal retainer and pontic are opposed by a removable partial denture or an edentulous ridge, while the two anterior retainers are opposed by natural dentition, allowing the distal terminal abutment to supraerupt.

V. Conclusion

The paper describes a technique to neutralize the effect of forces that are transmitted to terminal abutments when a rigidly designed fixed partial denture with an intermediate pier abutment acts as a fulcrum resulting in damage to abutment teeth. The selection of right type of connector is an important step when sorting treatment plan.

References

- [1]. SP Dange , AN Khalikar , Shiv Kumar. Non-rigid Connectors in Fixed Dental Prosthesis - A Case Report , JIDANov 2008;2(11):356.
- [2]. Saurav Banerjee, Arlingstone Khongshei, Tapas Gupta, and Ardhendu Banerjee. Non-rigid connector: The wand to allay the stresses on abutment. Contemp Clin Dent. 2011 Oct-Dec;2(4): 351-354.
- [3]. Glossary of prosthodontic terms. 8
- [4]. Selcuk Oruc, Oguz Eraslan, H. AlperTukay and Arzu Atay. Stress analysis of effects of non rigid connectors on fixed partial dentures with pier abutments J Prosthet Dent 2008;99:185-192).
- [5]. P.V.Badwaik, A . J . P a k w a n . Non-rigid connectors in fixed prosthodontics: current concepts with a case report. J I P S , J u n e 2005;5(2):99-102.
- [6]. Markley MR. Broken-stress principle and design in fixed bridge prosthesis. J Prosthet Dent.1951;1:416-23.
- [7]. Adams JD .J Am Dent Assoc. Planning posterior bridges. 1956;53:647- 54.
- [8]. Gill JR. Treatment planning for mouth rehabilitation. J Prosthet Dent. 1952;2:230-45.
- [9]. Carl E.Misch Dental implant prosthetics. Elsevier Mosby. 2005; Pg:189-190.
- [10]. Shillingburg HT, Jr,Hobo S, Whitsett LD, Jacobi R, Brackett SE; Fundamentals of fixed prosthodontics. 3rd ed. Chicago:Quintessence 1997;Pg:85-118.