

## Needle Port Assisted Two-Port Laparoscopic Appendicectomy

Kiran Kumar KM<sup>1</sup>, Naveen Kumar M<sup>2</sup>, Srinivas Arava<sup>3</sup>,  
Kishore Krishna<sup>4</sup>, Pratheek KC<sup>5</sup>,

Dept. of Surgery, Sree Siddartha Medical College, Tumkur, Karnataka, India

1,3 Professor, 2 Assistant Professor, 4,5 Junior resident.

Address for Correspondence : Dr. Kiran Kumar KM, 109, "Khushi", 6<sup>th</sup> main road, Ashoka Nagara, Tumkur  
572102. Mob: 9886609009,

---

### Abstract:

**Introduction:** In conventional Laparoscopic Appendicectomy, three ports are used wherein both the sub-umbilical and supra-pubic port sites are hidden by the natural camouflages and the only visible scar is the third port in the iliac fossa. The third port scar can be made invisible by using a needle port for trans-parietal appendicular traction.

**Materials and Methods:** From January 2013 to May 2014 we attempted 35 cases of Needle port assisted Two port Laparoscopic Appendicectomy of which 7 were converted to conventional three port technique. After introducing 10 mm subumbilical telescopic port and a 5 mm suprapubic working port, an 18G needle fastned with prolene was made into a loop and introduced in right iliac fossa to retract the appendix as the third port, which scarless.

**Results:** Of the 35 included 7 were converted to conventional laparoscopy. Except for wound infection in 3 cases of appendicular abscess, post-operative complications were nil. Mean operative time was 55 minutes.

**Conclusion:** Needle port assisted two port laparoscopic appendicectomy has all the merits of conventional laparoscopy with additional advantage of invisible scars.

**Keywords:** Laparoscopic appendicectomy, two port laparoscopic appendicectomy,

---

### I. Introduction

Laparoscopic Appendicectomy (LA) has the advantages of less pain, fewer post-operative complications, shorter hospitalization, earlier return to work and better cosmesis<sup>1,2,3</sup> requiring three ports. These three ports can be avoided in Single Incision Laparoscopic Surgery (SILS) with special multiport umbilical trocar and specialized instruments, but has a steep learning curve due to loss of triangulation, clashing of instruments, lack of maneuverability, decreased technical expertise among the surgeons and an added financial burden to the patients. Thus, limiting its widespread use especially in rural/peripheral centers with limited resource.<sup>4,5</sup> Recent development is Natural Orifice Trans-luminal Endoscopic Surgery (NOTES) but, there are numerous difficulties including, complications of opening hollow viscera, failed sutures, lack of fully developed instrumentation and necessity of reliable cost-benefit analyses<sup>6,7</sup>. In conventional three-port LA (CLA) from a cosmetic viewpoint, the sub-umbilical and supra-pubic port sites are hidden by natural camouflages, but scar of the third port in the iliac fossa is the only visible external sign of surgery. In Needle-port assisted two-port LA (NLA) we avoid the third Laparoscopic port, instead an 18G hypodermic needle fastned with a poly-propylene (prolene) 1-0 suture material which we call as "Needle loop retractor" (NLR) is introduced in the right iliac fossa for retraction on the appendix<sup>8</sup>. This technique is virtually scar-less as the third port is needle port which does not produce a scar at all. This technique replicates the intra peritoneal view and operative technique of CLA, hence has a very short learning curve. Compared to SILS and NOTES, there is no need for expensive specialized equipment. NLA can be considered as the best procedure for selective cases of AA<sup>9</sup>.

### II. Materials And Methods

Patients with Appendicitis were confirmed sonologically and included. Patients with perforation-peritonitis and shock were excluded. A detailed proforma was recorded, and laboratory blood investigations done. Ethical clearance and Informed consent was obtained. Possibility of conversion to CLA or even open Appedicectomy if necessary was explained to patients.

#### Procedure

Patients were made to empty their bladders before lying on the operation table. Under General Anaesthesia, pneumoperitoneum of 12 mm Hg was created. With 10 mm sub-umbilical camera port a diagnostic laparoscopy was done and another 5 mm supra-pubic working port introduced. Table positioned with head low and tilt to left side. This facilitates evaluation and mobilisation appendix with a grasper. Appendix was held in

the grasper with traction towards the anterior abdominal wall. The tip of the grasper is felt by the surgeon externally, to know the point of best exposure of appendix in the right iliac fossa or even higher. An 18-gauge hypodermic needle traversed with a long prolene 1-0 suture material. This is needle loop retractor (NLR) (fig 1). NLR was punctured into the best suitable site (fig. 2) and it forms a loop in the abdomen to secure the appendix (fig 3). If exposure is inadequate the NLR is replaced into a new site. The needle is slid backwards and the exteriorised prolene is clamped with a artery forceps on the abdominal wall (fig. 2) and the appendix is held taut. This produces trans-parietal appendicular traction (TAT) for the surgeon. If exposure is inadequate the position of transparietal suture can be changed by a suitable new puncture site. With bipolar diathermy mesoappendix is cauterized and the cut (fig 4). Roeder knot with polyglycolic acid (Vicryl) 1-0 is made, introduced into the abdomen with Maryland forceps. Appendix released from the prolene loop, introduced into the Vicryl loop and again held taught by the poly-propylene loop. Appendicular base ligated with Vicryl using a knot pusher (fig 5). Similarly one more vicryl knot is applied to the appendix just distal to the first knot. Appendix is cut in between the knots and delivered out through umbilical port. The two laparoscopic port sites closed (fig 6). Those cases which were difficult with NLA were converted to CLA by introducing the third 5mm port in right iliac fossa - port rescue<sup>4</sup>. Total duration of the procedure was calculated from the time of incision upto the completion of skin closure. Pain in the post-operative period was rated using a Visual Analogue Scale (from 0 to 1). Procedure related complications during and after operations were recorded. Patients will be discharged from the hospital once they are fully mobilized and able to tolerate a normal diet.

### **III. Results**

From January 2013 to May 2014, 35 cases of AA between 6 to 45 years age were included, with 25 adults (13 men, 12 women) and 10 children (6 boys and 4 girls). Of the 35 cases, 28 underwent NLA and 7 required conversion to CLA (peri-appendicular adhesions in 4, long retrocolic appendix with narrow mesoappendix in 3). 5 of 28 patients had peri-appendicular abscess, which was drained by sucker in the suprapubic port, lavage done and the perforated friable appendix was removed by NLA. All the patients were discharged on third post-operative disease. Pain was experienced only at the umbilical site for 3-4 days. All were followed after one week. NLA had all the advantages of CLA. The needle puncture was not even identified by 21 patients of 28 cases and was totally scarless. The two port scars were invisible after 3 months as they were hidden by the natural camouflages and hence patients had better cosmetic satisfaction. 3 of the 5 cases appendicular abscess had umbilical port site infection. For the surgeons there was no difference in NLA technique except to get oriented for TAT using NLR which was accomplished in the initial 3 cases. The mean operative time was 55 minutes. There were extensive adhesions in 4 cases, which posed difficulty in releasing and visualisation of appendix with one working port. 3 cases had a long retrocolic appendix with a narrow mesoappendix tightly hugging the colon which we could not be released. Hence these 7 cases were converted to CLA.

### **IV. Discussion**

Surgical advancement in the management of AA has evolved dramatically in the last 120 years, from McBurney's simple large incision, to minimally invasive LA, to barely noticeable incisions after Single Incision Laparoscopic Surgery (SILS)<sup>11</sup>. LA significantly decreases the requirement of post-operative analgesia<sup>11</sup>. NLA has all the advantages of CLA with significantly reduced operative time and cost. The NLR provides a good TAT even with extensive inflammation, enables the surgeon for stable manipulation and gives better counter traction than conventional forceps<sup>12</sup>. Also with the intraoperative view the surgeon can decide the best site for placement of the needle-loop which ergonomically and cosmetically suitable<sup>12</sup>. The only drawback is that it is difficult if there are dense peri-appendicular adhesions or long, immobile retrocolic appendix. In such cases it can easily converted to CLA by an additional trocar in the right iliac fossa - "port rescue"<sup>4</sup>. NLA can be considered as best procedure for selective cases of AA<sup>9</sup> with significantly shorter operative time, lesser incidence of surgical sites infection, lesser post-operative pain and significantly lesser hospital stay<sup>2</sup>. It has an advantage over SILS and NOTES in being safe, easy, feasible, not requiring specialised instruments and also economical<sup>11</sup>. It is feasible in children also<sup>12</sup>. This technique can be considered as transition from CLA to SILS<sup>13</sup>. The long supra-umbilical incision used in SILS is more than that used for 10 mm trocar and scar is visible<sup>13</sup>. A meta-analysis comparing the "needlescopic appendicectomy" (Mini-laparoscopy - using 5mm telescopic port and 3mm working ports) with CLA concluded that there was no difference in post-operative hospitalisation, with higher conversion rate to open appendicectomy and longer operative time<sup>14</sup>. In CLA the appendix is held by the right hand and mesoappendix is cauterised by the left hand of the surgeon. The basic difference from CLA, is that counter traction is given by the exteriorised suture in right iliac fossa, as described in "puppet" technique<sup>15,16</sup>. The right hand is used for instrumentation in the suprapubic port. Penait L et al.,<sup>17</sup> differs from our technique in relation to trocar sizes appendicular fixation. In Ates O et al.,<sup>18</sup> technique fixation of both appendix and mesoappendix was done with a transparietal suture. Chow A et al<sup>19</sup> compared CLA with SILS

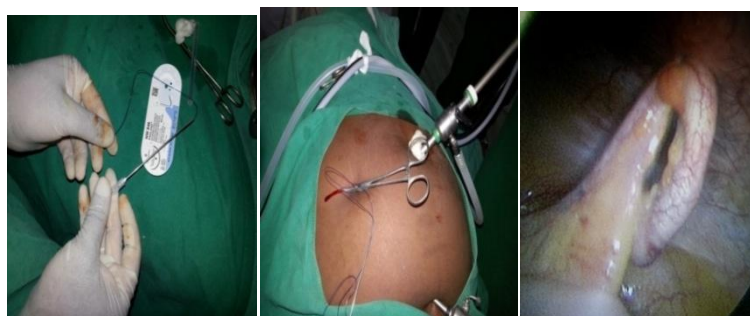
and noted that with increasing experience, SILS require just one additional port. Transparital appendicular fixation technique with 18G needle does not leave any scars as in other studies<sup>13,20</sup>. In supra-umbilical incision for SILS was larger than that used for single 10 mm trocar accommodation resulting in a more visible scar<sup>13</sup>. These studies are usually case reports and studies with more statistical power are needed for setting guidelines. NLA can be difficult in cases of unfavourable anatomical positions (retrocecal) or unfavourable abdominal cavity (extensive conatmination or adhesions). NLA can always be done in uncomplicated early AA with favaurable anatomical positions and in case of difficulty a third port can always be introduced to convert into CLA.

### V. Conclusion

Needle port assisted Laparoscopic appendicectomy has all the advantages of conventional laparoscopic appendicectomy with invisible scars. It is easy and cheap compared to SILS and NOTES. It can be routinely done in all cases of appendicitis, and can be easily converted to conventional technique in case of difficulty by inserting a third port.

### References

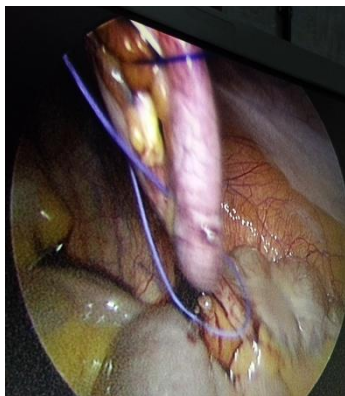- [1]. Eypasch E, Sauerland S, Lefering R, Neugenbauer EM. Laparoscopic versus open appendectomy: Between evidence and common sense. *Dig Surg* 2002;19:518-22.
- [2]. Yagnik VD, Rathod JB, Phatak AG. A retrospective study of two-port appendectomy and its comparison with open appendectomy and three-port appendectomy. *Saudi J Gastroenterol* 2010;16:268-71.
- [3]. Garbutt JM, Soper NJ, Shannon WD, Botero A, Littenberg B. Meta-analysis of randomized controlled trials comparing laparoscopic and open appendectomy. *SurgLaparoscEndosc* 1999;9:17-26
- [4]. Udwardia TE. Single-incision laparoscopic surgery: An overview. *J Minim Access Surg* 2011;7:1-2.
- [5]. Rao PP, Rao PP, Bhagwat S. Single-incision laparoscopic surgery - current status and controversies. *J Minim Access Surg* 2011;7:6-16.
- [6]. Chamberlain RS, Sakpal SV. A comprehensive review of single-incision laparoscopic surgery (SILS) and natural orifice transluminal endoscopic surgery (NOTES) technique for cholecystectomy *J GastrointestSurg* 2009;13:1733-40.
- [7]. Romanelli JR, Earle DB. Single-port laparoscopic surgery: An overview. *SurgEndosc* 2009;23:1419-27
- [8]. Rammohan A, Jothishankar P, Manimaran A B, Naidu R M. Two-port vs. three-port laparoscopic appendicectomy: A bridge to least invasive surgery. *J Min Access Surg* 2012;8:140-144.
- [9]. M Husain, S Sahu, P Sachan. Two-Port Laparoscopic Appendectomy. *The Internet Journal of Surgery*.2010 Volume 27 Number 2.
- [10]. Noah J. Switzer, Richdeep S. Gill, and ShahzeerKarmali, "The Evolution of the Appendectomy: From Open to Laparoscopic to Single Incision," *Scientifica*, vol. 2012, Article ID 895469, 5 pages, 2012. doi:10.6064/2012/895469.
- [11]. Rajab Ali, Muhammad R. Khan, TurabPishori, and Mohammad Tay, *Saudi J Gastroenterol*. 2010 Jan-Mar; 16(1): 25–2 doi: 10.4103/1319-3767.58764
- [12]. Ahmed Khairia,d, MagdiLolah b, Ahmed A. Khalaf,c,d, MostafaTolba, Pediatric Surgery Units, Departments of Surgery, a: Alexandria Faculty of Medicine, Alexandria and b: Monofya.Faculty of Medicine, Monofya, c: Department of Surgery, Ein-Shams Faculty of Medicine, Cairo, Egypt, d:Department of Surgery, Dallah hospital, Riyadh KSA. *Annals of Pediatric Surgery*.Vol. 6, No 3,4 July, October 2010, PP 140-143
- [13]. Jose Gustav Olijnyk, Guilherme Goncalves Pretto, Omero Pereira da Costa Filho, Fernando Koboldt Machado, Sidney Raimundo Silva Chalub, Leandro Totti Cavazzola, Two-port laparoscopic appendectomy as transition to laparoendoscopic single site surgery, *JMAS* 2014, vol : 10, issue :1, p23-26
- [14]. Sajid MS, Khan MA, Cheek E, Baig MK. Needlescopic versus laparoscopic appendectomy : A systematic review. *Can J Surg* 2009; 52: 129-34
- [15]. Chow A, Purkayastha S, Aziz O, Paraskeva P. Single incision laparoscopic cholecystectomy: An evolving technique. *Surg Endosc* 2010;24: 709-14
- [16]. Roberts KE, True single-port appendectomy: Firt experience with "Puppeteer technique". *Surg Endosc* 2009; 23: 1825-30
- [17]. Panait L, Beli RL, Duffy AJ, Roberts KE. Two-port laparoscopic appendectomy: minimising the minimally invasive approach. *J Surg Res* 2009; 153: 167-71
- [18]. Ate O, hakguder G, Olguner M, Akgur FM. Single-port laparoscopic appendectomy conducted intracorporeally with the aid of a transabdominal sling suture. *J Pediatr Surg* 2007;42:1071-4
- [19]. Chow A, Purkayastha S, Nehme J, Darzi LA, Paraskeva P. Single incision laparoscopic surgery for appndicectomy:A retrospective comparative analysis. *Surg Endosc* 2010;24:2567-74
- [20]. Akgur FM, Olguner M, Hakguder G. Ate O. Appendectomy conducted with single port incisionless-intracorporeal conventional equipment-endoscopic surgery. *J Pediatr Surg* 2010; 45: 1061-3.
- [21]. Source of support : nil, conflict of interest : nil



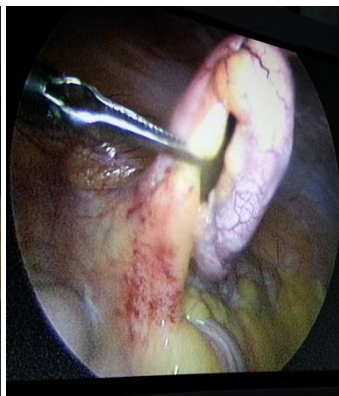
**Fig.1**

**fig.2**

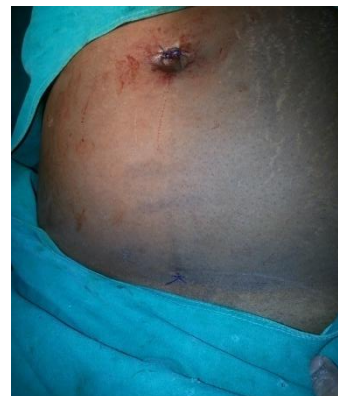**fig.3**



**Fig.4**



**fig.5**



**fig.6**