

## A Case Report of Dysgerminoma of the Ovary

Dr.V.IndiraKumari<sup>1</sup> MD, DGO Dr. R. Ramesh Babu <sup>2</sup>MD,RT

(Associate Professor, Dept. of obgyn) and

(Asst. Professor, YVC Oncology wing & Research centre, Chinnakakani Siddhartha Medical College, Vja, Dr.NTR UHS India)

**Abstract:** Correct terminology is Disgerminoma as the prefix 'Dis-', which means 'two', denotes that the tumour occurs in both sexes. The dysgerminoma of the ovary is identical with seminoma of the testes. Dysgerminoma is the commonest (30-40%) malignant germ cell tumour. It arises from undifferentiated form of germ cells. In five percent of cases, it is associated with dysgenetic gonad. 75% of the tumours occur before the age of 30 years. This patient is 28 years, admitted with a chief complaint of acute pain abdomen, fever and lump abdomen. On clinical examination, she was found to have a tender solid tumour of 22-24wks size, mobile more towards right side. Surface is irregular. No organomegaly and no evidence of ascites. Staging laparotomy done and left ovary is the seat of solid tumour falling to the right side of peritoneal cavity. Capsule is intact. No adhesions, no ascites. Other ovary cystic measuring 5x4 cms. And no evidence of growth in rest of abdomen. Left salpingo-oophorectomy done on 9<sup>th</sup> January, 2015. Biopsy is taken from the right ovary and from omentum.

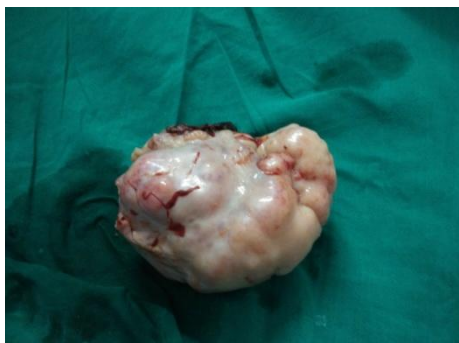**Keywords:** Dysgerminoma, germ cell tumours, Oophorectomy, Dysgenetic gonad.

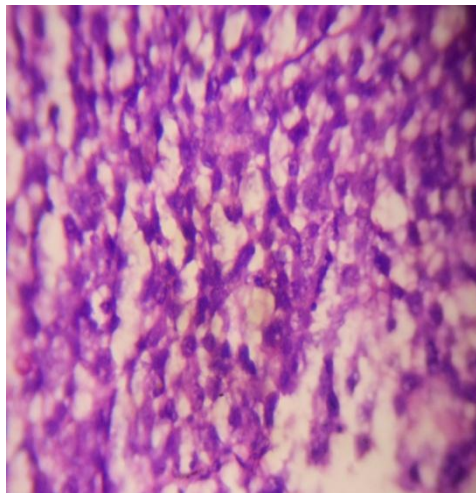
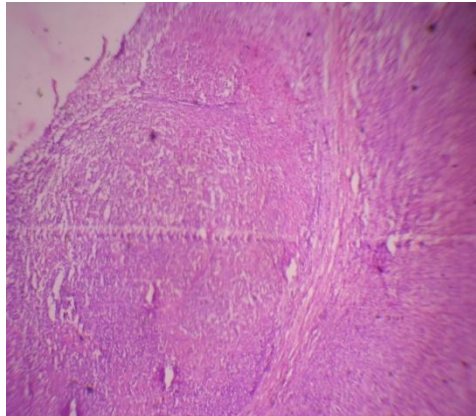
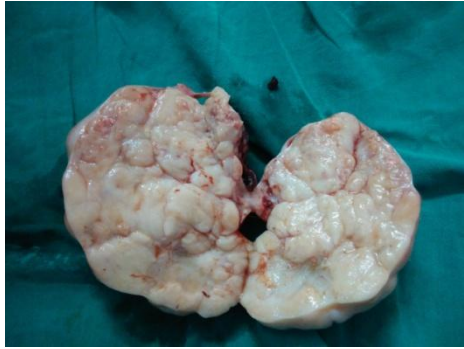### I. Introduction

Incidence is less than 1% of ovarian malignancies. It is the second most common tumour of germ cell tumours. Germ cell tumours constitute 15-20% of ovarian neoplasms. 3% of germ cell tumours are malignant. Germ cell tumours occur predominantly in children and young adults. Germ cell tumour accounts for 1% of all the malignant tumours in young females, bilateral in 10% of cases. The symptoms of dysgerminoma are abdominal pain, abdominal pain with lump, acute abdomen, menstrual abnormalities, ascites, fever and dyspnoea. Mean duration of symptoms as per the study conducted at AIIMS (1988-1999) is from 10 days to 36 months. Typically the dysgerminoma is without an endocrine activity. Some tumours are not pure dysgerminomas. Mixture with choriocarcinoma, yolk sac or embryonal carcinoma may worsen the prognosis. If contralateral ovary is cystic wedge biopsy need to be taken from it. If contralateral ovary is normal then biopsy need not be taken. Even though rare, dysgerminomas make up two thirds of all malignant ovarian neoplasms in women younger than 20 years.

### II. Case report

This case aged 28 years admitted with a complaint of acute pain abdomen, fever and abdominal lump. Past history: dyspareunia present since 2 months. Menstrual history regular, 3-5/30 days. She is para 1 and live 1 with history of caesarean section done for premature rupture of membranes. Patient conceived after investigations for infertility. At the time of LSCS, ovarian cyst was found and it was surgically removed. But the specimen was not sent for histopathological examination by that consultant doctor. Last child birth of 3 years. CA125, AfP, HCG and LDH levels are within normal limits. By X-ray chest P/A view and the USG of total abdomen and intraoperatively, no evidence of metastasis. Biopsy taken from the contralateral cystic ovary and from the omentum. As the patient is young and having only one child of 3 years and per-operatively no evidence of malignancy, left salpingo oophorectomy done and the specimen sent for histopathological examination. The surface in cut section shows yellowish grey colour. The HPE report is dysgerminoma.





### III. Discussion

This case presented as dyspareunia of 2 months duration followed by fever and pain lower abdomen of sudden onset. History of conception after investigations for infertility. At the time of doing caesarean section, ovarian cyst was found and was surgically removed (?para ovarian/fimbrial cyst). In view of young patient with neither clinical nor USG or per-operative evidence of malignancy, only left salpingo-oophorectomy done. As the specimen report came as dysgerminoma, the case referred to cancer unit where she was kept on Bleomycin, Etoposide and Cisplatin.

**Chemotherapy regime:** For stage 1a- Adjuvant chemotherapy is not recommended, recurrence rate of stage 1a is 10-15%.

4 cycles BEP Regimen every 3 weeks.

- Bleomycin – 30 units IV on Day 1, 8 and 15.
- Etoposide – 100mg/m<sup>2</sup> IV Day 1-5.
- Cisplatin – 20mg/m<sup>2</sup> IV on Day 1-5.

**Follow up:** It consists of physical examination, tumour markers (LDH,  $\beta$  HCG) every 1-2 months for one year, every 2 months in the 2<sup>nd</sup> year, every 3 months in the 3<sup>rd</sup> year, every four months in the 4<sup>th</sup> year, every 6 months in the 5<sup>th</sup> year and annually thereafter.

#### **IV. Conclusion**

75-80% of dysgerminoma has presented at stage 1a, can be treated by conservative surgery alone. Even though the dysgerminomas are radio sensitive, radiotherapy abandoned due to high success rates with platinum based chemotherapy as well as avoiding long term complications from radiation including sterility and early menopause. Prognosis of patients with GCT of ovary has improved significantly as a result of cisplatin based chemotherapy after conservative surgery. The menstrual function and reproductive function of the patient are preserved. These patients need life long follow up because of recurrence of the tumour.

#### **References**

- [1]. Principles of Gynaecology Sir. Norman Jeffcoate
- [2]. Shaw's text book of Gynaecology
- [3]. DC Datta's book of Gynaecology
- [4]. Sudhasalhan book of Gynaecology
- [5]. Gynecological oncology practise guide lines
- [6]. WWW.PATHOLOGYOUTLINES .COM
- [7]. Dysgerminoma- Shahzadehdaivand MD  
e medicine.medscape.com
- [8]. Chad M Michemen
- [9]. 8)WWW.ncbi.nlm.nih.gov/putmed/3299187
- [10]. Thomas GM DamtoAJ.Hcker NF, De petrilloAD
- [11]. AGOICON-2008 compelled by Dr R Raghu Raman
- [12].