

## Rigid Ureteroscopy for the Treatment of Ureteric Calculi: Initial Experience

Dr. Sudershan Kapoor<sup>1</sup>, Dr. Ketan Gujral<sup>2</sup>,

<sup>1</sup>, Associate Professor, Surgery Deptt, GNDH/GMC Amritsar

<sup>2</sup>, Junior Resident

---

**Abstract:** Ureteroscopy is a standard urologic technique that provides direct visualization of the upper urinary tract, facilitating both diagnostic and therapeutic interventions. Ureteroscopy is most commonly used for the treatment of ureterolithiasis and nephrolithiasis. Other common indications include evaluation of lateralizing hematuria, abnormal urinary cytology, and abnormal upper tract imaging studies. Surveillance and treatment of upper tract urothelial carcinoma may be performed using ureteroscopic techniques. Ureteroscopy may also be utilized in cases of ureteral stricture and ureteropelvic junction obstruction. This study was conducted in the Department of General Surgery of Guru Nanak Dev Hospital attached to the Government Medical College Amritsar. Total of 25 patients with diagnosis of ureteric calculi admitted were taken up for study, excluding patients below 14 years of age, patients unfit for surgery. Rigid ureteroscopy was performed in all cases for stone retrieval, and the complications encountered intra and post-operatively were noted and managed accordingly. Overall, the procedure ureteroscopy was highly satisfactory in the management of ureteric calculi. The ureteroscope used correctly, is a valuable part of the endoscopic armamentarium.

---

### I. Introduction

Renal and ureteric calculi are formed when the urine is supersaturated with salt and minerals such as calcium oxalate, struvite (ammonium magnesium phosphate), uric acid and cystine.<sup>1</sup> 60-80% of stones contain calcium. They vary considerably in size from small 'gravel-like' stones, to large staghorn calculi. The calculi may stay in the position in which they are formed, or migrate down the urinary tract, producing symptoms along the way. Renal and ureteric stones are common, being present at some time in one in ten of the population, although a significant proportion will remain asymptomatic. Men are more commonly affected than women, with a male to female ratio of 3: 1. The classical feature of renal colic (or ureteric colic) is sudden severe pain. It is usually caused by stones in the kidney, renal pelvis or ureter, causing dilatation, stretching and spasm of the ureter. The pain radiates down to the testis, scrotum, labia or anterior thigh. Basic analysis should include stick testing of urine for red cells (suggestive of urolithiasis), white cells and nitrites (both suggestive of infection) and pH (pH above 7 suggests urea-splitting organisms such as *Proteus* spp. whilst a pH below 5 suggests uric acid stones). Mid-stream specimen of urine for microscopy (pyuria suggests infection), culture and sensitivities. Blood for FBS, CRP, renal function, electrolytes, calcium, phosphate and urate, creatinine. Prothrombin time and international normalized ratio if intervention is planned. Non-enhanced CT scanning is now the imaging modality of choice and has replaced Intravenous pyelogram (IVP). Ultrasound scanning may be helpful to differentiate radio-opaque from radiolucent stones and in detecting evidence of obstruction. Plain X-rays of the kidney, ureter and bladder (KUB) are useful in watching the passage of radio-opaque stones (around 75% of stones are of calcium and so will be radio-opaque). Initial management of acute presentation: Non-steroidal anti-inflammatory drugs (NSAIDs), usually in the form of diclofenac IM or PR, should be offered first-line for the relief of the severe pain of renal or ureteric colic. Calcium-channel blockers (eg nifedipine) or alpha-blockers (eg tamsulosin) are given. A corticosteroid such as prednisolone is occasionally added when an alpha-blocker is used but should not be given as monotherapy.<sup>2</sup> Procedures to remove stones include extracorporeal shock wave lithotripsy (eswl). Percutaneous nephrolithotomy (pcnl) - used for large stones (>2 cm), staghorn calculi and also cystine stones. Stones are removed at the time of the procedure using a nephroscope, ureteroscopy - this involves the use of laser to break up the stone and has an excellent success rate in experienced hands, open surgery - rarely necessary and usually reserved for complicated cases or for those in whom all of the above have failed, eg multiple stones.

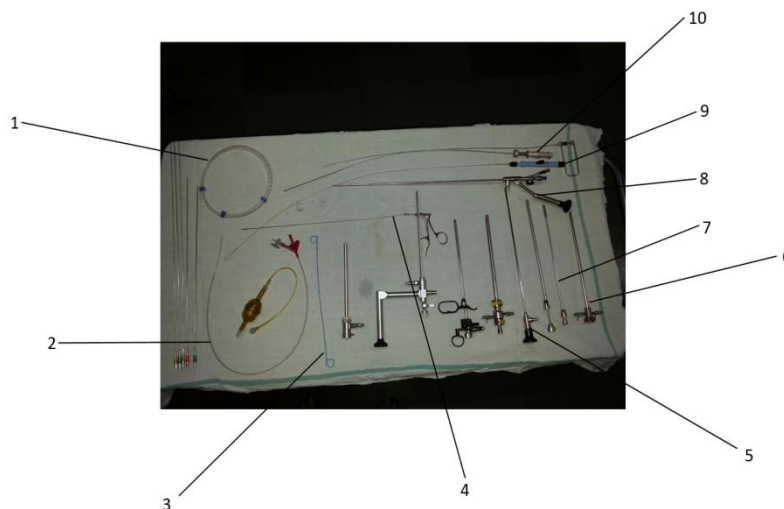
### II. Aims And Objectives

To evaluate the learning curve of rigid ureteroscopy within our institution and to find out the results and complications of rigid ureteroscopy for the treatment of ureteric calculi as initial experience.

### III. Materials & Methods

The patients were enrolled after taking informed consent on basis of following inclusion and exclusion criteria after approval from ethical committee. Inclusion criteria: 25 adult patients of ureteric stone, admitted in surgical ward, GNDH, Amritsar. Exclusion criteria: Patient below 14 years of age, patient unfit for surgery. Subjects were followed up for a month after discharge. The instruments used were rigid ureteroscopy set 8/9.8 Fr, 12degree, double working channel., cystoscope 19.5 Fr., Telescope 30 degree., Pneumatic lithotripsy set., standard laproscopic unit.

Outfit of procedure: Firstly the cystoscopy was done. Then the ureteric orifice was visualized. Once the orifice was found then the Guide wire was inserted. Further the ureteric balloon dilator was inserted over the guide wire to dilate ureteric orifice. Further ureteroscopy was done and stone was visualized. The stone was then fragmented with pneumatic lithotripter. The fragments were retrieved in UB with dormia basket or forceps. Furthermore DJ stenting was done and UB was washed with plenty of normal saline to remove the debris. Lastly Foley's catheter was inserted.



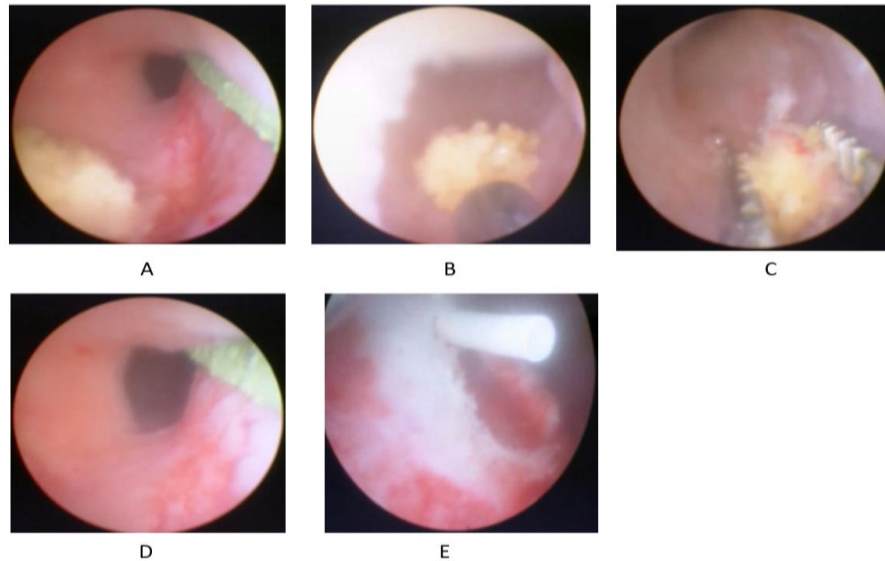
#### Instruments Used In Ureteroscopy

1. Guide wire
2. Balloon dilator
3. DJ stent
4. Stone holding forceps
5. Telescope
6. Cystoscope
7. Cystoscopic obturator
8. Ureteroscope
9. Dormia basket
10. 3-Prong grasping forceps

### IV. Observations

The study showed that in the age group <20 years (14-20) there were 2 cases (8%), between 21-40 years there were 15 cases (60%), between 41-60 years there were 7 cases (28%), and aged more than 60 years there was 1 case (4%). Of the total cases studied 18 cases were male (72%) and 7 were female (28%). The study showed the sex ratio of M:F of 2.6: 1. The study showed the location of ureteric calculi in pelvic ureter is seen in 19 cases (76%), iliac ureter is seen in 4 cases (16%), and lumbar ureter is seen in 2 cases (8%). The study showed the incidence of calculi in right ureter seen in 10 cases (40%), left ureter in 15 cases (60%). The study showed that stone size was between 0.6cm- 0.8cm in 4 cases (16%), between 0.9cm- 1.2cm in 17 cases (68%), and >1.2cm in 4 cases (16%). Intraoperative complications were encountered in 2 cases (8%). In both cases bleeding was the complication seen, and one of those cases was converted to open ureterolithotomy. The other case underwent successful ureteroscopy with DJ stenting. Failure of stone removal was accounted in 4 cases of total cases (16%). Distal ureteric stricture found in 1 case (25%), large impacted stone in 2 cases (50%), and stone was non-visualized in 1 case (25%). Out of 25 cases, 3 cases were converted to open surgery and remaining 22 underwent successful ureteroscopy. Total of 4 of those 22 cases (18.2%) presented with post-operative complications which were managed conservatively with no long term consequences. The study showed the incidence of mild hematuria in 2 cases (50%), fever in 1 case (25%), and colic in 1 case (25%) of all

cases with post-operative complications. None of the cases studied were complicated with perforation or obstruction. Complete stone removal was done in 21 cases (84%), and stone not removed in 4 cases (16%). 100% of stones in upper ureter were not removed. 100% of stones in middle ureter were removed. 90% of stones in lower ureter were removed (17/19 cases), whereas 10% were not removed (2/19 cases). The study showed the incidence of hydronephrosis in 20 cases (80%), hydroureter in 18 case (72%), perinephric changes in 15 cases (60%).



#### **Ureteroscopic Images Captured While Performing Urs**

- A. Stone in the ureter with a guide wire in place at 3'o clock position.
- B. Lithotripter in action.
- C. Stone holding forceps holding the fragmented stones.
- D. Clear ureteric lumen after stone extraction.
- E. DJ stent insertion.

#### **V. Discussion**

The first ureteroscopy was reported by Young and McKay in 1929 after passing an adult sized cystoscope to the renal pelvis in a child with megaureters and posterior urethral valves.<sup>3</sup> It was not until 1961 that a subsequent ureteroscopy was cited by Marshall using a 9F flexible fiberoptic instrument.<sup>4</sup>This study was done to evaluate the learning curve of ureteroscopy within our institution, and to weigh the advantages and limitations of this technique. The study done in our institution showed that in the age group <20 years (14-20) there were 2 cases, between 21-40 years there were 15 cases, between 41-60 years there were 7 cases, and aged more than 60 years there was 1 case. The mean age of the patient in our study was 38.44 years. The sex distribution as per our studies showed a greater incidence in male patients.18 cases studied were male, and 7 were female, with a sex ratio of M: F of 2.6: 1. Our study showed that stone size was between 0.6cm- 0.8cm in 4 cases, between 0.9cm- 1.2cm in 17 cases, and >1.2cm in 4 cases. A study done by CătălinPricop, Carmen Dorobăt, and Martha Orsolya on retrograde ureteroscopy in 473 patients, showed a higher proportion of women patients (male to female ratio: 1/1.72), and patient age ranged from 17 to 82 years with a mean age of 46.35±15.76. The study group included 473 patients, in 209 cases the stone size was between 0.6 and 0.8 cm, in 196 cases between 0.9 and 1.2 cm, and in 68 cases above 1.2 cm.<sup>5</sup>The study done in our institution showed the location of ureteric calculi, in pelvic ureter in 19 cases, in iliac ureter in 4 cases, and in lumbar ureter in 2 cases. Whereas it showed the incidence of calculi in right ureter in 10 cases, in left ureter in 15 cases. A study done at urology and nephrology centre, University of Mansoura, Mansoura, Egypt showed the location of stone in pelvic region in 98 cases, in iliac region in 15 cases, in lumbar region in 11 cases. Incidence of calculi in right ureter was seen in 50 cases and incidence in left ureter was seen in 74 cases.<sup>6</sup>Our study showed the incidence of hydronephrosis in 20 cases, hydroureter in 18 case, perinephric changes in 15 cases. A study done by Katz DS, Lane MJ and Sommer FG reviewed 54 cases with ureteric stones and observed that hydronephrosis was found in 37 patients, hydroureter in 36 patients, and perinephric soft-tissue changes in 35 patients. Only two of the 54 patients had no evidence of hydronephrosis, hydroureter, or perinephric soft-tissue changes.<sup>7</sup>In our study, intraoperative complications were encountered in 2 cases. In both cases bleeding was the complication seen, and

one of those cases was converted to open ureterolithotomy. The other case underwent successful ureteroscopy with DJ stenting. None of the cases were complicated by lesions of ureteral mucosa, perforation of ureter, avulsion of ureter, or by extra-ureteral migration of stone. A study was done by Georgescu D, Muțescu R, Geavlete B, Geavlete P and Chirurgiain which 8150 semirigidureteroscopic procedures for ureteral lithiasis were performed in 7456 patients. Intraoperative incidents occurred in 348 cases. The overall rate of intraoperative complications was 2.8%. These were represented by lesions of the ureteral mucosa, perforation, bleeding, ureteral avulsion and extra-ureteral stone migration.<sup>8</sup>In our study, failure of stone removal was accounted in 4 cases of total cases. Distal ureteric stricture found in 1 case, large impacted stone in 2 cases, and stone was non-visualized in 1 case. A study done in Urology and Nephrology centre, University of Mansoura, Mansoura, Egypt, on 120 patients, technical failure was encountered in 13 cases. Out of which, 2 cases each were due to distal ureteric stricture, large impacted stones, proximal migration of calculi, fragmented gravel, and non-visualized stone. 3 cases were unsuccessful due to ureteric perforation.<sup>6</sup>In our study, complete stone removal was done in 21 cases, and stone not removed in 4 cases. 100% of stones in upper ureter were not removed. 100% of stones in middle ureter were removed. 90% of stones in lower ureter were removed (17/19 cases), whereas 10% were not removed (2/19 cases). Our study showed an acceptable removable rate (90%) when location was below iliac vessels. A study done in Department of urology, Rigshospitalet and Glostrup Hospital, University of Copenhagen, Copenhagen, Denmark, showed that out of a total of 55 cases, 40 cases had successful stone removal, whereas in 15 cases the stone could not be removed. 7 out of 8 cases of stones in upper ureter could not be removed, 1 case was successful. In the middle ureter, in 3 cases the stones were not removed, and in 7 cases the stone was removed. In the lower ureter 5 cases were unsuccessful, while in 32 cases the stones were removed. A random selection of 15 cases from our study revealed an average operating time of 55 minutes.<sup>9</sup>In our study since distal ureteric stricture was found in 1 case, large impacted stone in 2 cases, and stone was non-visualized in 1 case so out of 25 cases, 3 cases were converted to open surgery and remaining 22 underwent successful ureteroscopy. Out of these 22 cases, 7 cases presented with post-operative complications which were managed conservatively with no long term consequences. The incidence of mild hematuria was noted in 2 cases, fever in 3 cases, and colic in 2 cases. None of the cases studied were complicated with obstruction. A study done in Urology and Nephrology centre, University of Mansoura, Mansoura, Egypt, on 120 patients, post-op complications were seen in 21 patients. Mild hematuria and colic were seen in 3 cases each, obstruction was noted in 2 cases, fever was seen in 5 cases, and perforation was noted in 8 cases. 3 out of these 8 cases required open surgery, and in the other 5 ureter was stented after successfully removing the calculi. The other complications were treated conservatively.<sup>6</sup>Our experience indicates that with familiarity the ureteroscope should become a useful tool in the armamentarium of every urologist.

## **VI. Summary And Conclusion**

Rigid ureteroscopy was performed in all cases for stone retrieval and was successful in 21 cases. Majority of patients were in the age group of 21-40 years, and males predominate females (male: female is 2.6: 1). Imaging studies are the most helpful in diagnosing the patient and to note stone size and location and to plan the procedure accordingly. Maximum number of stones were located in the lower ureter, seen in 19 cases. The average stone size was between 0.9-1.2 cms seen in 17 cases. The ureteroscopy procedure was uneventful with no intra-operative complications encountered in 23 cases. Post-operative complications were noted in 4 cases, which were managed conservatively without any delayed consequences. Complete stone removal by ureteroscopy was done in 21 cases, 90% of stones in lower ureter were removed (17/19 cases). IVP is a sensitive and commonly used diagnostic aid in stone detection and renal function. Overall, the procedure ureteroscopy was highly satisfactory in the management of ureteric calculi. The ureteroscope used correctly, is a valuable part of the endoscopic armamentarium.

## **References**

- [1]. Worcester EM, Coe FL. Clinical practice. Calcium kidney stones. *N Engl J Med.* 2010; 363(10): 954-63.
- [2]. Seitz C, Liatsikos E, Porpiglia F, et al; Medical therapy to facilitate the passage of stones: what is the evidence? *EurUrol*, 2009; 56(3) : 455-71.
- [3]. Young HH, McKay RW. Congenital valvular obstruction of the prostatic urethra. *SurgGynec&Obst* 1929; 48: 509.
- [4]. Marshall VF. Fiber optics in urology. *J Urol*, 1964; 91: 110.
- [5]. Pricop C, Dorobãt C, Orsolya M. Antibiotic prophylaxis in retrograde ureteroscopy: what strategy should we adopt?. *Germs*, 2013; 3(4): 115-21.
- [6]. El-Kappany H, Gaballah MA, Ghoneim MA. Rigid Ureteroscopy for the treatment of ureteric calculi: Experience in 120 cases. *Brit J of Urol*, 1986; 58: 499-503.
- [7]. Katz DS, Lane MJ, Sommer FG. Unenhanced helical CT of ureteral stones: incidence of associated urinary tract findings. *Am J Roentgenol*, 1996; 166(6): 1319-22.
- [8]. Georgescu D, Muțescu R, Geavlete B, Chirurgia GP. Intraoperative complications after 8150 semirigidureteroscopies for ureteral lithiasis: risk analysis and management. *Bucharest Romania*, 1990; 109(3): 369-74.
- [9]. Schultz A, Kristensen JK, Bilde T, Eldrup J. Ureteroscopy: results and complications. *Journal of Urology* , 1987; 137(5): 865-6.