

## **“A Comparative Study Of Diagnostic Efficacy Of Fine Needle Aspiration Cytology Of Cervical And Axillary Lymphadenopathy As Compared To Open Biopsy For Histopathological Examination In Karpaga Vinayaga Medical College And Hospital, Madhuranthagam.”**

<sup>1</sup>Prof Dr. M. Bhaskar , <sup>2</sup>Dr. Dhinesh Babu. K

<sup>1</sup>Professor, Department of General Surgery ,karpaga vinayaga medical college and hospital, madhuranthagam.

<sup>2</sup>Assistant Professor, Department of General Surgery, karpaga vinayaga medical college and hospital, madhuranthagam.

---

**Abstract:** Lymphadenopathy is a very common clinical manifestation of many diseases, defined as an abnormality in the size or character of lymph nodes, caused by the invasion or propagation of either inflammatory cells or neoplastic cells into the node.

**Objective:** To evaluate the diagnostic efficacy of the fine needle aspiration cytology of cervical and axillary lymphadenopathy as compared to open biopsy for histopathological examination. A comparative study of diagnostic efficacy of FNAC cervical and axillary lymphadenopathy as compared to open biopsy for histopathological examination was carried out on the patients with cervical and axillary lymph adenopathy coming to OPD. All patients selected as per inclusion and exclusion criteria underwent FNAC of lymph node followed by open biopsy of same lymph node. The results revealed that, the overall diagnostic accuracy was 82.00% with accuracy of 91.70% for tuberculous lymphadenitis and 80.00% for metastatic carcinoma with positive predictive value of 100.00%. In 50.00% of the patients, enlarged tuberculous lymph nodes were matted. Cervical group of lymph nodes were the most commonly affected group of lymph nodes (79.00%). In the present study diagnostic accuracy for metastatic carcinoma was 80.00% and for squamous cell carcinoma was 100.00%. It must be stressed that when the fine needle aspirate appears purulent or when tuberculosis is clinically suspected, specimen should be stained for acid fast bacilli. It improves diagnostic capability of FNAC. If FNAC is positive surgeon can proceed to treat the neck without excisional biopsy of the enlarged lymph nodes. Supraclavicular lymphadenopathy rarely represents curable disease and these nodes can be excised for histological confirmation. FNAC should be followed by open biopsy if negative. The use of flow cytometry, tumour markers, immunocytochemistry of FNA specimen have excellent potential for cytological based diagnosis.

---

### **I. Introduction**

Lymphadenopathy is a very common clinical manifestation of many diseases. It is defined as an abnormality in the size or character of lymph nodes, caused by the invasion or propagation of either inflammatory cells or neoplastic cells into the node. It results from vast array of disease process whose broad categories are “MIAMI”. This represents malignancies, infections, autoimmune disorders, miscellaneous and iatrogenic causes. Among the serious illness that can present with lymphadenopathy most concerning to the patient and physician is the possibility of an underlying malignancy. Though the presentation of lymphadenopathy is common its diagnosis is sometimes difficult, requires battery of test. Awareness of lymphatic anatomy, drainage patterns, regional differential diagnosis, a thorough history including key factors such as age, location, duration, patient exposure is essential.

Open biopsy followed by histopathological examination is the final answer for the diagnosis of the lymphadenopathy. But this procedure has got its limitations like, poor patient compliance, consumption of time, co-operation of anesthetist, surgeon, proper operating facilities and risk of anaesthesia and surgery.

A physician reluctance to perform excisional biopsy is based on the fact that the procedure may increase the risk of inducing tumour spread. The morbidity of the procedure and the hindrance of subsequent therapy because of scarring or vascular impairment are also the reasons for caution. However this above mentioned fact is debatable.

Considering all the pitfalls of open biopsy FNAC is rapid inexpensive and safe procedure that can be done at the time of the patients first presentation and immediately after regional physical examination. The technique is simple, rapid, relatively pain free and safe. The Differential diagnosis lies usually between reactive hyperplasia, malignant lymphoma and metastatic disease. FNAC is ideally suited for the investigations of these

swellings and aspirated material may be used in ancillary investigations such as immunocytochemistry to support the diagnosis of cytology on FNAC. This allows a definitive diagnosis to be made sparing more expensive radiological investigations and surgical intervention.

FNAC can not only confirm the presence of metastatic disease but also gives the clues regarding the nature and origin of primary tumour. In patients with enlarged lymph nodes and previous documented malignancy FNAC can obviate the further surgery performed merely to confirm the presence of metastasis. Also it helps in diagnosis of diffused cervical lymphadenopathy in HIV where open biopsy might prove costly resulting in increased morbidity. However the most difficult areas in diagnosing lymph node disease by FNAC are concerning differentiation of low grade lymphoma from reactive hyperplasia and subtyping of lymphoma.

For FNAC of lymph nodes to become diagnostically successful in lymphoproliferative disorders, the many myths concerning the difficulty of diagnosing the lymph node disease by FNAC must be abandoned. FNA specimens, but they have excellent potential for cytological based diagnosis.

Hence the present study is undertaken to discuss the diagnostic efficacy of FNAC, its limitations and place in clinical practice.

### **Objectives**

The objective of the present study is to evaluate the diagnostic efficacy of the fine needle aspiration cytology of cervical and axillary lymphadenopathy as compared to open biopsy for histopathological examination.

## **II. Methodology**

A comparative study of diagnostic efficacy of fine needle aspiration cytology of cervical and axillary lymphadenopathy as compared to open biopsy for histo-pathological examination was carried out in karpaga vinayaga medical college and hospital, madhuranthagam

### **Source of Data**

Patients with cervical and axillary lymph adenopathy coming to out patient department of karpaga vinayaga medical college and hospital, madhuranthagam

### **Sample Size**

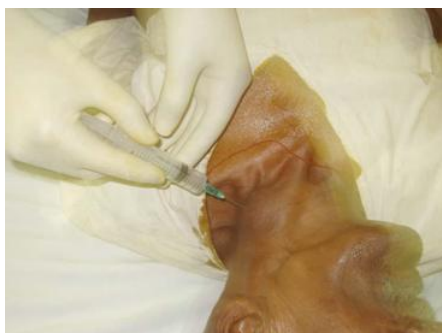
50 Patients

### **Inclusion Criteria**

- a. Age 3 to 80 years
- b. All axillary and cervical lymphadenopathy (firm to hard in consistency)
- c. Enlarged non-tender lymph nodes more than 1.5 cm in diameter

### **Exclusion Criteria**

- a. Enlarged lymph nodes less than 1.5 cm in diameter
- b. All other neck swellings other than cervical lymphadenopathy
- c. Acute lymphadenitis i.e. tender, soft in consistency with signs of inflammation

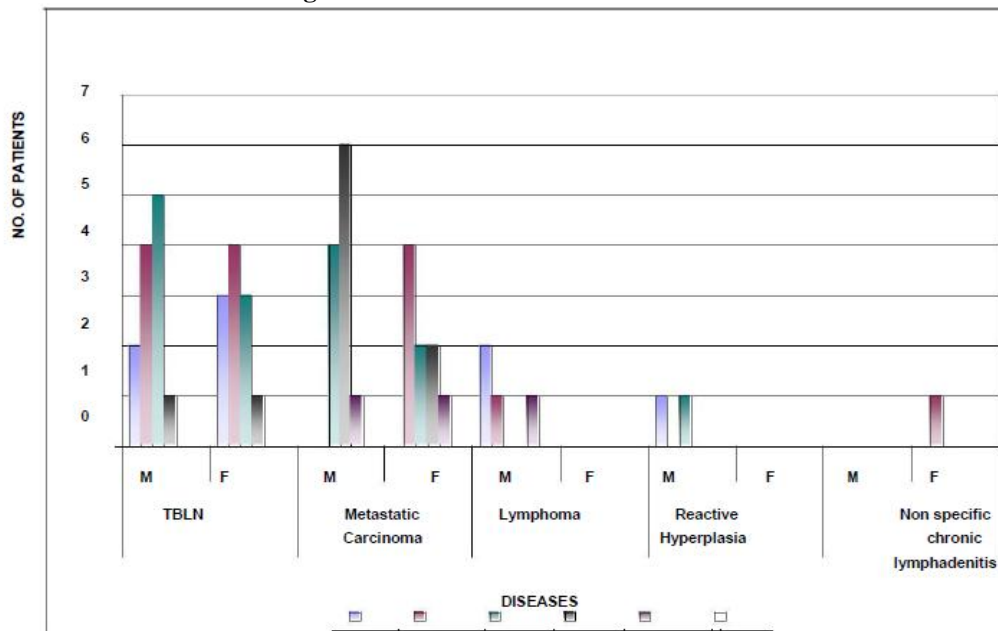


## **III. Results**

A total of 50 patients having cervical and axillary lymphadenopathy underwent fine needle aspiration cytology followed by open biopsy of same enlarged diseased lymph node for histopathological confirmation in karpaga vinayaga medical college and hospital, madhuranthagam

All patients were selected in the study as per inclusion and exclusion criteria.

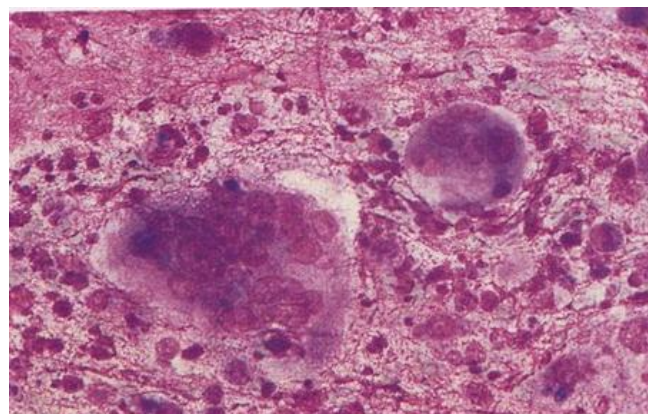
**Age And Sex Distribution Of Patients**



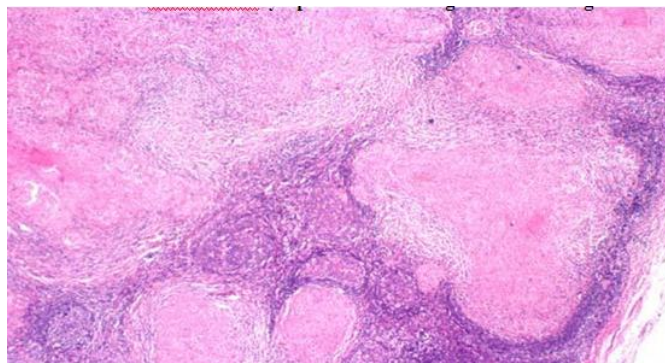
50 patients with a definite diagnosis made on FNAC were analyzed for age and sex distribution. Tuberculosis lymphadenitis was seen more commonly in third and fourth decade 34.83% each. Its incidence declined with the advancing age. Metastatic carcinoma was more in patients over the age of 35 years. Lymphoma was distributed in all age groups without predilection, however, the number of cases are too small in the present study to actually comment on its incidence. Incidence of reactive hyperplasia could not be commented upon as there are only 2 patients with definite diagnosis of reactive hyperplasia. Males showed preponderance of lymphoma (as 4 cases are male), metastatic carcinoma (head and neck origin) to lymph nodes, whereas tuberculosis showed almost equal preponderance.

**Table No. 8 Overall diagnostic efficacy of FNAC (n=50)**

Test	HPR (+)	HPR (-)	Total
FNAC +	41	00	41
FNAC -	09	00	09
Total	50	00	50



**Picture No. 1: FNAC of Tuberculous lymph node – showing multinucleate giant cells**



**Picture No. 2: Histopathology of Tuberculosis of cervical lymph node showing caseation.**

#### **IV. Discussion**

FNAC entails using a narrow gauge (22-23G) needle to collect the sample of a lesion for microscopic examination. It allows a minimally invasive, rapid diagnosis of tissue but it does not preserve the histological architecture which limits its ability to make a definitive diagnosis.

However, rapid diagnosis by FNAC can shorten or avoid hospital admission, speed a patient's route to an appropriate specialist.

This study was undertaken to evaluate the role of FNAC in clinically significant cervical and axillary lymphadenopathy. Symptoms and signs although indicative of the etiology of lymphadenopathy cannot be substituted for a morphological diagnosis. Until recently, excision of diseased enlarged lymph node for histopathological examination was the final answer for the diagnosis. With the advent of FNAC in recent years, it has provided the clinician with an additional, safe, reliable, quick and inexpensive method for the diagnosis of lymphadenopathy.

In developing countries like India where tuberculosis is the major problem and facilities for the biopsy are not readily available at the primary health care level, FNAC can be very useful in providing a diagnosis. It also reduces pressure on financial resources necessary for surgical procedures like open biopsy for diagnosis confirmation. In our study we attempted to evaluate the diagnostic efficacy and its limitation in the clinical practice. All our patients as per inclusion criteria were subjected to FNAC followed by open biopsy of the same diseased enlarged lymph node. In our study of 50 patients of cervical and axillary lymphadenopathy (23 out of 50) patients had tuberculous lymphadenopathy which was the most common diagnosis in our study (46.00%) with an accuracy of 91.70% on FNAC with histopathological correlation. The sensitivity of FNAC for diagnosing tuberculous lymphadenopathy is 91.70% in the present study, which is comparable to similar studies.

The study done by Gupta K.A. (1990) has also reported accuracy of 76.78% for tuberculous lymphadenopathy to an histological correlation.<sup>39</sup>

A similar study done by Bhargava P (2001) has reported accuracy of 98.50% for tuberculous lymphadenopathy to histological correlation.<sup>45</sup>

The study done by Sarda A. K. (1990) reported accuracy of 96.00% for tuberculous lymphadenopathy.<sup>38</sup> In the present study accuracy for tuberculous lymphadenopathy is 91.70% which is comparable with most of the studies. In the present study tuberculous lymphadenitis has a peak incidence in age group of 19 – 50 years with almost same male to female ratio with decline in incidence of increasing age.

In 50.00% of patients, enlarged tuberculous lymph nodes were matted. Mantoux reaction of 10 mm or more was observed in 40.00% of patients. The characteristic feature of tuberculous lymphadenitis on cytology examination are the presence of epitheloid cell clusters, caseation necrosis and typical Langhan's giant cells. In doubtful cases Ziehl–Neelsen staining is helpful in demonstrating the presence of acid fast bacilli. In the present study 2 cases on Ziehl–Neelsen staining were positive of acid fast bacilli which helped in giving diagnosis of tuberculous lymphadenopathy.

Problem arises in definite diagnosis in tuberculous lymphadenitis cases when Langhan's giant cell, and epitheloid cells are not seen in the smear or when smear contains only caseous material or pus. Hence in our study we had 2 false negative reports on FNAC for tuberculous lymphadenopathy being reported as reactive hyperplasia and nonspecific chronic lymphadenitis. There was no false positive report in the present study.

In the present study cervical group was most common affected with tuberculous lymphadenopathy with 19 out of 24 cases in cervical group (79.04%). The distribution of tuberculosis lymph nodes was 46.00% showing it to be most common cause of lymphadenopathy in the present study.

#### **V. Conclusion**

FNAC is a very useful diagnostic tool in patients having significant lymphadenopathy. The metastatic carcinomas, especially squamous cell carcinoma and tuberculous lymphadenopathy can be diagnosed by FNAC

with a high degree of accuracy. However the differentiating features are not well demarcated in reactive hyperplasia and Non-Hodgkin's lymphoma.

In the present study, accuracy was of 91.70% for tuberculous lymphadenitis which had improved because of Zeihl-Neelsen staining for acid fast bacilli. Therefore it must be stressed that when the fine needle aspirate appears purulent or when tuberculosis is clinically suspected, specimen should be stained for acid fast bacilli. It improves diagnostic capability of fine needle aspiration cytology.

In the present study, overall diagnostic accuracy was 80.00% for metastatic carcinoma and 100.00% for squamous cell carcinoma. Open biopsy for histological confirmation is gold standard. It has its limitations because it distorts the surgical planes and may increase risk of induction of tumour spread especially in metastatic upper and middle cervical lymph nodes which are potentially curable with radiotherapy or node dissection. FNAC is preferable and if it is positive surgeon can proceed to treat the neck without excisional biopsy of the enlarged lymph nodes. However supraclavicular lymphadenopathy rarely represents curable disease and so these nodes can be excised for histological confirmation.

In cases of metastasis of unknown origin to cervical and axillary lymphadenopathy FNAC is useful adjunct to diagnostic procedures and can point to primary depending upon the cell type.

Although FNAC is useful in clinical management, there are number of pitfalls in its use. There is significant limitation in the assessment of low grade Non-Hodgkin's lymphoma because of high false negative rate in cases of substantial non malignant component but FNAC can assess correctly high grade Non Hodgkin's lymphoma. The most difficult areas in diagnosis of lymph node disease by FNAC is differentiating low grade lymphoma from reactive hyperplasia. Lack of tissue architecture can be overcome on FNAC samples by subjecting them to dual parameter flow cytometry, T-cell, B-cell tumour markers and immunocytochemistry analysis. Finally we conclude that, FNAC is simple self reliable, cost effective diagnostic tool for lymphadenopathies but the limitation of the procedure should be kept in mind. If FNAC is negative it does not rule out the disease and should be followed by open biopsy for histopathological confirmation

#### **Annexure IV – Bibliography**

- [1]. Bielamowicz SA, Storper IS, Jabour BA. Spaces and triangles of head and neck. *Head Neck* 1994; 164: 383-8.
- [2]. Rouviere H. *Anatomy of the Human Lymphatic System*. Ann Arbor MI: Edward Bros. Inc; 1948.
- [3]. Fisch V. *Lymphography of the Cervical Lymphatic System*. Philadelphia: WB Saunders Co; 1968.
- [4]. Reede DL, Bergeron RT. The CT evaluation of the normal and diseased neck. *Semin Ultrasound CT. MR*. 1986; 7: 181-201.
- [5]. Shah JP, STrang E, Spiro RH. Neck dissection, current and future possibilities. *Clin. Bull*. 1981; 11: 25-33.
- [6]. Robins KT, Medina JE, Wolfe GT. Standardizing neck dissection terminology. Official report of the academy's committee for head and neck surgery and oncology. *Arch Otolaryngol Head and Neck Surg*. 1991; 117: 601-5.
- [7]. Mc. Gregor's L. *Synopsis of Surgical Anatomy*. 12<sup>th</sup> Ed. Bombay: K. M. Varghex Publishing house; 1999.
- [8]. Pitts WC, Weiss LM. *Neoplastic Hematopathology: The role of fine needle aspiration biopsy in diagnosis and management of hematopoietic neoplasms*. Baltimore: Williams and Wilkins; 1992.
- [9]. Silverberg S, Delellis RA, Frable WJ. *Principle and practice of surgical pathology and cytopathology: Lymph Nodes and Spleen*. 3<sup>rd</sup> Ed. London: Churchill Livingstone; 1997.
- [10]. Rappaport H. *Tumors of the hematopoietic system. Series I*. Washington, DC: Armed Forces Institute of Pathology; 1996.
- [11]. Strickler JG, Warnke RA, Weiss LM. Necrosis in lymph nodes. *Pathol. Annu*. 1987; 22(2) : 253-82.
- [12]. Cleary KR, Osborne BM, Butler JJ: Lymph node infarction foreshadowing malignant lymphoma. *Am. J. Surg. Pathol*. 1982; 6: 435-42.
- [13]. Cook MG. The size and histological appearance of mesenteric lymph nodes in Crohn's disease. *Gut* 1972; 13: 970-2.
- [14]. Bascom R, Johns CJ. The natural history and management of sarcoidosis. *Adv. Intern. Med*. 1986; 31: 213-41.
- [15]. Hollingsworth HC, Loingo DL, Jaffe ES. Small noncleaved cell lymphoma associated with florid epithelioid granulomatous response: A clinicopathologic study of seven patients. *Am. J. Surg. Pathol*. 1993; 17: 51-9.
- [16]. Sacks EL, Donaldson SS, Gordon J, Dorfman RF. Epithelioid granulomas associated with Hodgkin's disease: Clinical correlations in 55 previously untreated patients. *Cancer*. 1978; 41: 562-7.
- [17]. Van den Oord JJ, de Woolf-Peeters C, Facchetti F, Desmer VJ. Cellular composition of hypersensitivity type granulomas. Immunohistochemical analysis of tuberculous and sarcoid lymphadenitis. *Hum. Pathol*. 1984; 559-65.
- [18]. Reid JD, Wolinsky E. Histopathology of lymphadenitis caused by atypical mycobacteria. *Am. Rev. Respir. Dis*. 1969; 99: 8-12.
- [19]. Lukes RJ, Butler JJ. The pathology and nomenclature of Hodgkin's disease. *Cancer Res*. 1996; 26: 1063-81.
- [20]. Boring CC, Squires TS, Tong T. *Cancer statistics, 1993*. *CA Cancer J. Clin*. 1993; 43: 7-26.
- [21]. MacMahon B. Epidemiology of Hodgkin's disease. *Cancer Res*. 1966; 1159-1200.
- [22]. Weiss LM, Chang KL. The association of the Epstein – Barr virus with hemolymphoid neoplasia. *Adv. Anat. Pathol*. 1996; 3: 1-15.
- [23]. Weiss LM, Chen Y-Y, Liu X-F, Shibata D. Epstein-Barr virus and Hodgkin's disease: A correlative in situ hybridization and polymerase chain reaction study. *Am. J. Pathol*. 1991; 139: 1259-65.
- [24]. Kaplan HS. *Hodgkin's Disease*. Cambridge MA: Harvard University Press; 1980.
- [25]. Dass DK, Gupta SK, Datta BM, Sharma SC. Fine needle aspiration cytodagnosis of Hodgkin's disease and its subtypes: Scope and limitations. *Acta. Cytol*. 1989; 34: 329-36.
- [26]. Devasa SS, Fears T. Non-Hodgkin's lymphoma time trends: United States and International Data. *Cancer Res. suppl*. 1992; 52: 5432-40.
- [27]. Gail MH, Pluda JM, Rabkin CS. Projections of the incidence of non-Hodgkin's lymphoma related to acquired immunodeficiency syndrome. *J. Natl. Cancer. Inst*. 1991; 83: 695-701.
- [28]. Scherr PA, Hutchison GB, Neiman RS. Non-Hodgkin's lymphoma and occupational exposure. *Cancer Res. Suppl*. 1992; 52: 5503-9.
- [29]. Russell J, Skinner J, Orell S, Seshadri R. Fine needle aspiration cytology in the management of lymphoma. *Aust. NZ. J. Med*. 1983;

- 13: 365-8.
- [30]. Robert NJ, Garnick MB, Frei E. Cancers of unknown origin: current approaches and future perspectives. *Semin. Oncol.* 1983; 9: 526-31.
- [31]. Copeland EM, McBride CM. Axillary metastasis from an unknown primary site. *Ann. Surg.* 1973; 178: 25-7.
- [32]. Finkbeiner WE, Eghert BM, Groundwater JR, Sagebier RW. Kaposi's sarcoma in young homosexual men, a histopathologic study with particular reference to lymph node involvement. *Arch. Pathol. Lab. Med.* 1982; 106: 261-4.
- [33]. Chang Y, Cesarman E, Pessin MS. Identification of herpesvirus like DNA sequences in AIDS. Associated Kaposi's sarcoma. *Science* 1994; 26: 1865-9.
- [34]. Gnepp DR. Diagnostic surgical pathology of head and neck: Cyst of the neck, unknown primary tumour and neck dissection. Einband, Gebunden: W. B. Saunders; 2001.
- [35]. Kline TS. Handbook of fine needle aspiration biopsy. 2<sup>nd</sup> Ed. New York: Churchill Livingstone; 1998
- [36]. Shaha A, Webber C, Marti J. Fine needle aspiration in the diagnosis of cervical lymphadenopathy. *Am. J. Surg.* 1986; 152: 420-3.
- [37]. Lau SK, Wei WI, Hsu C, Engzell UCG. Efficacy of fine needle aspiration cytology in the diagnosis of tuberculous cervical lymphadenopathy. *The Journal of Laryngology and Otology.* 1990; 104: 24-27.
- [38]. Sarda Ak, Bal S, Singh MK, Kapur MM. Fine needle aspiration cytology as a preliminary diagnostic procedure for asymptomatic cervical lymphadenopathy. *J. Assoc. Physicians India.* 1990; 38(3): 203-5.
- [39]. Gupta AK, Nayar M, Chandra M. Reliability and limitations of fine needle aspiration cytology of lymphadenopathies: An analysis of 1,261 cases. *Acta Cytologica.* 1991; 35(6): 777-83.
- [40]. Prasad R, Garg SK, Mukerji PK, Agarwal PK. Role of fine needle aspiration cytology in the diagnosis of lymphadenopathy. *Indian J. Chest. Dis. Allied Sci.* 1993; 35(1) 27-9.
- [41]. Shapiro AL, Pincus RL. Fine needle aspiration of diffuse cervical lymphadenopathy in patients with acquired immunodeficiency syndrome. *Otolaryngol Head Neck Surg.* 1991; 105: 419-21.
- [42]. Lee DW, Jin SY, Kim DW. Diagnostic usefulness of fine needle aspiration cytology on lymphadenopathy: An analysis of 1,216 cases. *Acta. Cytol.* 1998; 42: 523.
- [43]. Reyes CV, Thompson KS, Jensen JD, Choudhary AM. Metastasis of unknown origin: The role of fine-needle aspiration cytology. *Diagn. Cytopathol.* 1998; 18(5): 319-22.
- [44]. Haque MA, Talukder SI. Evaluation of fine needle aspiration cytology FNAC of lymph node in myensingh. *Memensingh Med. J.* 2003; 12(1) 33-5.
- [45]. Bhargava P, Jain AK. Chronic cervical lymphadenopathy: A study of 100 cases. *I. J. S.* 2002; 64(4): 344-6.
- [46]. Das DK, Gupta SK, Datta BN, Sharma SC. FNA cytodiagnosis of Non-Hodgkin's lymphoma and its subtyping, under working formulation of 175 cases. *Diagn. Cytopathol.* 1991; 7: 489-98.
- [47]. Kline TS. Handbook of fine needle aspiration biopsy: Lymph nodes and superficial masses. St. Louis: C. V. Mosby; 1981
- [48]. Narang RK, Pradhan S, Singh RP, Chaturvedi S. Place of fine needle aspiration cytology in the diagnosis of lymphadenopathy. *Indian J. Tuber.* 1990; 37: 29.