

## Bilateral Two Rooted Mandibular Second Premolars: Report of an unusual Case

Dr. Mallayya C. Hiremath<sup>1</sup>, Dr. Pooja Srivastava<sup>2</sup>

<sup>1</sup>(Associate Professor, Department of Pedodontics and Preventive dentistry, Government Dental College and Research Institute, Bangalore, India)

<sup>2</sup>((Post graduate student, Department of Pedodontics, Government Dental College and Research Institute, Bangalore, India)

---

**Abstract :** The mandibular second premolar is usually described as a single rooted tooth with a single root canal. However, two root canals may be found but the occurrence of two roots is extremely rare. The reported studies have shown 0.3% prevalence of two roots in mandibular second premolars. This report describes an unusual case of a thirteen year old female patient with bilateral two rooted mandibular second premolars. The patient reported for root canal therapy of decayed mandibular first permanent molar and the presence of bilateral two rooted mandibular second premolars was detected coincidentally. The clinicians should be aware of the presence of anatomical variations in the teeth during endodontic treatment.

**Keywords -** Mandibular second premolar, number of roots, root morphology, root canal morphology.

---

### I. Introduction

The basic knowledge of root and root canal morphology and its variations is very important for successful endodontic treatment.<sup>1</sup> Mandibular second premolar is typically described in textbooks as single rooted tooth with a single root canal system. The ovoid-shaped root in cross section normally has developmental grooves or depressions on the mesial and distal surfaces.<sup>1,2</sup>

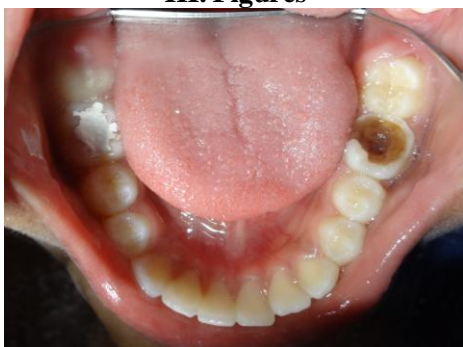The anatomic studies reported on the prevalence of number of roots and root canals in mandibular second premolars are limited.<sup>3,4</sup> Anatomic studies have reported a single root in 99.6% of these teeth. Two roots were found in 0.3% of these teeth. Three roots were found in only 0.1% of mandibular second premolars.<sup>4</sup> Although uncommon, possible morphological anomalies reported in the literature include mandibular second premolars with two roots and two canals<sup>5</sup>, three roots and three canals<sup>6</sup> and four canals in one root.<sup>7</sup> Sachdeva et al<sup>8</sup>, reported a case of mandibular second premolar with four roots and four root canals using spiral Computed Tomography. But bilateral occurrence of anomalies in root morphology of mandibular second premolars are rarest. The purpose of this article is to report an unusual case of bilateral two rooted mandibular second premolars.

### II. Case Report

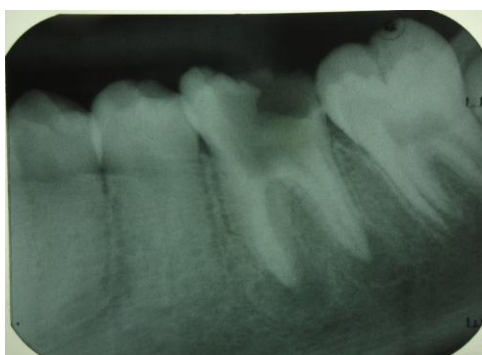A thirteen year old female patient reported to the department of Pediatric Dentistry with a chief complaint of decayed left mandibular permanent molar. The medical history was noncontributory. Clinical examination revealed a large carious lesion involving pulp in relation to 36 (figure-1). To assess the periapical region and root canal morphology an intraoral periapical radiograph was taken with respect to 36. The intraoral periapical radiograph showed large carious lesion involving pulp and periapical radiolucency with respect to 36 and anomalous root morphology with respect to 35 (figure-2). Conventional root canal therapy was planned with respect to 36. Access opening was made and four root canal orifices were located. Working length intraoral periapical radiograph was made by changing the horizontal angulation and four root canals (MB, ML, DB and DL) were found (figure-3). Coincidentally we noticed bifurcated root (mesial and distal) in relation to mandibular left second premolar (figure-3). The presence bifurcated root in relation to 35 arose curiosity in us to look for contralateral premolar root morphology. Thus an intraoral periapical radiograph was made with respect to 45, which also showed bifurcated root (mesial and distal) morphology (figure-4). Such bilateral root anomaly in mandibular second premolars is a rare finding and it was confirmed with a second radiograph taken at a different horizontal angulation.

In subsequent visits the root canals of 36 were obturated with gutta percha by lateral condensation technique and the root canal treatment was completed. The decayed 16 and 46 were restored with silver amalgam. An orthopantomograph (OPG) was made to rule out other anomalies and to confirm the presence of bilateral bifurcated roots in mandibular second premolars (figure-5). Stainless steel crown was placed as an interim restoration with respect to 36 and the treatment was completed (figure-6).

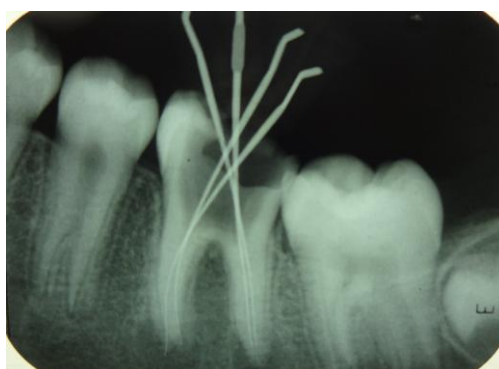
**III. Figures**



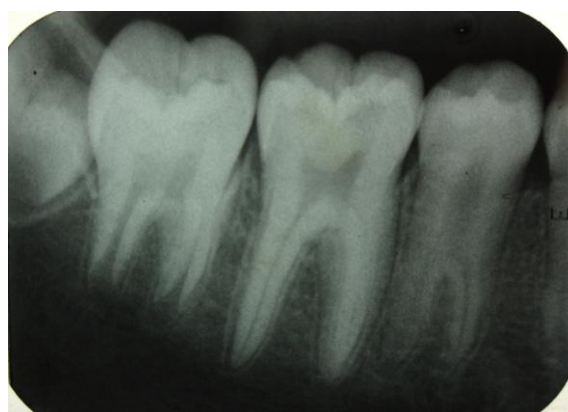**Figure-1.** Intra oral photograph showing a large carious lesion involving pulp with 36 and temporary restoration with 46.



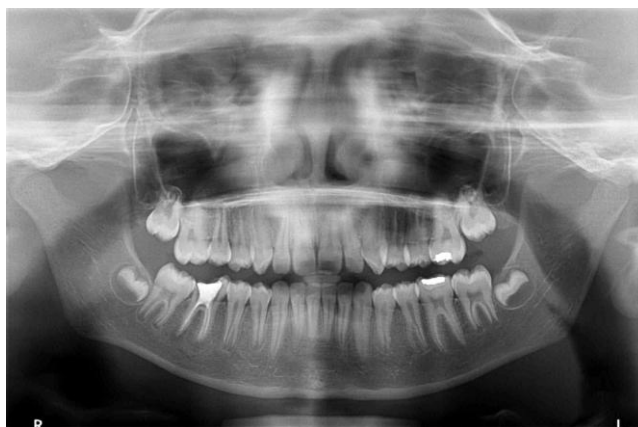**Figure-2.** IOPA Radiograph showing a large carious lesion involving pulp in relation to 36 and anomalous root outline in relation to 35.



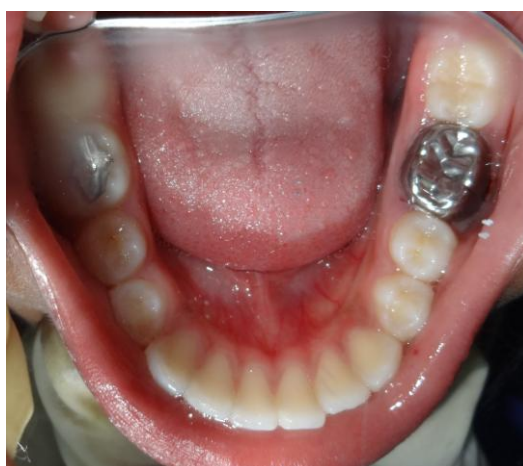**Figure-3.** Working length IOPA radiograph showing four root canals (MB, ML, DB and DL) in relation to 36 and bifurcated root (M and D) in relation to 35.



**Figure-4.** IOPA radiograph showing bifurcated root (M and D) in relation to 45.



**Figure-5.** Orthopantomograph (OPG) showing the completed root canal therapy with 36 and presence of bilateral bifurcated roots with mandibular second premolars.



**Figure-6.** Post-operative intra oral photograph showing Stainless steel crown with respect to 36 and silver amalgam restoration with 46.

#### **IV. Discussion**

An awareness of the anatomical variations in the root and root canal morphology of mandibular second premolars is essential if the clinician has to achieve a high degree of success in endodontic therapy.<sup>8</sup> Mandibular premolars have gained a reputation for having aberrant anatomy. The reported incidence of both extra roots and extra root canals in mandibular second premolar was lower than that found in the mandibular first premolar.<sup>4,6,9</sup> Anatomic studies reported have shown a single root in 99.6% of the mandibular second premolars. Two roots were found in 0.3% of these teeth. Three roots were found in only 0.1% of mandibular second premolars. Anatomic studies on the root canal morphology of mandibular second premolars have reported a single canal in 91.0% of the teeth. Two or more canals were found in 9% of the teeth studied.<sup>4</sup>

Serman and Hasselgren,<sup>9</sup> in their radiographic survey reported that supernumerary roots and root canals in mandibular premolar teeth were mostly situated bucco-lingually. The incidence of extra roots in mesio-distal location was uncommon.<sup>9</sup> In the case reported here, the mesio-distal branching of mandibular second premolar root was quite significant and it was confirmed with a second radiograph taken at a different horizontal angulation. The root bifurcation was present bilaterally which is rarely seen. The presence of two roots is an advantage for bridge fabrication but disadvantage during root canal therapy and extraction.<sup>5</sup> From a clinical standpoint, when the initial radiograph shows the image of an unusual anatomic root form it is recommended to take a second radiograph for additional information.<sup>10</sup> A second radiograph with 15–20 degrees horizontal angulation from either mesial or distal side of the long axis of the root is necessary to accurately diagnose the number of roots and root canals in premolar teeth.<sup>6,10</sup>

Radiographs produce two dimensional image of a three dimensional object resulting in superimposition of images. Hence they are of rather limited value in cases with complex root canal anatomy. Taking into consideration that so many morphological variations exists in teeth, use of superior diagnostic aids and knowledge of anatomical variations can help the clinician to identify and treat multiple root canal systems in mandibular premolars successfully.<sup>8</sup> The advent of 3D imaging has provided the endodontist with tools that were not available to the clinician before and facilitated interactive image manipulation and enhancement to

visualize the area of interest. 3D imaging will find more applications in endodontics in future as technology continues to advance.<sup>8</sup>

The use of 3-dimensional imaging methods in future large anatomic studies would be of value in assessing the occurrence and frequency of anomalous root canal morphology. The role of genetics is also being appreciated in identifying anomalies caused by syndromes and even ethnicity variations in root morphology.<sup>4</sup>

### **V. Conclusion**

The diagnosis and management of extra roots and root canals in mandibular second premolars is undoubtedly an endodontic challenge. Radiographs taken from different angulations can help in identifying these abnormal root anomalies and increase the success of endodontic treatment.

### **References**

- [1]. Ingle J, Bakland I. Endodontics. 5<sup>th</sup> ed. Hamilton: BC Decker, 2002.
- [2]. Ash M, Nelson S. Wheeler's dental anatomy, physiology and occlusion. 8<sup>th</sup> ed. Philadelphia: Saunders, 2003.
- [3]. Vertucci FJ. Root morphology of mandibular premolars. J Am Dent Assoc 1978;97:47-50.
- [4]. Cleghorn BM, Christie WH, Dong CC. The root and root canal morphology of the human mandibular second premolar: a literature review. J Endod 2007;33:1031-1037.
- [5]. Goswami M, Chandra S, Chandra S, Singh S. Mandibular premolar with two roots. J Endod 1997;23:187.
- [6]. Mukhaimer RH. Bilateral mandibular second premolars with three separate roots. Saudi Endod J 2012;2:156-160.
- [7]. Wong M. Four root canals in a mandibular second premolar. J Endod 1991;17:125-126.
- [8]. Sachdeva GS, Ballal S, Gopikrishna V, Kandaswamy D. Endodontic management of a mandibular second premolar with four roots and four root canals with aid of spiral computed tomography: A case report. J Endod 2008;34:104-107.
- [9]. Serman NJ, Hasselgren G. The radiographic incidence of multiple roots and canals in human mandibular premolars. Int Endod J 1992;25:234-237.
- [10]. Fava LR, Dummer PM. Periapical radiographic techniques during endodontic diagnosis and treatment. Int Endod J 2003;36:912-919.