

## Male Breast Carcinoma – A Cytological Study & Clinicopathological Correlation of a Case

Nanda Patil<sup>1</sup>, Dhiraj kumar Shukla<sup>2</sup>, Pankti M. Patel<sup>2</sup>

<sup>1</sup>, Associate Professor, Department of Pathology, Krishna Institute of Medical Sciences, Karad.

<sup>2</sup>, Assistant Lecturer, Department of Pathology, Krishna Institute of Medical Sciences, Karad

**Abstract:** Carcinoma of a breast is rare in men accounting for 0.6% of all breast cancers and less than 1% of malignancies in men. Risk factors are same as that of female breast cancer. Poor prognosis of this cancer is attributed to late age of presentation. We present a case of male breast cancer diagnosed with cytology in a 73 year old male patient to highlight its rarity and to increase the awareness.

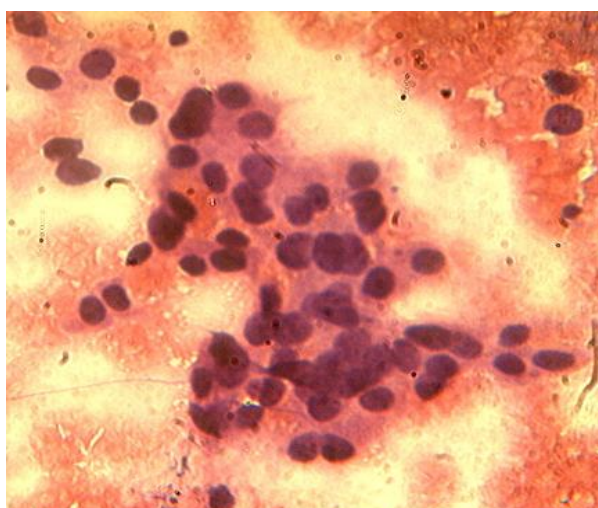
**Keywords:** Breast cancer, Male, Prognosis.

### I. Introduction

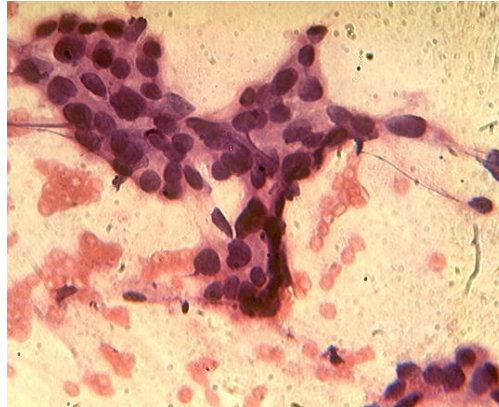
Breast carcinoma rarely affects men accounting for less than 1% of all breast cancers and all cancers in men.<sup>1</sup> Risk factors for male breast carcinomas are same as that for female breast cancers with positive family history being the main predisposing factor.<sup>1</sup> Male breast carcinoma has a poorer prognosis as compared to female breast carcinoma, which has been attributed to the late presentation of the patient to the clinicians.<sup>2</sup> We report here a case of 73 years old man diagnosed as breast carcinoma on fine needle aspiration cytology.

### II. Case Report

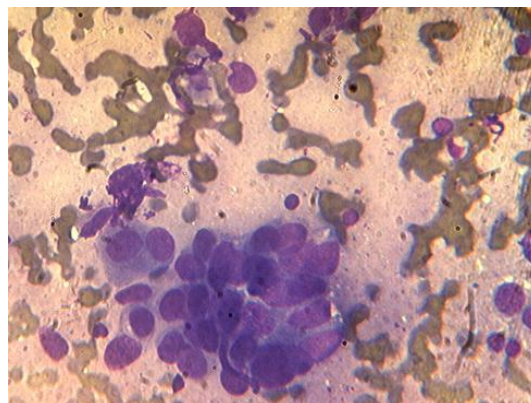
A 73 years old man reported to the out patient department of surgical oncology with a 2 cm diameter lump in left breast of 4 years duration without any palpable axillary lymph nodes. Nipple, areola and overlying skin appeared unremarkable. There was no history of trauma, familial breast cancers, gynaecomastia, solid organ tumor, hormonal treatment or any other malignancy. Routine hematological, biochemical investigations were normal. Patient was advised fine needle aspiration cytology (FNAC) of the lump. FNAC yielded hypercellular smears showing neoplastic cells arranged in loosely cohesive clusters, scattered singly (Figure 1, Figure 2, Figure 3) as well as forming acinar pattern. Individual cells showed large pleomorphic vesicular nuclei, coarse chromatin, prominent nucleoli and moderate to ample amount of cytoplasm. Background of the smears showed necrotic debris, inflammatory cells and haemorrhagic material. On the basis of these finding, diagnosis of duct carcinoma was given.



**Figure 1: Photomicrograph showing loosely cohesive cluster of neoplastic ductal epithelial cells with nuclear anaplasia. H & E, 400x**



**Figure 2: Photomicrograph showing loosely cohesive cluster of neoplastic ductal epithelial cells with nuclear anaplasia. H & E, 400x**



**Figure 3: Photomicrograph showing loosely cohesive cluster of neoplastic ductal epithelial cells with nuclear anaplasia. Leishman stain, 400x**

### III. Discussion

Male breast carcinoma represents 0.6% of all breast carcinomas and <1% of all malignancies in men. Male breast carcinoma being rare condition, limited information is available regarding the epidemiology, treatment and prognosis of this disease.<sup>3</sup> Men have more advanced disease at presentation compared with women which may be attributed to late presentation, lack of public awareness of breast cancer in men which subsequently leads to delay in diagnosis. Median age at diagnosis of breast cancer in men is 67 years compared with 62 years for women.<sup>2</sup>In the present case, patient is 73 year old and presented very late. Several risk factors for male breast carcinoma has been proposed such as familial and genetic factors, radiation exposure, Klinefelter's syndrome, hormonal imbalance, undescended testis, obesity, orchitis and orchiectomy.<sup>4,5</sup> No such risk factors were noted in the present case.

A painless lump beneath the areola, usually discovered by the patient himself is the most common presenting symptoms in the male breast carcinoma. Tumor size is usually less than 3 cm in diameter but associated with nipple retraction, discharge and fixation of breast tissue to skin and muscles. Approximately half of men with breast carcinoma have palpable axillary lymph node.<sup>5</sup>In the present case, patient presented with 2 cm diameter lump in left subareolar region without any sign of nipple retraction. Tumor was fixed to skin. Axillary lymph node was not palpable.

FNAC of the breast lump plays an important role in the diagnosis and further management of the lump. FNAC can be effectively used in a male patient to differentiate malignant from non-malignant disease. In the present case, FNAC of the lump was diagnosed positive for duct carcinoma. Further management of the patient could not be initiated on as the patient was lost to follow up.

As noted in women, invasive ductal carcinoma form the major bulk of the cases of male breast carcinomas. Papillary carcinomas are comparatively more common and lobular carcinomas are rarer in men.<sup>6</sup>

Tumor size and axillary lymph node involvement are independent prognostic markers for diagnosis of male breast cancer.<sup>3,7</sup> Higher survival rate of upto 85% are seen with tumor size of <2 cm. A higher tumor grade is associated with a poor prognosis and a significant difference in 5 year survival.<sup>8</sup>

In the present case, tumor size was small i.e. 2 cm in diameter but grade of the tumor could not be determined as patient was lost to follow up.

Surgical examination of the tumor is required, radiotherapies, hormone therapy and chemotherapy constitute an essential part of the adjuvant therapy.

#### **IV. Conclusion**

Male breast carcinoma being a rare condition having worse prognosis than female breast carcinoma owing to poor level of awareness and delayed presentation and diagnosis. FNAC is an important tool in early diagnosis of male breast carcinoma leading to prompt management of the condition.

#### **References**

- [1]. Rizzolo P, Silvestri V, Tommasi S, Pinto R, et al. Male breast cancer: genetics, epigenetics and ethical aspects. *Annals of Oncology* 2013; 24( 8):75-82.
- [2]. Melenhorst J, Van berlo C.L.H., Nijhuis P.H.A. Simultaneous Bilateral Breast Cancer in a Male: a Case Report and Review of the Literature. *Actachir belg*,2005;105:531-532.
- [3]. Giordano S, Cohen D, Buzdar A, et al. Breast Carcinoma in Men. *Cancer*. 2004;101(1):51-57.
- [4]. Hill A, Yagmur T, Tran KN, et al. Localized male breast carcinoma and family history. An analysis of 142 patients. *Cancer* 1999;86(5):821-5.
- [5]. Sarru E, Mudarris F, Amr S. MALE BREAST CANCER – CASE REPORT AND BRIEF REVIEW. *Middle East Journal of Family Medicine*, 2004;Vol.6(6).
- [6]. Ruddy K, Winer E. Male breast cancer: risk factors, biology, diagnosis, treatment and survivorship. *Annals of Oncology*. 2013;00:1-9.
- [7]. Yildirim E, Berberoglu U. Male breast cancer: a 22 year experience. *Eur J Surg Oncol*.1998;24:548-52.
- [8]. Ribeiro G, Swindell R, Harris M, et al. A review of the management of the male breast carcinoma based on an analysis of 420 treated cases. *The Breast*.1996;5:141-6.