

Diagnostic Role of CT in the Evaluation of Proptosis

Dr.K.Sambasivarao¹, Dr.B.Ushalatha²

¹. Assistant Professor, Radiodiagnosis, Rangaraya Medical college, Kakinada, Dr.NTR University of Health sciences, INDIA

². Assistant Professor, Ophthalmology, Rangaraya Medical college, Kakinada, Dr.NTR University of Health sciences, INDIA

Abstract:

Objectives: To analyze the Diagnostic role of Computed Tomography in the evaluation of proptosis.

Material And Methods: 80 patients presenting with proptosis were evaluated for CT scan Orbits. Role of CT was evaluated in characterizing the precise location and extension of the lesions causing proptosis. Final diagnosis was made based on the histopathology, operative findings and clinical outcome.

Results: Most common cause of proptosis was Orbital tumors(38.75%) followed by Pseudotumor(12.5%). Among the Tumors Lymphoma and Optic nerve Glioma were the common lesions. Pseudotumor(12.5%) and Graves disease (10%) are the inflammatory causes. Other causes of proptosis include infections (15%), paraorbital tumors (12.5%), Trauma (8.75%) and vascular causes (2.5%). Accuracy of Computed Tomography in the diagnosis of etiology of proptosis was 85%

Conclusion: Computed tomography is the simple, cost effective technique in the evaluation of proptosis with the accuracy of 85%.

Keywords: Computed Tomography; Inflammation, Infections ,Proptosis; Tumors.

I. Introduction

Proptosis is defined as an abnormal protrusion of the eyeball. If the distance between the lateral orbital rim to corneal apex is more than 21 mm or a difference of 2 mm between the eye positions is considered as proptosis. Proptosis can result from a variety of disease processes including infective, inflammatory, vascular, neoplastic, traumatic, endocrine lesions and extraorbital lesions.

The evaluation of proptosis include a detailed clinical history , ocular examination, laboratory investigations & imaging studies .As far as the radiological investigations are concerned , findings on plain radiographs & ultrasonography are not pathognomic of most of the orbital disease process though some help can be obtained in characterization of lesion in certain cases. Advent of MRI & CT has revolutionized the diagnostic imaging of orbit & its contents. MRI with its superb soft tissue contrast & multiplanar ability provides excellent rendering of orbital anatomy but is limited by lack of wider availability & high cost. On the other hand easy availability and operability, good maintenance and speed makes CT scan an affordable diagnostic tool in orbital diseases under existing circumstances and present set up.

II. Material And Methods

80 patients of various age groups & both sexes with unilateral or bilateral proptosis that were referred to the Department of Radiodiagnosis from the Department of Ophthalmology for Computed Tomography of Orbits over a period of 9months between April 2013 to December 2013 were the subjects for the study. Before commencing for CT examination, all the preceding history, clinical, laboratory data were recorded. A CT scanner (SIEMENS SOMATOM DUAL SLICE) was used for the study. The technique was to obtain a lateral scannogram with the patient supine and contiguous axial sections with slice thickness of 3 mm and interslice gap of 3 mm were obtained. Coronal 3-5 mm sections were obtained as and when required with the patient in prone position. The scans were obtained both prior to and after administration of non ionic intravenous contrast. All patients with globe protrusion >21mm anterior to the interzygomatic line on axial scans at the level of lens were evaluated .CT findings were correlated with final diagnosis based on clinical, laboratory findings , operative findings , histopathological study or response to treatment.

III. Results

The patients included were from 2 to 65 yrs. of age. The majority of patients (22%) were between 31-40 yrs. of age. man/woman ratio was 1:1.28. The results were shown in Table:1. Most common cause of proptosis was Orbital tumors (38.75%) followed by Pseudotumor(12.5%).

Table :1 Total Cases

SL.NO	DIAGNOSIS	FREQUENCY	%	ADULT	CHILDREN
1	ORBITAL TUMORS	31	38.75%	12	19
2	PARAORBITAL TUMORS	10	12.5%	8	2
3	ORBITAL PSEUDOTUMOR	10	12.5%	10	-
4	GRAVES DISEASE	8	10%	8	-
5	ORBITAL CELLULITIS	8	10%	2	6
6	PNS INFECTIONS	4	5%	4	-
7	TRAUMA	7	8.75%	7	-
8	VASCULAR CAUSES	2	2.5%	2	-

Tumours :

Orbital tumors (38.75%) are the most common cause of proptosis in our study. Lymphoma and Optic nerve Glioma were the most common orbital tumors(8.75%) shown in Table.2. Lymphoma is the most common orbital tumour in adults(41.6%). Lymphoma (Figure.1) appeared as homogenously enhancing soft tissue masses in extraconal space with involvement of intraconal space in four patients . Extraocular muscles were involved in all patients and Optic nerve involvement was seen in one patient.

Table :2 Orbital Tumors

SL.NO	DIAGNOSIS	FREQUENCY	%	ADULTS	CHILDREN
1	ORBITAL LYMPHOMAS	7	22.5%	5	2
2	OPTIC NERVE GLIOMA	7	22.5%	-	7
3	RHABDOMYOSARCOMA	4	12.9%	1	3
4	MENINGIOMAS	3	9.6%	3	-
5	METASTASES	2	6.4%	1	-
6	HEMANGIOMA	3	9.6%	-	3
7	DERMOID CYST	3	9.6%	-	3
8	LACRIMAL GLAND TUMOR	1	3.2%	1	-
9	RETINOBLASTOMA	1	3.2%	-	1

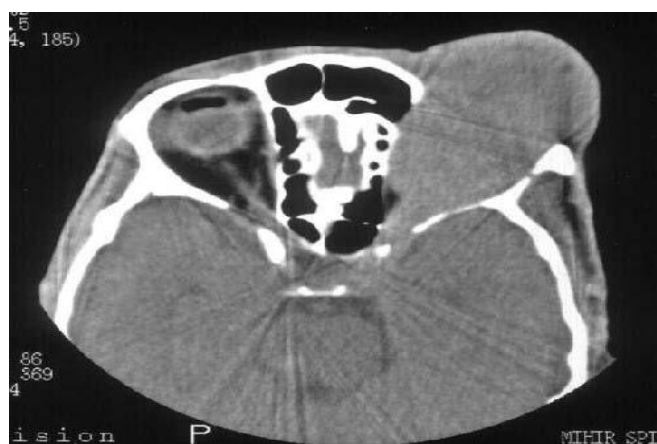

Figure.1. Plain CT of the orbit showed a hypodense mass involving the Extraocular muscles and Optic nerve with scalloping of the lateral and medial walls of the left orbit- Lymphoma

Optic nerve Glioma was the most common pediatric orbital tumour (36.8%) causing proptosis. The lesion was diagnosed with a characteristic fusiform enlargement involving optic nerve with mild to moderate contrast enhancement. In two patients widened optic canal was noted. Four patients of Rhabdomyosarcoma (5%) presented as homogeneously enhancing extraconal masses with involvement of extraocular muscles in all four patients. Epidural extension was seen in one patient. Three out of four cases of Rhabdomyosarcoma were seen in children.

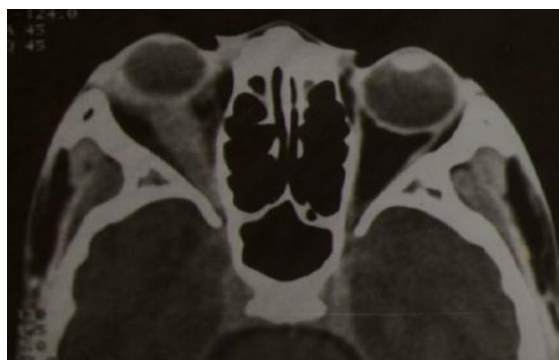

Figure .2. CECT show fusiform enlargement of right optic nerve with mild enhancement

Meningiomas were found in 3 cases (3.75%). One case was an optic nerve sheath meningioma (ONSM) Figure .3. while other were at parasellar and suprasellar regions with orbital extension. On CT they appeared as well defined hyper dense homogeneously enhancing intraconal mass with central lucency (Optic nerve) with calcification and Minimal sclerosis of adjacent bones.

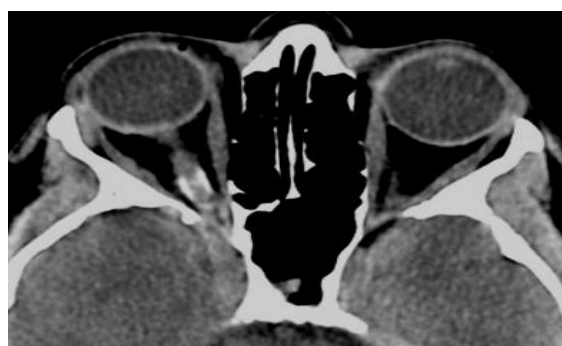

Figure.3. Plain CT show calcification along the right optic nerve - ONSMeningioma

Two patients in our study presenting with proptosis were proved to be metastases in the orbit. One of the patients presenting with extraconal masses in superolateral quadrants in left orbit Figure.4. was proved to be a case of Ewings sarcoma. One patient was a follow up case of Carcinoma breast and was shown to have metastatic extraconal mass in the left orbit.

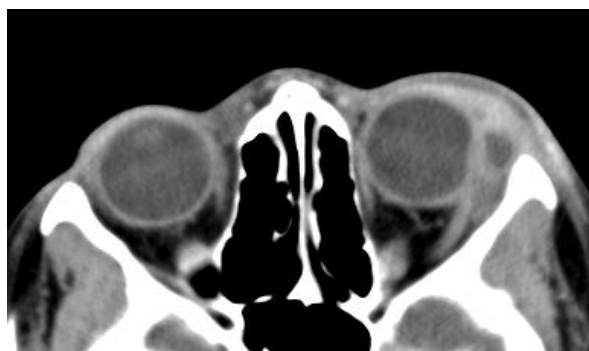


Figure.4. CECT show minimally enhancing extraconal lesion of left orbit

Hemangioma appeared as Well defined capsulated hyperdense intraconal mass with moderate enhancement in three patients Figure.5.

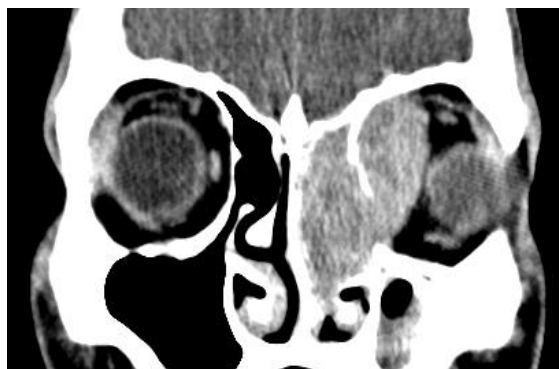

Figure.5. well defined moderately enhancing intraconal mass- Hemangioma

In our study Retinoblastoma was unilateral in the left orbit of a 2 years old female child. On CT Retinoblastoma revealed homogeneously enhancing masses involving whole of the eyeball with Calcification and thickening of the Optic nerve. Pleomorphic adenoma of Lacrimal gland was found in 1 case . Pleomorphic adenoma presented on CT as heterogeneously enhancing mass lesion in superolateral part of orbit with proptosis The most common paraorbital tumor (12.5%)invading the orbit in our study was maxillary carcinoma(6.25%). In five patients maxillary carcinoma Figure.6. appeared as heterogeneously enhancing masses involving the maxillary sinus, nasal cavity, ethmoid sinuses, infratemporal fossa with bone destruction and extension into the orbit. In one patient squamous cell carcinoma of ethmoid sinus appeared as heterogeneously enhancing mass with bone destruction and extension into the orbit.

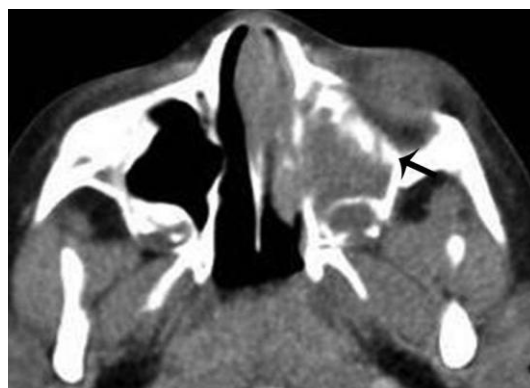

Figure.6. Plain CT show heterogenous mass with destruction of medial wall of left orbit.

In two cases(2.5%) of Nasopharyngeal carcinoma proptosis were due to involvement of cavernous sinuses and orbital extension with bony destruction at base of skull with intracranial extension. Unilateral orbital extensions was seen in 1 case while extension in bilateral orbits was seen in the other. On CT they appeared as enhancing mass on roof and lateral wall of nasopharynx with bony destruction and orbital extension. Two patients (2.5%) of Angiofibroma Figure.7. presented as soft tissue masses with intense homogenous enhancement involving nasal cavity, pterygopalatine fossa, ethmoid sinuses, infratemporal fossa with extension through inferior orbital fissure into the orbit.

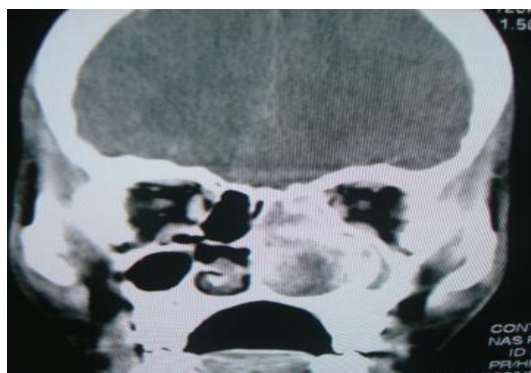


Figure.7. CECT show intense enhancing mass involving left nasal cavity

Inflammation: Amongst ten patients (12.5%) of inflammatory pseudotumor Figure.8. of the orbit, unilateral involvement was more common (eight patients) than bilateral (two patients). Muscle involvement was seen in eight patients with multiple muscle involvement being more common. Muscle enlargement was diffuse involving the tendinous insertions. Lacrimal gland was enlarged in one patient. Soft tissue infiltration of orbital fat was seen in five patients with infiltration up to orbital apex in one patient. Optic nerve was infiltrated in one patient.

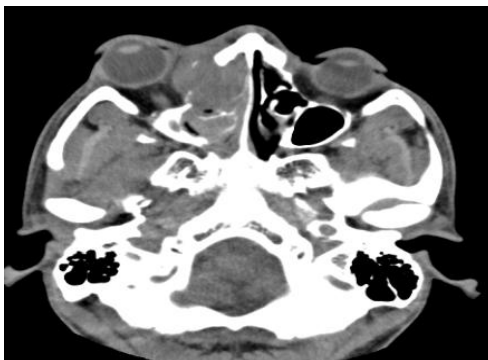

Figure.8. plain CT show homogenous extraconal mass involving right orbit .

Amongst eight patients(10%) of Grave's disease, bilateral involvement was seen in six patients and unilateral involvement Figure.9. in two. Extraocular muscle enlargement was seen in all patients with multiple muscle involvement being more common than single muscle involvement. Inferior rectus muscle was most commonly enlarged followed by medial rectus and superior rectus.

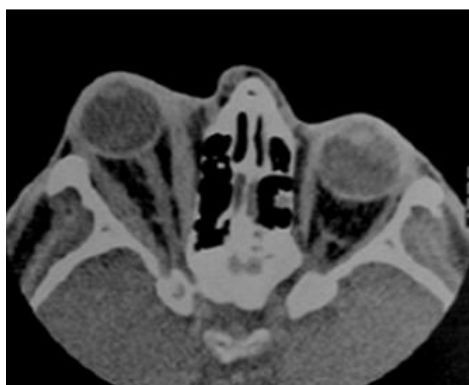

Figure.9. plain CT show thickening of medial and lateral rectus muscles of right orbit.

Infections: Amongst eight patients of orbital cellulitis Figure.10.in our study, subperiosteal involvement was the most common and seen in four patients. Preseptal extension was seen in 3 cases showing increased density of the soft tissues. Formation of subperiosteal abscess with medial enhancing rim was seen in one patient. Diffuse orbital involvement was seen in two patients with increased density of soft tissues in both intraconal and extraconal spaces. Concurrent paraorbital sinus infections were seen in four patients.

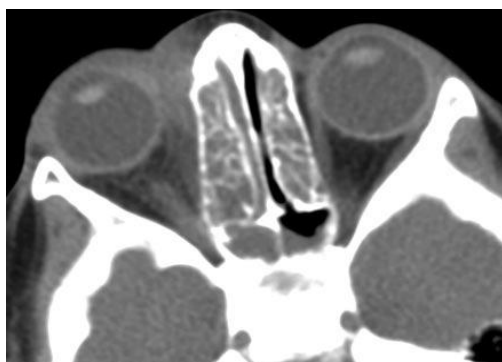

Figure.10. plain CT show increased attenuation with thickening of pre and post septalfat with opacification of ethmoid and sphenoid sinuses.

Trauma: All seven patients of orbital trauma had intraorbital haemorrhage Figure .11. (retrobulbar and preseptal). Fracture of the bony orbit was seen in all patients with evidence of haemorrhage in paranasal sinuses in all.

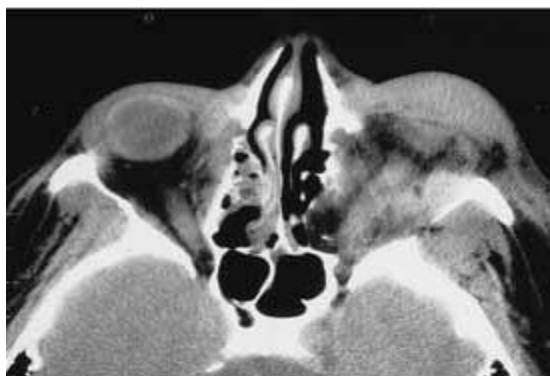


Figure .11. plain CT show increased and heterogenous attenuation with few air foci in the preseptal and retrobulbar compartments – orbital hemorrhage

Vascular :

In our study there were a case of post traumatic pseudoaneurysm and carotico cavernous fistula presenting as pulsatile exophthalmos. CT findings included proptosis, asymmetry and distension of affected cavernous sinus and congestion and asymmetrical dilatation of superior ophthalmic vein.

IV. Discussion

The most common cause of proptosis in our study were Tumours(38.75%). Our findings correlated well with the findings of Masud MZ et al (2006) [1] who described tumors (33%) as the most common cause of proptosis in their study. Lymphomas and Optic nerve Gliomas (7 cases each) were the most common orbital tumours in our study. Margo CE et al (1998) [2] reported orbital lymphoma to be the most common malignant orbital tumours. Orbital tumors are commonly seen in children as compared to adults (71%vs39%). Lymphoma(5) was the most common orbital malignancy in adults followed by Meningioma(3), Metastases(2) . Gliomas(7) were most common in children followed by Rhabdomyosarcoma (3), Hemangioma(3) , Dermoid(3) and Lymphoma(2) .

The most common paraorbital tumor invading the orbit in our study was maxillary carcinoma(5%) similar to that described by Johnson LN et al (1984) [3]. Out of 31 patients of tumours CT diagnosis correlated with histopathological diagnosis in 27 patients (87%). In a study by Sabharwal et al (2006) [4] there was 78% correlation between the CT diagnosis and histopathological diagnosis of orbital neoplasms.

Accurate evaluation of orbital tumours is most important for therapeutic management .orbital tumors are relatively surgically inaccessible for biopsy due to presence of bony walls. This gives rise to a need for effective methods of indirect assessment of the orbit prior to definitive therapy. USG, CT and MRI are the modality of choice in the assessment of orbital tumors but each has its own limitation. This enables the clinician to delineate the extent of disease and plan the surgical approach for biopsy and excision. In some cases serial orbital imaging is used to monitor for diseases status.

Pseudotumor accounted for 12.5% patients of proptosis in our study compared to the study by M K Narula et al (1994) [5] where pseudotumor accounted for 11% patients of proptosis. Correct diagnosis of pseudotumour was made in 60% patients in our study in view of the non specific radiological findings as stated by Alfred L Weber et al [6]. In all our patients combined clinical and radiological findings were confirmatory and hence none of them required biopsy and responded well with steroid with complete resolution on follow up CT. Graves disease accounted for 10% patients of proptosis is similar to the study conducted by Sabharwal et al (2006) [4] . Inferior rectus muscle was most commonly enlarged followed by medial rectus and superior rectus similar to the study by Murakami et al (2001) [7].Correct diagnosis of Graves disease was made in 6 out of 8 (75%) patients on CT in the present study. In a study by Ozgen et al (1999) [8] diagnosis of Graves ophthalmopathy was made in 69 of 87 (79%) patients using CT.

Infectious pathology accounted for 15% patients of proptosis in our study while in study by Masud MZ et al (2006) [1] infections accounted for 20% patients of proptosis. Orbital cellulitis was predominantly seen in children (6 vs 2 cases). Paraorbital infections are the next common cause. CT provided an accurate diagnosis in 83.3% patients of orbital cellulitis in our study. Clary RA et al (1992) [9] analysed the accuracy of CT in orbital cellulitis in children and showed correlation between radiological and operative findings in 84.21% cases.

Trauma was the cause in 8.75% patients of proptosis in the present study. Our results are similar to the study done by Masud MZ et al (2006) [1] where trauma was the cause of proptosis in 5% patients. CT showed 100% accuracy in the detection of complex orbital rim and wall fractures, where xrays failed to detect some of these fractures. CT clearly depicted the status of orbital soft tissues in relation to fractures. We believe CT is much more superior in case of trauma to the orbit.

In our study vascular lesions were the least common accounting for 2.5% patients of proptosis while in a study by Sabharwal et al (2006) [4] 2 % cases of proptosis were caused by vascular lesions. Contrast enhanced CT showed a 100% accuracy in the detection of a case of carotico-cavernous fistula and posttraumatic pseudoaneurysm.

In the present study overall CT diagnosis was found to be correct in 68 patients (85%). Our results are similar to the study of Zahir Shah Mahsud et al (2004) [10], In their study the diagnostic accuracy of CT scan in evaluation of proptosis was 80%. CT scan is highly useful in describing the precise location and extent of the lesion and is fairly accurate in lesion characterization. In view of non specific findings in cases of orbital tumours and pseudotumours, an evaluation of clinical and laboratory data is essential to arrive at a precise diagnosis.

V. Conclusion

CT is useful to characterize the precise location, extent and features of the lesion (density, calcification, enhancement). These findings are helpful to generate a differential diagnosis. CT is also useful to demonstrate the precise extension of adjacent paranasal sinuses & nasal cavity, The evidence of bone erosion and intracranial extension which helps in pre treatment evaluation & post treatment follow up. To conclude CT scan can be considered as a cost effective, non invasive, reliable diagnostic tool for evaluation of proptosis. Early CT scan evaluation is required for prompt adequate medical therapy and for early intervention.

References

- [1]. Masud MZ, Babar TF, Iqbal A et al, Proptosis- etiology and demographic patterns. J. Coll. Physicians Surg. Pak. 2006; 16(1): 38-41
- [2]. Margo CE, Mulla ZD, Malignant tumors of the orbit. Ophthalmology 1998; 105: 185
- [3]. Johnson LN, Krohel GB, Yeon EB, Parnes SM, Sinus tumors invading the orbit. Ophthalmology 1984; 91(3): 209-17.
- [4]. KK Sabharwal, Al Chouhan, S Jain, CT evaluation of proptosis, IJRI, 2006 16:4:683-688
- [5]. Narula M. K. et al, Ultrasound evaluation of proptosis. IJRI 1994; 4: 203-206
- [6]. Alfred L. Weber, Laura Vitale Romo, Nelson R. Sabates, Pseudotumor of the orbit RCNA Jan 1999; 37:1: 151-166
- [7]. Murakami Y, Kanamoto T, Tuboi T et al, Evaluation of extraocular muscle enlargement in dysthyroid ophthalmopathy. Jpn J Ophthal. 2001; 45(6): 622-7
- [8]. Ozgen A, Alp MN, Ariyurek M, Tutuncu NB, CanI, Gunalp I, Quantitative CT of orbit in Graves disease. Br. J. Radiol. 1999; 72 (860): 757-6
- [9]. Clary RA, Cunningham MJ, Eavey RD, Orbital complications of acute sinusitis- Comparison of CT scan & surgical findings. Ann. Otol. Rhinol. Laryngol. 1992; 101 (7): 598-600
- [10]. Zahir Shah Mahsud, Suraya Bano, Diagnostic role of CT scan in proptosis in pediatric age group. JPMI 2004; 18: 3: 439-446.