

## Bochdaleks Hernia with Situs Solitus in Adult- A Case Report

Dr. Athui Gangmei<sup>1</sup>, Dr. Rothangpui<sup>2</sup>, Dr. Th. Rameshchandra<sup>3</sup>, Dr. Th. Geeta<sup>4</sup>.

<sup>1</sup>, Senior Resident, <sup>2</sup>, Asst. Professor, <sup>3</sup>, Senior Resident,

<sup>4</sup>, Senior Resident, Dept. of Medicine, JNIMS, Imphal, Manipur, India.

**Abstract:** Bochdaleks Hernia, a posterolateral Congenital Diaphragmatic Hernia is usually asymptomatic and usually manifest in adult. Patient are usually incidentally diagnosed when investigated and treated for other disease. Early diagnosis is essential to avoid subsequent morbidity and mortality related to it.

**Keywords:** Congenital diaphragmatic hernia, Bochdaleks hernia

### I. Introduction

Bochdaleks hernia is name after Bochdaleks in 1948. He described the foramen in the diaphragm and the associated hernia. The incidence of Congenital Diaphragmatic Hernia in infant is 1: 6000 live birth but entity is rare amongst adult .We have report the present cases and review other published literature.

### II. Case Report

We report a 50 years old male coming with history of shortness of breath occasionally, palpitation, chronic cough, inability to lie down supine. Symptoms aggravated after meal and relieved after passing flatus

#### On Clinical Examination

General condition was fair.

Chest examination reveals no abnormality on inspection.

Trachea shifted to the right.

Breath sound reduced on the left side

Vocal fermitus, Vocal resonance is reduced on the left side, BORBORYGMI could be heard on the left upper chest.

Normal Heart sound is heard in the right side just at the 4 inter costal space on the right lateral to right sternal border

Abdominal examination is insignificant.

Blood pressure is normal.

Sinus tachycardia with heart rate of 112/min, regular.

All blood parameters were normal.

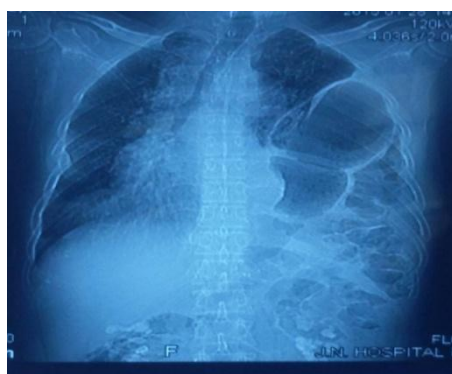**X-Ray Chest** shows trachea pull toward the right side.

Heart is seen in the right side. Normal right lung field and bowel loops seen in the left thoracic cavity

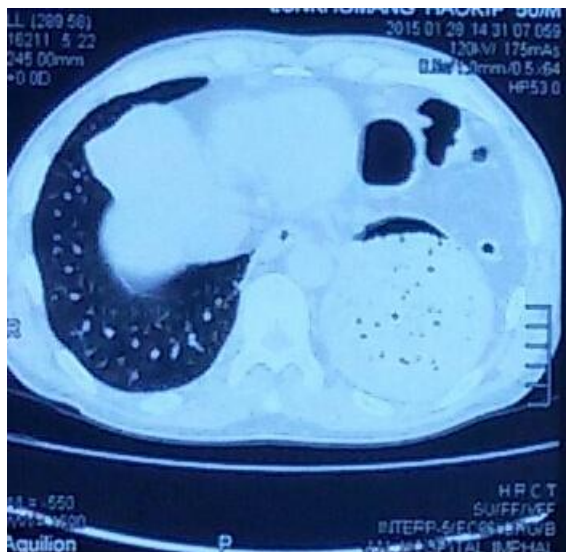
**Multislice Ct Chest** shows left hemidiaphragmatic herniation with hernia content of the stomach, small bowel, mesentery and transverse colon extending up to the level of the carini .

S/O of BOCHDALEKS Hernia. There is also passive atelectasis of left lung involve at lingual segment and lower lobe sparing superior lobe. Diaphragmatic hump is seen on the right side.

Examination findings, X-Ray Chest (fig 1) and CT scan (fig 2) confirm the diagnosis of Bochdaleks Hernia.



**Fig 1: Chest X-Ray showing Abdominal contents Occupying the left chest**



**Fig 2: CT scan showing bowel loops in the left thoracic cavity**

**Echocardiography** shows situs solitus, Dextropose of heart. Normal chamber dimension. Normal valve. Adequate ventricular functions

### **III. Discussions**

The true incidence of diaphragmatic hernia remains unknown and rare, There is also report of predominance on the right side and asymptomatic cases. Undiagnosed patient may never be identified as bochdaleks hernia .The left sided presentation in our patient is in accordance with the majority case reported in the literature.

### **IV. Conclusion**

Bocdaleks hernia is an uncommon variant of diaphragmatic hernia in adult and symptomatic cases are even rarer. Often the case present with chronic chest and abdominal symptoms with typical radiological findings. We wanted to emphasized the point that though rare, diaphragmatic hernia should be kept in mind while considering all the possibility of differential diagnosis of DEXTROPOSED HEART. Early diagnosis is essential so as to reduced the subsequent morbidity and mortality related to it.

### **Reference**

- [1]. Beyanta L, Lassucia I, Ramus F et al. Bochdaleks hernia in Adult; J Clinical Gastroentrol 2001; 32;155-57
- [2]. Bjelica Rodie B, Lyestine Pribu R, Petrovic S. Bogdanovic D; congenital poterolateral right diaphragmatic hernia- a cases repot. Med Pregl 2000, 53(11-12) ;613-6
- [3]. M.Abdullah et al, Congenital Diaphragmatic Hernia in a post par tum women. J Malasia ,Vol 58, No 1 MARCH 2003
- [4]. Mullin ME, Stein J, Saini SS et al: Prevalance of incidental Bochdaleks hernia in large adult population, AJR Am J Roentgenol 2001; 177;363-6
- [5]. Kirkland J A. Congenital posterolateral diaphragmatic hernia in adult. Br j Surg 1959;47;16-22.