

## Partial Duplication of Maxilla Associated With Tessier 3 and Incomplete Tessier 6 Cleft: A New Entity

Preeti Tiwari<sup>1</sup>, Jayanto Tapadar<sup>2</sup>

<sup>1</sup> B.D.S, M.D.S, Senior Resident, Trauma Centre, Institute of Medical Sciences, Banaras Hindu University, Varanasi, India

<sup>2</sup> M.B.B.S, M.S, M.Ch., Consultant Plastic surgeon, Samayan hospital, Varanasi, India

**Abstract:** Oblique facial clefts are extremely rare congenital deformities. Partial duplication of maxilla is a rare isolated anomaly. The concurrent existence of maxillary duplication and Tessier clefts has been described previously, specially the Tessier 7 clefts. In presented case, partial duplication of maxilla has occurred associated with Tessier 3 and incomplete Tessier 6 cleft along with cleft palate which might be the first case of its kind till now. Traditionally the correction of oblique facial cleft involved multiple local cheek and nasal flaps in Tessier 3. In presented case the use of a nasal flap was impossible due to significant defect of the lateral nose. An irregular Z plasty of cleft closure was therefore used in first stage. This was followed by extraction of supernumerary teeth present in the duplicated (accessory) maxilla. Resection of the duplicated maxilla and cleft palate closure was performed in second stage.

**Keywords:** Maxillary duplication, Accessory maxilla, Tessier no. 3 cleft, Rare cleft.

### I. Introduction

Oblique facial clefts are extremely rare congenital deformities. Their precise incidence in the population is unknown with reported incidence of 0.24% of all facial clefts [1-2]. Tessier described an anatomical classification system, in which number is assigned to each craniofacial cleft on the basis of its position relative to sagittal midline & the orbit [3]. The Tessier type 3 cleft extends from the philtrum of upper lip, through the wings of nostril & reaches the medial canthus of eye [4]. Maxillary jaw duplication, while rare as an isolated anomaly, can be associated with increased frequency in facial clefts, specially the Tessier 7 clefts [5]. However, to our knowledge, a combination of an isolated Tessier 3 clefts and an accessory maxilla has not been reported yet. Here we present the first case of a variant of Tessier 3 and Incomplete Tessier 6 cleft with accessory maxilla.

### II. Case Report

A 9 year old boy visited to our hospital with complaints of facial deformity since birth, difficulty in intake of food and upper jaw discomfort. The child was psychologically depressed due to his appearance. The child was born as the first child to unrelated healthy parents at term by spontaneous vaginal delivery. There was no history of any relevant abnormalities in the family. His medical history was unremarkable, and he appeared as a healthy young boy of normal intelligence & neurocognitive development.

On examination the child was found to have a left sided oblique cleft, corresponding to Tessier 3 cleft [Fig 1]. The cleft extended through the left side of upper lip, the alar groove and lower palpebra towards lateral half. Coloboma was present in the left lower eyelid corresponding to incomplete Tessier 6 cleft. Intra-orally cleft palate along with bony prominence extending from the left half of the alveolus of the maxilla was present [Fig 2]. The panoramic radiograph showed that these osseous structures contained supernumerary teeth [Fig 3]. There was no sign of other bone pathology or sinus involvement. Rest of systemic examination was normal without any other congenital anomalies. The child was taken for repair under general anaesthesia after fitness. The oblique cleft & cleft lip was repaired using an irregular Z-plasty at 9 years of age [Fig 4]. This was followed by extraction of supernumerary teeth present in the duplicated (accessory) maxilla as well as resection of the duplicated maxilla & cleft palate closure was performed at 10 years of age [Fig 5]. Further, autogenous bone grafting and orthodontic treatment is planned to coordinate maxillary & mandibular arches in preparation for orthognathic surgery.

### III. Discussion

Failure of fusion of the mesoderm during embryonic facial processes is explained as the cause of facial clefts, but lateral oro-ocular clefts cannot be explained by this theory. Presence of amniotic bands has been suggested as the cause of these clefts by some authors [1]. The concurrent existence of maxillary duplication and Tessier clefts has been described previously [3]. Most commonly maxillary duplication has been associated

with Tessier 7 clefts and an association between these two entities has been suggested in a recent report [6]. In presented case the partial duplication of maxilla was associated with Tessier 3 cleft and incomplete Tessier 6 cleft which according to best of knowledge might be the first of its kind. The possible differential diagnosis of bony prominences containing teeth includes supernumerary teeth, cystic teratoma, and jaw duplication. Multiple supernumerary teeth are also seen in developmental conditions such as cleft lip and palate [7]. In presented case differential diagnosis of multiple supernumerary teeth with Tessier 3 cleft and incomplete Tessier 6 cleft was excluded because in the presented case the teeth of the patient's were found within accessory osseous structures that extended from the maxillary tuberosities. This is in contrast to published cases of supernumerary teeth where teeth are known to have developed within the normal anatomic confines of the maxillary and mandibular bones [8-9]. Therefore, the condition in the present case report represents maxillary jawbone duplication. Early resection of the accessory jaws can damage the permanent tooth germs, therefore surgical resection is often deferred until the age of three or later in order to allow for development of the patient's tooth germs [5]. The permanent teeth are separated from the accessory jaw during surgical resection that can be associated with the loss of permanent tooth buds, and consequently, patients will need combined orthodontic and restorative treatment [10-11]. Traditionally the correction of oblique facial cleft involves multiple local cheek & nasal flaps [12-13]. In Tessier 3 cleft, as in presented case, the use of a nasal flap was impossible due to significant defect of the lateral nose. An irregular Z plasty of cleft closure was therefore used for primary reconstruction. The cheek scar deformation will require further correction. This was followed by extraction of supernumerary teeth present in the duplicated (accessory) maxilla. Resection of the duplicated maxilla and cleft palate closure was performed in second stage.

#### **IV. Conclusion**

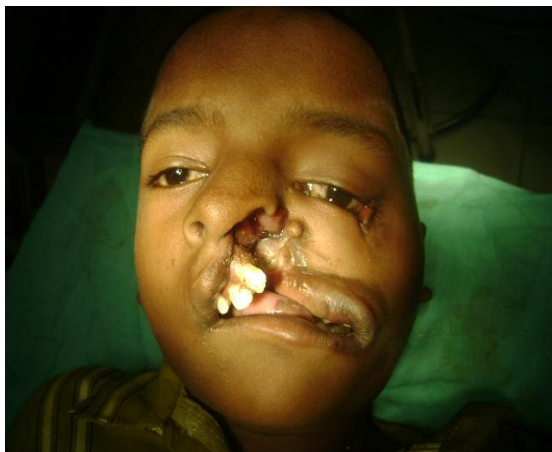The findings of this report demonstrate the wide variability in the pattern of presentation of oblique facial clefts. This new variant posed special challenges for its management by virtue of its uniqueness, late presentation and limited affordability of patient for standard treatment. There are no specific guidelines in literature for management of such cases. This makes all these cases worth for reporting in order to guide treating surgeons.

#### **Acknowledgement**

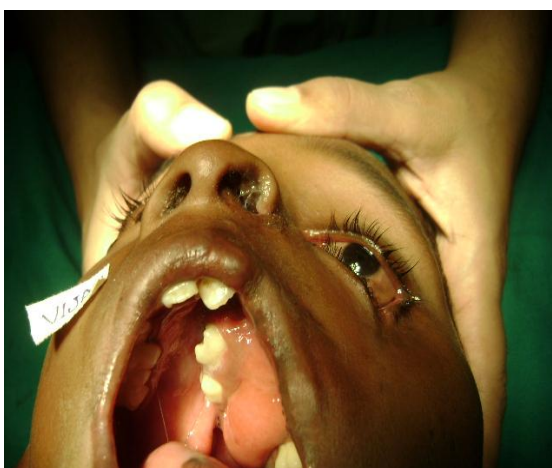There was no funding support. All authors have viewed and agreed to the submission.

#### **References**

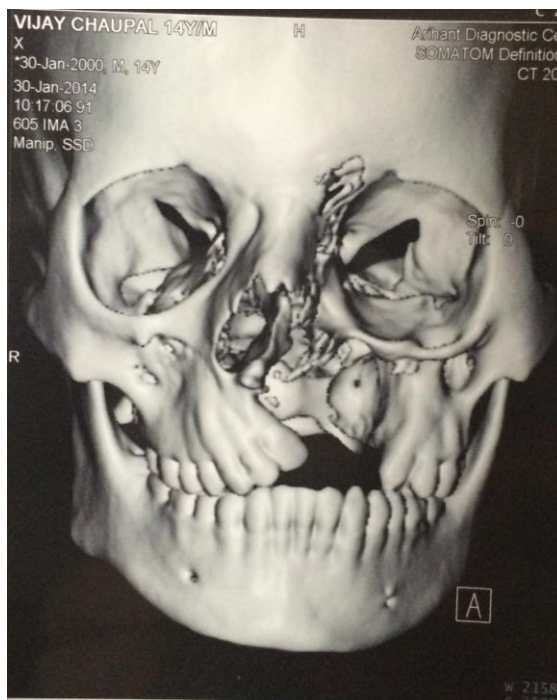
- [1]. Eppley BL, van Aalst JA, Robey A, Havlik RJ, Sadove AM: The spectrum of orofacial clefting. *Plast Reconstr Surg*, 115, 2005, e101ee114.
- [2]. Tapadar J, Tiwari P. Experience with Rare Oblique Facial Clefts: A case series. *International Journal Of Advances in Case reports*, 2(7), 2015, 474-476.
- [3]. Tessier P: Anatomical classification of facial, cranio-facial and latero-facial clefts. *J Maxillofac Surg* 4, 1976, 69e92.
- [4]. Gawrich E, Janiszewska-Olszowska J, Chojnacka H: Tessier type 3 oblique facial cleft with a contralateral complete cleft lip & palate. *Int J of oral Maxillofac surg*, 39, 2010, 1133-1136.
- [5]. Borzabadi-Farahani A, Yen SL, Yamashita DD, Sanchez-Lara PA: Bilateral maxillary duplication: case report and literature review. *Oral Surg Oral Med Oral Pathol Oral Radiol* 113, 2012a, e29ee32.
- [6]. Chauhan DS, Guruprasad Y: Bilateral Tessier's 7 cleft with maxillary duplication. *J Maxillofac Oral Surg*. <http://dx.doi.org/10.1007/s12663-012-0346-x>, 2012
- [7]. Vahid-Dastjerdi E, Borzabadi-Farahani A, Mahdian M, Amini N. Supernumerary teeth amongst Iranian orthodontic patients. A retrospective radiographic and clinical survey. *Acta OdontolScand*, 69, 2011, 125-128.
- [8]. Batra P, Duggal R, Parkash H. Non-syndromic multiple supernumerary teeth transmitted as an autosomal dominant trait. *J Oral Pathol Med*, 34, 2005, 621-625.
- [9]. Tapadar J, Tiwari P. Tessier 30 Facial Cleft Associated with Complete Duplication of Tongue: A Rare Entity. *International Journal Of Otolaryngology and Head & Neck Surgery*, 4, 2015, 169-172.
- [10]. Borzabadi-Farahani A, Gross J, Sanchez-Lara PA, Yen SL: An unusual accessory mandible and a sub-mucosal cleft palate: a case report and review of the literature. *Cleft Palate Craniofac J* 50, 2013, 369e375.
- [11]. Borzabadi-Farahani A: Orthodontic considerations in restorative management of hypodontia patients with endosseous implants. *J Oral Implantol* 38: 779e791, 2012b
- [12]. Woods RH, Varma S, David DJ: Tessier no. 7 cleft: a new subclassification and management protocol. *Plast Reconstr Surg*, 122, 2008, 898e905.
- [13]. Akoz T, Erdogan B, Gorgu M, Kutlay R, Dag F. Bilaterally involved Tessier No. 4 cleft: case report. *Cleft palate craniofac J* 33, 1996, 252-254.



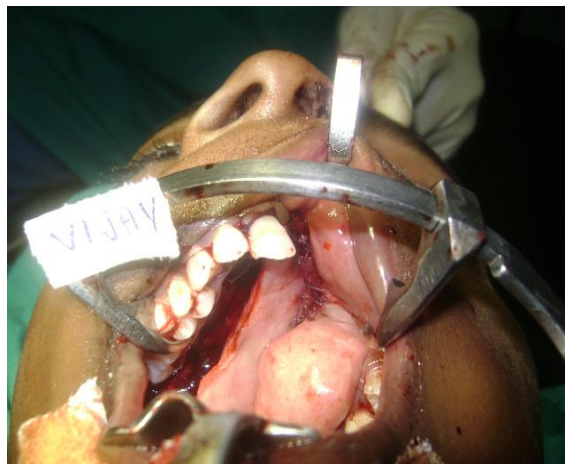
**Fig 1:** Preoperative extraoral photograph



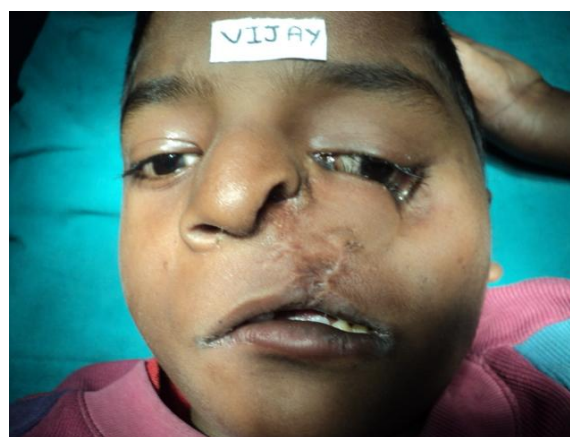**Fig 2:** Preoperative intraoral photograph



**Fig 3:** 3D reconstructive CT scan image.



**Fig 4:** Postoperative intraoral photograph



**Fig 5:** Postoperative op extraoral photograph.