

## Biometric Denture Space Enhanced With Balanced Occlusion: Remedy for Severely Resorbed Mandibular Ridges

Dr. Sagar C. Chaudhari. M.D.S<sup>a</sup>, Dr. S.P.Dange. M. D. S<sup>b</sup>,  
Dr. Smita A. Khalikar. M.D.S<sup>c</sup>.

<sup>a</sup> Post-graduate student , Dept of Prosthodontics, Govt. Dental College & Hospital, Aurangabad, Maharashtra University of Health Sciences, Maharashtra, India.

<sup>b</sup> Professor & Head, Dept of Prosthodontics, Govt. Dental College & Hospital, Aurangabad, Maharashtra University of Health Sciences, Maharashtra, India.

<sup>c</sup> Associate Professor, Dept of Prosthodontics, Govt. Dental College & Hospital, Aurangabad, Maharashtra University of Health Sciences, Maharashtra, India.

---

**Abstract:** One of the most commonly faced problems among long term denture wearers is the reduction in the denture foundation. Prosthetic Rehabilitation of a patient with severely resorbed ridge is the most challenging therapy. In order to have a favourable prognosis for the denture therapy, impression technique selected should be based on the present state of the basal tissue support. Also occlusal schemes can be modified to enhance stability of denture and hence overall function can be improved. However it is difficult to make records for programming Hanau articulator in order to achieve balanced occlusion in patient with resorbed ridges. In this case McCord's impression technique, concept of Neutral zone (NZ) and Balanced occlusal scheme being incorporated in an effort to achieve successful complete denture therapy.

**Keywords:** Neutral zone, Resorbed ridges, Impression technique, Balanced occlusion Stability.

---

### I. Introduction

The eruption of the teeth in the oral cavity is influenced by the forces exerted by tongue, cheeks and lips. These muscular forces collectively determine the final dental arch form and position of the tooth in the oral cavity. This muscular environment continues throughout life, even after teeth have been lost and greatly influences this potential space. It is one of the major determining factors for any prosthesis that will be placed in the oral cavity to replace these missing teeth. This potential space is known as neutral zone, which is bounded by the tongue medially, and the lips and cheeks laterally. Historically, different terminology has been loosely associated with this concept, including dead zone<sup>(1)</sup>, stable zone<sup>(2)</sup>, zone of minimal conflict<sup>(3)</sup>, zone of equilibrium<sup>(4)</sup>, zone of least interference<sup>(5)</sup>, biometric denture space<sup>(6)</sup>, denture space<sup>(7)</sup>, and potential denture space<sup>(8)</sup>. The success of any prosthesis depends on the proper position of the artificial teeth within the neutral zone. Weinberg<sup>(9)</sup> stated that buccal cusps and fossae of the posterior teeth should be directly over the crest of the ridge. Heartwell and Rahn<sup>(10)</sup> indicated that the posterior teeth should be positioned bucco-lingually on the residual alveolar ridge. Pound<sup>(11)</sup> stated that invariably arranging the teeth over the crest of the residual ridge condemned patients by accentuating facial deformity, provoking phonetic problems and making food manipulation difficult during deglutition. Robinson<sup>(12)</sup>, Payne<sup>(13)</sup>, Murray<sup>(14)</sup>, and Watt<sup>(15)</sup> are of the opinion that artificial teeth should be positioned where the natural teeth grew. Brill et al<sup>(2)</sup> stated that forces are developed as a result of the contraction of muscles during function. Beresin and Schiesser<sup>(16)</sup> have suggested that the denture teeth should be arranged in the neutral zone, where during function the forces of the tongue pressing outward are neutralized by the forces of cheek and lips pressing inward. Failure to recognize the importance of tooth position, flange form and contour often results in dentures which are unstable and unsatisfactory. Dental implants placed with neutral zone technique stabilize the denture fabricated over atrophic mandibular ridge. However, there may be certain medical, surgical or economical conditions when it is not possible to provide implants. In such complex cases the neutral zone impression technique is the only option left for the stabilization of the complete denture. It is not only a treatment of choice in atrophic mandible but also in patients with partial glossectomy, mandibular resections or motor nerve damage to the tongue which have led to either atypical movement or an unfavourable denture bearing area. This technique describes the fabrication of a complete denture using neutral zone impression technique.

### II. Case Report

A 75 year old male patient reported to Department of Prosthetic dentistry with the complaint of missing teeth and wanted the replacement of the same. On examination, it was found that both the upper and the lower arches were edentulous and lower arch severely resorbed . Patient also gave a history of denture wearing since

last 6 years. On examination of the existing dentures, it was found that there was attrition of teeth and drastically reduced vertical dimension so a treatment was planned which included fabricating the complete dentures with the help of neutral zone technique and the patient was explained about the same.

Primary impressions were made using irreversible hydrocolloid impression material. Custom trays fabricated on primary casts and border moulding carried out for maxillary arch. The secondary impression made using condensation silicone (light body) impression material. Mandibular impression made using McCord's technique. During recording of the secondary impression the patient was asked to open, swallow and speak so as to bring all the muscles into function.

The obtained impressions were poured with dental stone. One maxillary two mandibular record bases were fabricated, assessed and modified for stability, extension and comfort. One set of wax rim fabricated, maxillary rim oriented intraorally and facebow transfer carried out. Vertical dimension adjusted and Centric jaw relation made using mandibular wax rim and mounted. Then before making the neutral zone impression, the patient was made comfortable in an upright position with the head supported. The impression material (Green Impression Compound) was softened in a 65<sup>o</sup> C water bath. The softened compound was kneaded and a roll was formed according to the crest and was attached to the another mandibular record base. The attached roll of compound was reheated in the water bath and was carried into the patient's mouth. With the record base firmly seated, the patient was asked to perform a series of actions like swallowing, speaking, sucking, pursing lips, pronouncing vowels sipping water and slightly protruding the tongue several times which simulated physiological functioning. During function of the lips, cheeks, and the tongue, the forces exerted on the soft compound molds it into the shape of the neutral zone. After a few minutes when the compound has cooled, the record base with the compound rim is removed and placed in cool water bath. The height of the lower compound rim was then adjusted with a sharp knife on mounted cast.

The neutral zone impression so obtained was placed on the master model, locating grooves were cut on the master cast and was covered with a silicone putty index (condensation silicone,) around the impression on both the labial and lingual sides. The compound occlusal rim was then removed. The index would have preserved the space of the neutral zone. Using index lower wax rim is adjusted to recorded neutral zone. Teeth arrangement was done exactly. The position of the teeth was checked by placing the index together around the wax try-in.

Once the waxed up trial dentures were ready, they were checked in the patients mouth for aesthetics, phonetics and occlusion. Protrusive records were made in the mouth using bite registration material(Addition silicone,) for the purpose of capturing the position of condyles in their respective fossae. Using protrusive record horizontal condylar guidance was adjusted and lateral condylar angle calculated using Bennet angle formula ( $L = H/8 + 12$ ). Horizontal condylar guidance were found to be 5 degree and 6 degree on right and left side respectively. And calculated lateral condylar guidance were 12.625 degree and 12.75 degree respectively. In order to prevent the movement of mandibular denture base while doing balancing, mandibular record base was sealed to mandibular cast using modelling wax similarly as we do it before flasking. Balance occlusion was then obtained and checked intraorally. Later on, wax was removed from the labial and the lingual surfaces of the trial dentures leaving only minimal wax which could support the teeth that were placed. Patient was trained for making physiological movements such as tongue, cheek and lip movements. Once the patient was trained regarding the functional movements light body impression material was placed on the labial as well as lingual surfaces of the trial dentures, it was placed in the mouth and patient was asked to perform movements. This procedure was carried out for both the maxillary and mandibular arches. This recorded the polished surfaces of the denture according to the neutral zone and hence removes any soft tissue interferences if present and enhances stability of denture as well comfort of patient.

Once the try-in was satisfactory the dentures were processed and finished. Care was taken during finishing and polishing of the dentures so that the contours recorded previously were unaltered. During insertion the dentures are fully checked to eliminate any minor errors. The dentures provided the patient with improved facial appearance, stability and retention during function — as they have been constructed in harmony with their surroundings.

### **III. Discussion**

The ultimate goal of any prosthodontic treatment is to restore the form, function, and esthetics of the patient. Fish<sup>(17)</sup> pointed that out of the three surfaces of the denture the polished surface is bounded by the tongue and the cheeks. These are involved in normal physiologic movements such as speech, mastication, swallowing, smiling, and laughing. Hence, the fabrication of the denture must be in harmony with these functions. Because physiologically unacceptable denture is responsible for poor prosthesis stability and retention<sup>(2, 9, 18)</sup>, insufficient facial tissue support, less tongue space and compromised phonetics<sup>(11)</sup>.

Denture fabricated over a severely resorbed mandibular ridge by neutral zone impression technique will insure that the muscular forces aid in the retention and stabilization of the denture rather than dislodging the

denture during function. The dentures will also have other advantages such as reduced food lodgment, good esthetics due to facial support, proper positioning of the posterior teeth which allows sufficient tongue space.

Clinicians must identify and record the neuromuscular dynamics of the oral tissues and this should be applied in the construction of the definitive prosthesis that will exist within the stabilizing boundary conditions of the neutral zone area.

#### IV. Conclusion

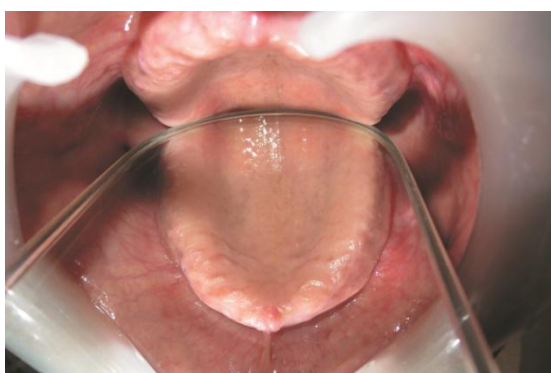
With advancement in dental material science and development of newer techniques in prosthodontics, the neutral zone impression technique may be incorporated into fabrication of any complete denture. Though this is indicated for patients with severe residual ridge resorption, the procedures discussed can also be used for full mouth rehabilitation of edentulous patients with dental implants.

#### References

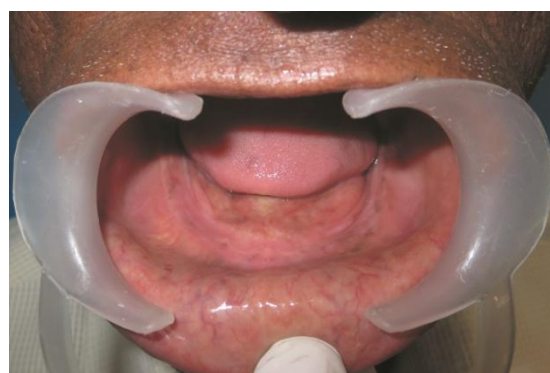- [1]. Fish E. Using the muscles to stabilize the full lower denture. *J Am Dent Assoc.* 1933;20(12):2163-9.
- [2]. Brill N, Tryde G, Cantor R. The dynamic nature of the lower denture space. *The Journal of Prosthetic Dentistry.* 1965;15(3):401-18.
- [3]. E.M. The polished surfaces. *Br Dent J.* 1961;111(5):407-11.
- [4]. Grant A, Johnson W. An introduction to removable denture prosthetics: C. Livingstone; 1983.
- [5]. Wright SM. The polished surface contour: a new approach. *Int J Prosthodont.* 1991;4(2):159-63.
- [6]. Watt D, MacGregor A. Designing complete dentures: John Wright; 1986.
- [7]. Schlosser R, Gehl D. Complete denture prosthesis. Philadelphia: WB Saunders; 1953.
- [8]. Roberts A. The effects of outline and form upon denture stability and retention. *Dent Clin North Am.* 1960;4:293-303.
- [9]. Weinberg L. Tooth position in relation to the denture base foundation. *The Journal of Prosthetic Dentistry.* 1958;8(3):398-405.
- [10]. Heartwell C, Rahn A. Syllabus of complete dentures: Lea & Febiger; 1974.
- [11]. Pound E. Lost--Fine arts in the fallacy of the ridges. *The Journal of Prosthetic Dentistry.* 1954;4(1):6-16.
- [12]. Robinson S. Physiological placement of artificial anterior teeth. *Journal of the Canadian Dental Association.* 1969;35(5):260.
- [13]. Payne A. Factors influencing the position of artificial upper anterior teeth. *The Journal of Prosthetic Dentistry.* 1971;26(1):26-32.
- [14]. Murray C. Re-establishing natural tooth position in the edentulous environment. *Australian Dental Journal.* 1978;23(5):415.
- [15]. Watt DM. Tooth positions on complete dentures. *J Dent.* 1978;6(2):147-60.
- [16]. Beresin VE, Schiesser FJ. The neutral zone in complete dentures. *J Prosthet Dent.* 1976;36(4):356-67.
- [17]. EW. F. An analysis of the stabilizing force in full denture construction. *Br Dent J.* 1947;83:137-42.
- [18]. Wright CR. Evaluation of the factors necessary to develop stability in mandibular dentures. *J Prosthet Dent.* 1966;16(3):414-30.

#### Legends

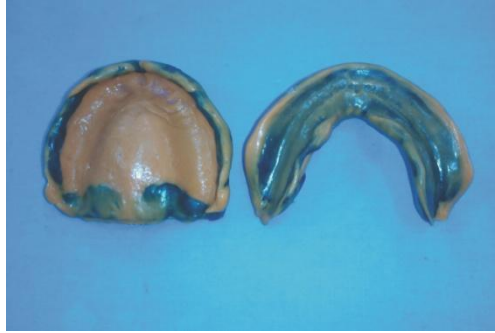- 1) Maxillary edentulous arch.
- 2) Mandibular edentulous arch.
- 3) Maxillary and Mandibular (McCord's technique) final impression.
- 4) Neutral zone recorded with green stick impression compound.
- 5) Teeth setting in neutral zone area.
- 6) Protrusive record made.
- 7) Try-in with balanced occlusion.
- 8) Second neutral zone record in condensation silicone light body.
- 9) Denture delivery- teeth in centric occlusion.
- 10) Denture delivery- teeth in balanced occlusion.



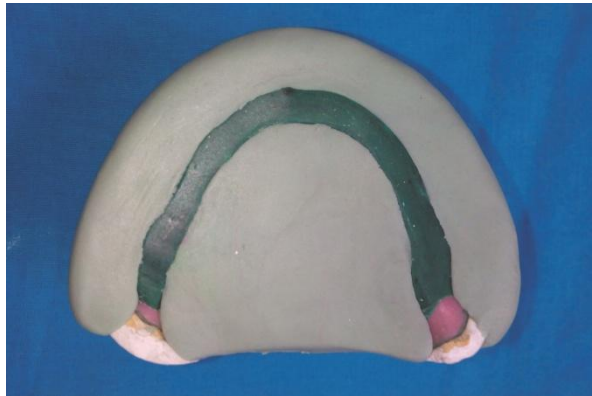**Fig 1.** Maxillary edentulous arch



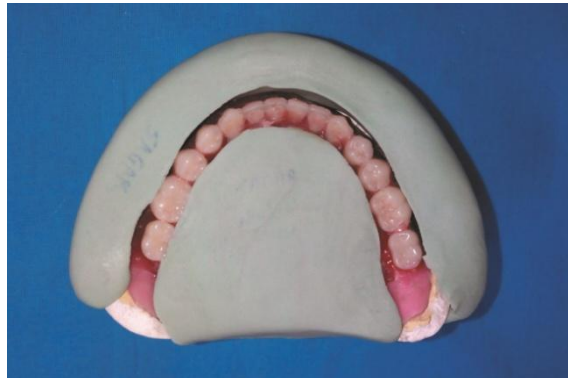**Fig. 2** Mandibular edentulous arch



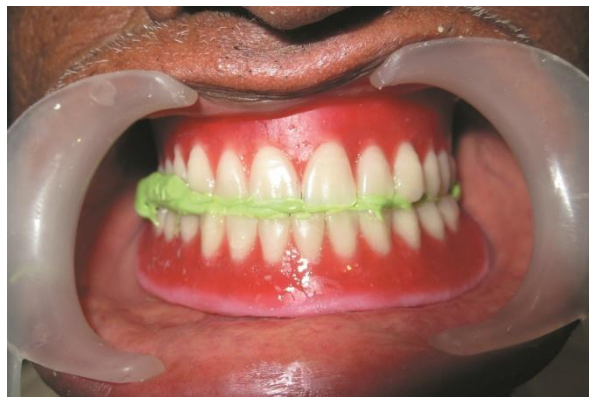**Fig. 3** Maxillary and Mandibular (McCord's technique) final impression



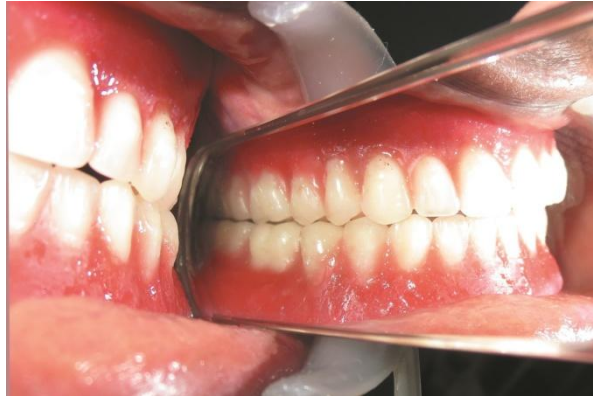**Fig. 4** Neutral zone recorded with green stick impression compound.



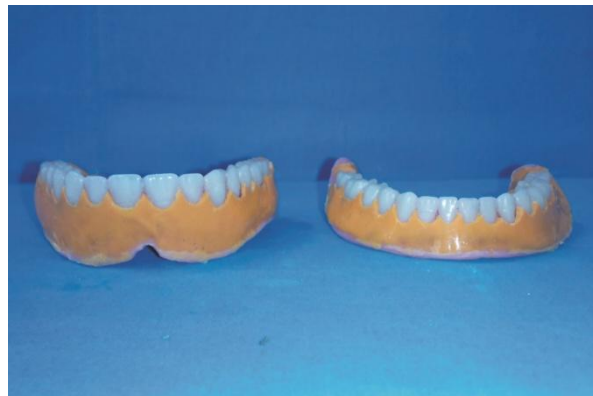**Fig. 5** Teeth setting in neutral zone area



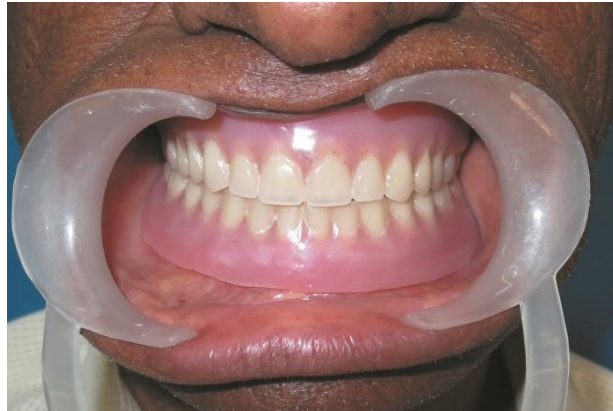
**Fig. 6** Protrusive record made.



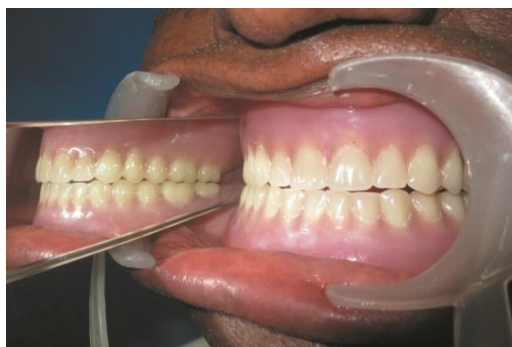**Fig.7.** Try-in with balanced occlusion



**Fig. 8** Second neutral zone record in condensation silicone light body



**Fig. 9** Denture delivery- teeth in centric occlusion



**Fig. 10** Denture delivery- teeth in balanced occlusion