

Unusual Homicidal Case of Firearm, Cut Throat and Stab Injury

Faisal Nasim Gilani¹, E.S.Goudar², Zarrin Afroz³

¹(Department of Forensic medicine & Toxicology, Al-Ameen Medical College, Bijapur, India)

²(Department of Forensic Medicine & Toxicology, Al –Ameen Medical College, Bijapur, India)

³(Department of Microbiology, Shri B.M.Patil Medical College, Bijapur, India)

Abstract: Dead body of a male aged about 30 years was brought for post mortem examination in the mortuary of Al-Ameen Medical College, Bijapur concerned to Rural Police Station, Crime No-192/2013, U/S-147,148 and 302 R/W-149 IPC. History over injury over the neck, back and chest was seen. Cause and Manner of death is a challenge while furnishing the final opinion. Detailed case along with Post mortem findings with Figures have been discussed in this case report.

Keywords: Homicide, Cut throat injury, stab injury, Firearm.

I. Introduction

Homicide means killing of a human being by another. The reason for Homicide can be Revenge, love failure, one sided love, property disputes, jealousy, infidelity, Enmity etc. There are many ways available to commit homicide .Invention of Fire was the greatest invention for the human civilisation but the invention of firearm has become curse to the world as it has become the most dreaded killing tool used by human being to kill themselves.¹ Mass production of advanced firearms and their availability in worldwide result in increased rate of death and injuries by these weapons².

Homicides are also done with the help of Sharp edged cutting weapons like Knives etc which can cause Stab wounds, Slash and Chop injuries, Cut throat wounds etc. Patients with Cut throat injury may present with airway compromise, aspiration, and acute blood loss with hypoxemia because of injury to airway and major vessels.³

Stab wounds are wounds produced from penetration using narrow instruments having pointed ends into the depth of the body .The typical feature of these wounds is a depth greater than their width or length⁴.

This paper describes a rare homicidal case of Firearm injury, Cut throat injury and multiple Stab injuries along with detailed description of post mortem finding and figures. Proper history, meticulous crime scene examination and carefully performed autopsy are vital in ascertaining the cause and manner of death in such cases⁵.

II. Case Summary

2.1 Case History – Information furnished by police was H/o Death due to firearm injury and Sharp cutting Weapon. The Case was concerned to Rural Police Station, Bijapur with Crime No-192/2013, U/S -302 IPC and 25, and 27 Arms Act.

2.2 Clothes and Articles: White T shirt with multiple tears on back of left side with a hole in the front. Blood stains at places.(Fig. 1)..White Sleeveless vest with multiple tears on back of left side with a hole in the front. Blood stains at places. (Fig. 2) Ash coloured cotton Trouser with blood stains at places .Blue coloured underwear with blood stains at places. Silver coloured bracelet over left wrist.

2.3 On Autopsy: The External Examination revealed the body of an adult male measuring 5 feet and 7 inches in length, moderately built and moderately nourished. Rigor Mortis present all over the body. Dried blood stains present all over the face, front of chest and back of chest. Nail beds were pale.

One Entry wound was present over front of left side of chest 3.5 cm medial to the left nipple showing Contused Abrasion, Inverted margins and Blood clots present.(Fig. 3)Cut Throat wound was present over upper part across the neck measuring 25cm x 4cm x cervical vertebrae deep. Underneath all soft tissues and neck structures from skin to trachea along with carotid artery and internal jugular veins were severed. Nearly all neck muscles like infrahyoid muscles, platysma. Sternomastoid muscles etc were clean cut. Trachea and oesophagus were transected. Blood clots were present. (Fig. 4, 5, 6)Multiple Stab wounds over back of outer aspect of left chest measuring 4.5 cms x 1.5 to 3.5cms x Muscle deep were seen. Ragged margins were seen. Blood clots were present. There was a bulge below these stab wounds near 7th to 8th intercostal space (Fig. 7, 8)

Internal examination- On opening the thoracic cavity, there was Extravasations of blood near 4th intercostal space. Laceration of Pleura, Pericardium, left lung, apex of heart and back of chest were seen. Thoracic Cavity was filled with approximately 2.5 litres of blood.

Organs of Cranial cavity and Abdominal cavity were intact and looked pale.(Fig.9,10,11)

III. Discussion

Easy access to Firearm (Mostly Country made) constitutes a true hazard in the community. Very few people survive incidents involving firearm injuries. Lack of legislative restrictions on firearms is often associated with higher fatality rates. Increased control over procurement and possession of firearm may help to limit fatalities. There should be strict ban on the illegal weapons in the market, so that homicidal firearm injury can be reduced⁶.

Stabbing is one of the most common methods of homicide in developing country like India and is of major importance in Forensic medicine. Stab wounds are most commonly homicidal which may result from any sort of Enmity, land dispute, family disputes, and quarrel with friends or snatching valuables etc. Homicidal stab wounds are usually more than 1 in number, all are quite deep, may be located anywhere on the body including self unapproachable parts. In homicidal cases, covering clothes usually bear corresponding cut marks or tears. A stab wound is deeper than its length and it is the depth of the injury that makes it so often fatal⁷.

Cut throat wound is usually homicidal and very rarely it is self inflicted or accidental. In India, one of the most frequent ways of committing homicide is by inflicting injury as with a sharp cutting or stabbing weapon.

IV. Cause Of Death

After over all considerations and lot of discussions, cause of death was opined as Haemorrhagic shock as a result of sustained injuries due to firearm and cut throat injury caused by hard and sharp edged object

V. Conclusion

All the injuries were Ante mortem in nature. Time since death was approximately 6-12 hrs prior to post mortem examination. This was the well thought out and well planned motive for the homicide as a result of old rivalry between two groups. It was a point of confusion for doctors for a long time that out of three injuries, which injury took place first.

. Fig 1:



Fig 2:

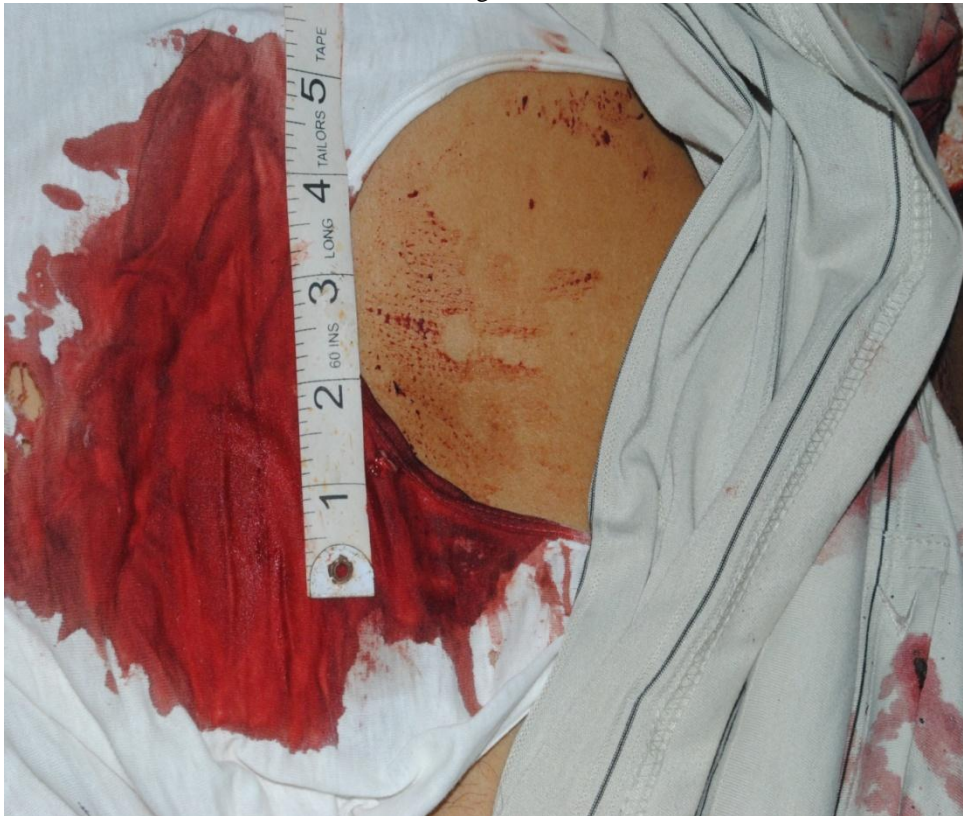

Fig 3:

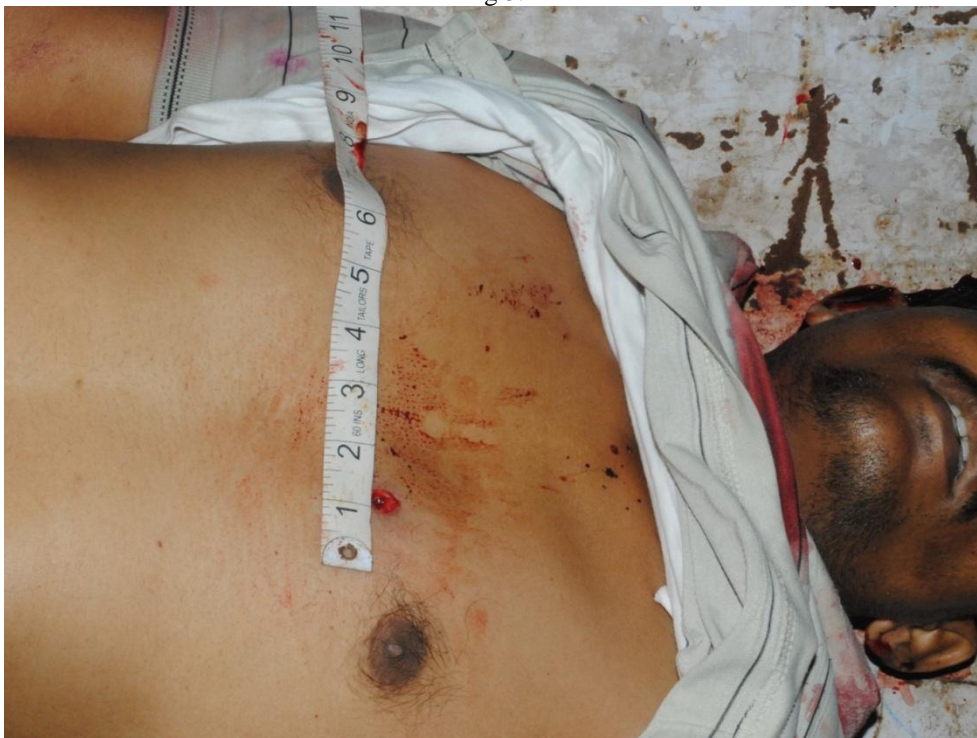

Fig 4:

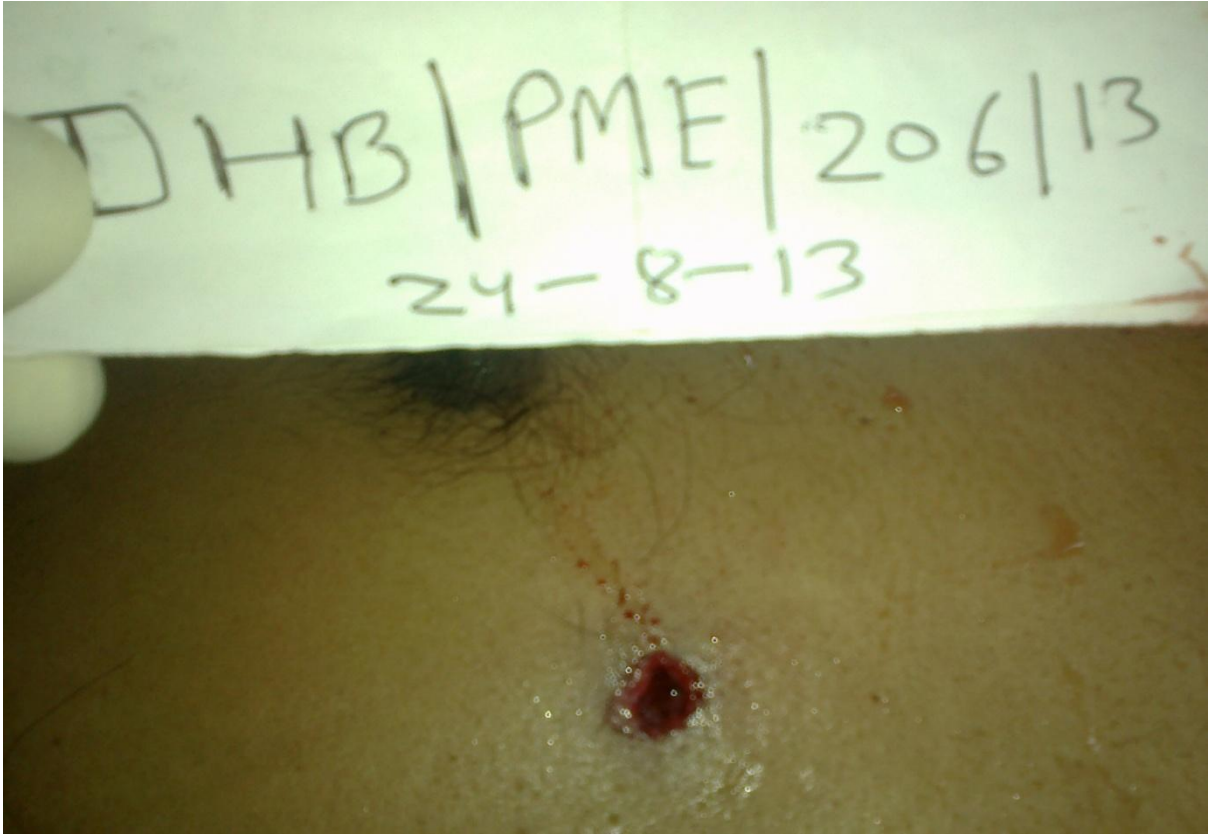


Fig 5



Fig. 6:

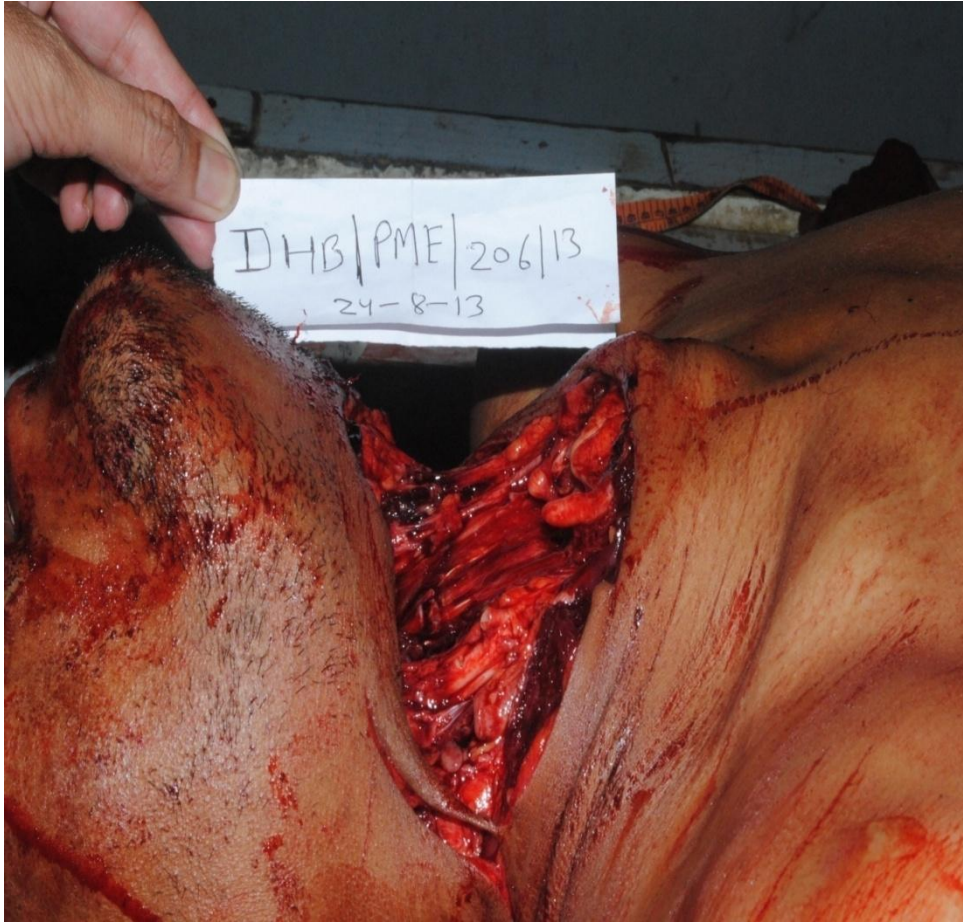

Fig. 7:

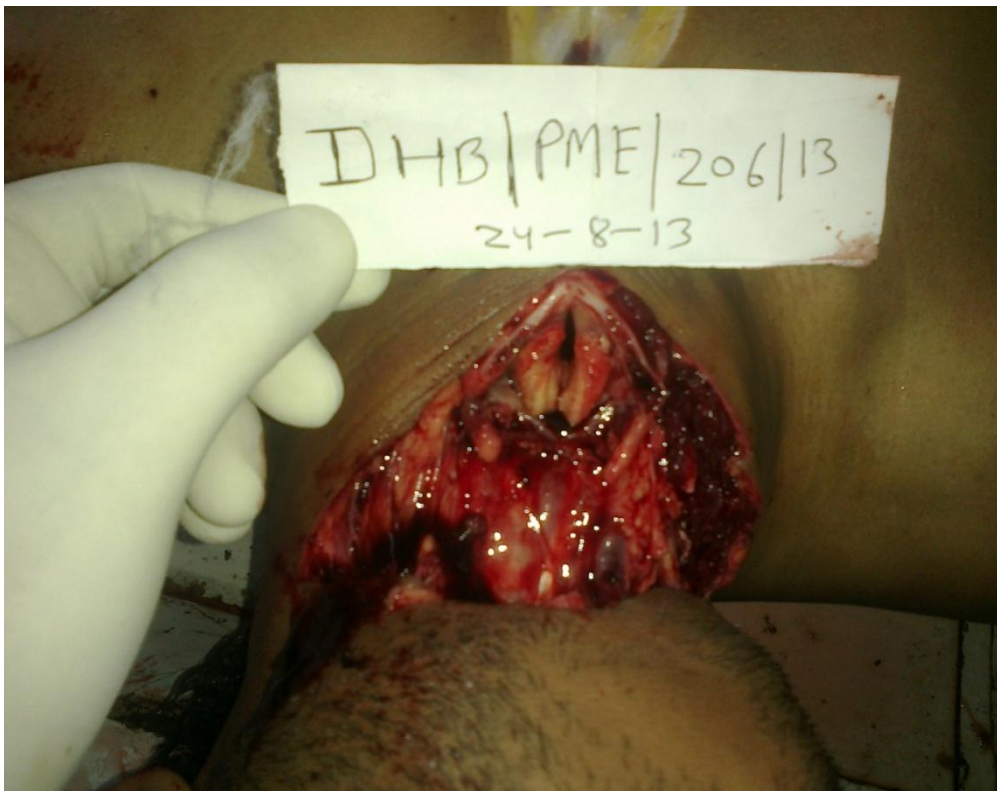

Fig. 8:

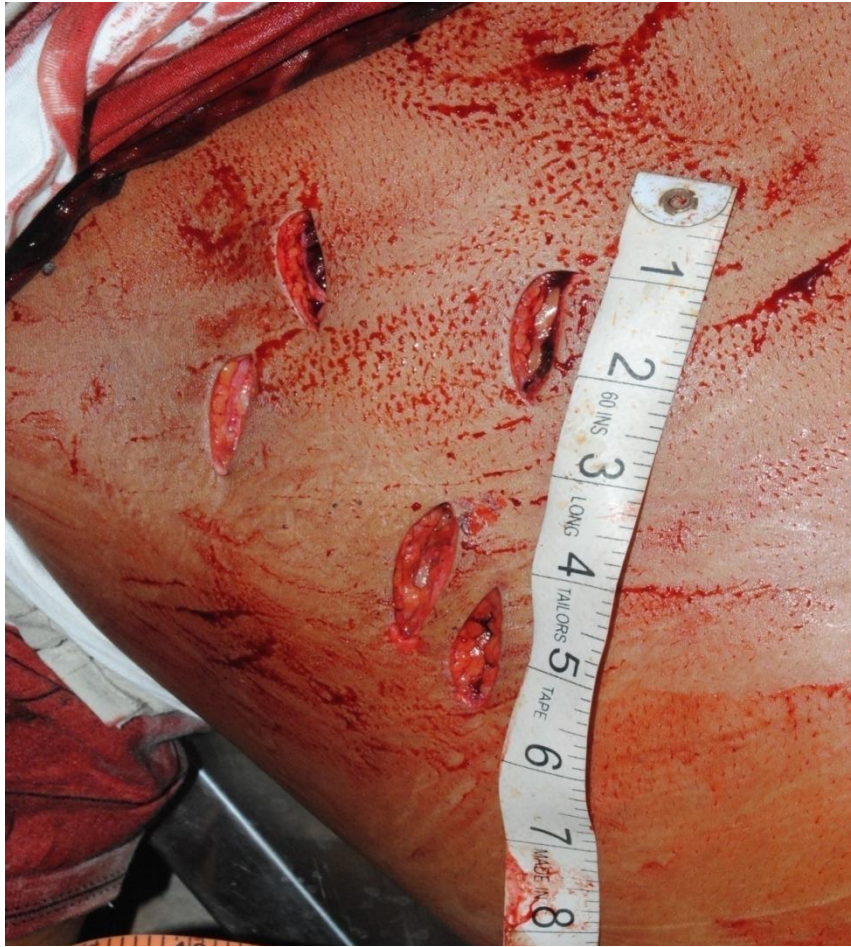

Fig. 9:

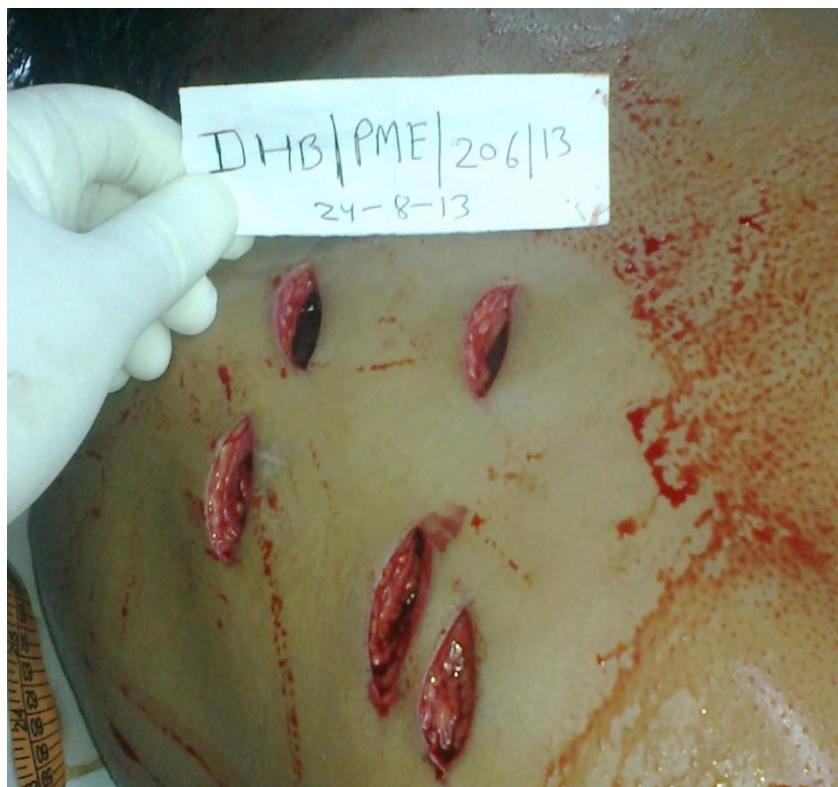

Fig. 10:

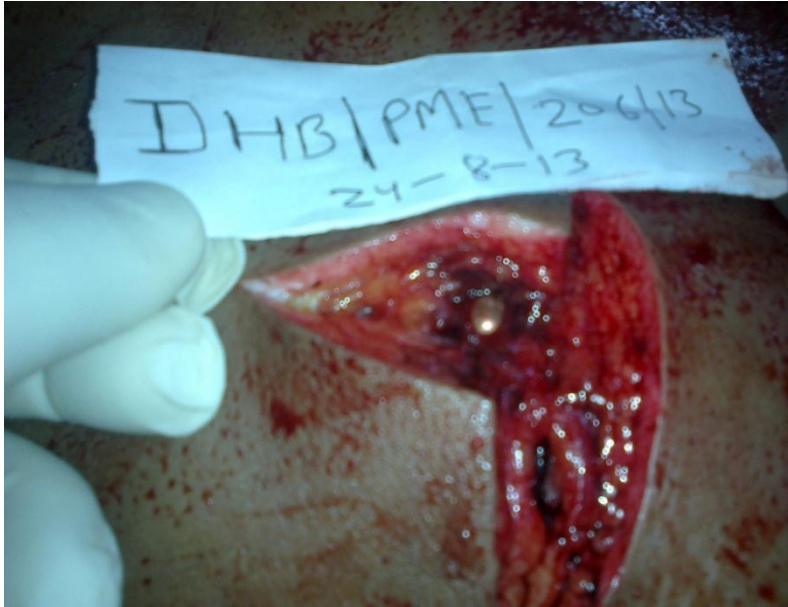

Fig. 11:

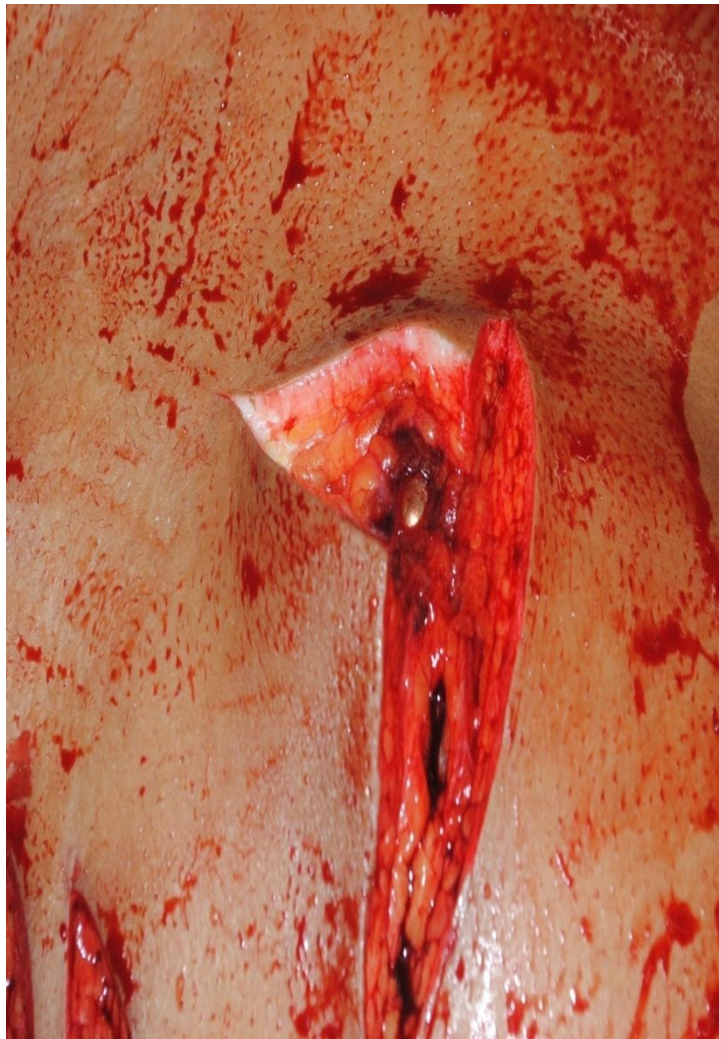
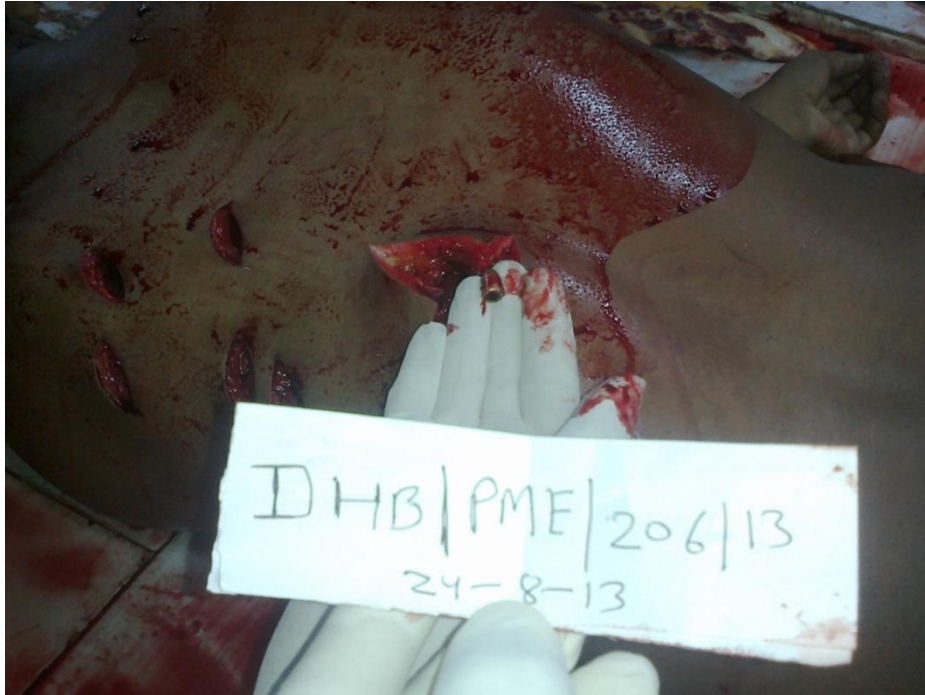
Fig. 12:



References

- [1] A.J.Patowary. STUDY OF PATTERN OF INJURIES IN HOMICIDAL FIREARM INJURY CASES. *JIAFM*.2005; 27(2):92-85.
- [2] Sithu Myint et al. A RETROSPECTIVE STUDY OF FATAL FIREARM INJURIES ON AUTOPSY CASES AT RAMATHIBODI HOSPITAL, BANGKOK. Proceedings of the 2nd ASEAN plus Three Graduate Research Congress (2nd AGRC), Bangkok. February 2014; 2:813-819.
- [3] Shreyas S. Joshi et al. Technicality of Managing Cut Throat Injury. *International Journal of Otolaryngology and Head & Neck Surgery*. January 2004; 2:11-12.
- [4] Muataz A. Al Qazzaz, Zaid Ali Abbas. Medico-Legal Study of Fatal Stab Wounds in Baghdad. *THE IRAQI POSTGRADUATE MEDICAL JOURNAL*. 2013; 12(1):104-110.
- [5] Ashish Jain et al. Fatal Cut-Throat Injury Labelled as Suicide after Meticulous Autopsy: Case Report. *J Indian Acad Forensic Med*. April-June 2014; 36(2):206-208.
- [6] Virendar Pal Singh, B.R. Sharma et al. MULTIPLE WOUNDS BY A SINGLE BULLET: ACASE REPORT. *JIAFM*.2004; 26(1):30-31.
- [7] Asma Begum, Md Rabiul Huq et al. A Case Report on Stab Injury. *Delta Med Col J*. Jan 2014;2(1):36-38.