

## Rare Presentations of Vitello Intestinal Duct (VID) In Two Infants, One in Ruptured Umbilical Cord Hernia and the Other As Y Shaped Prolapse From the Umbilicus

Dr.Sipala Siva kumar<sup>1</sup>, Dr.T.Vittal Mohan<sup>2</sup>

Dept. of Pediatric Surgery, S.V. Medical College, Tirupati, A.P., Dr. NTR University of Health Sciences, A.P., India.

**Abstract:** We are presenting 2 cases of vid one in 7 days old male baby and the other in 2 months old male baby, dealt with early surgery and discharged uneventfully on 7<sup>th</sup> post operative day.

**KeyWords:** prolapse, umbilical cord hernia, Vitello Intestinal Duct (VID)

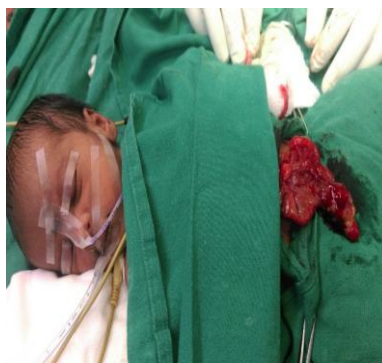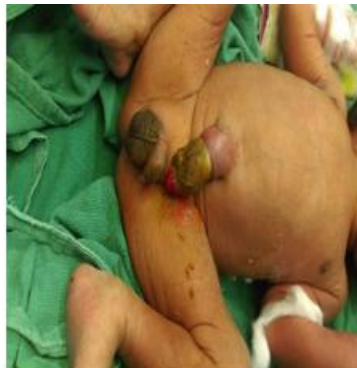### I. Introduction

Patent VID is an infrequent but well known anomaly. The incidence of patent VID is reported as 0.0053%. The developmental basis for these anomalies not recognized until the late 19<sup>th</sup> century. Surgery text book by Von Bergmann in 1904, clearly described the embryology responsible for persistence of VID as a fistula, sinus or cyst.

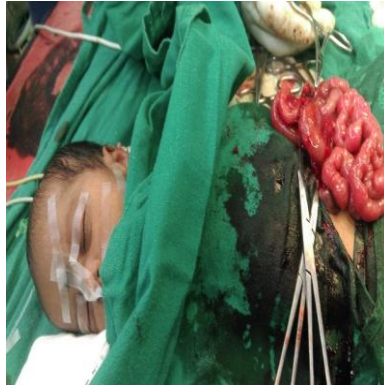
### II. Case Reports

**Case 1:** A 7day old full term, male baby weighing 2kg referred to our hospital from rural area, delivered by normal vaginal delivery with the complaints of passing stools from the abdomen since birth, the baby was born to non- consanguinous parents, there was no history of maternal diabetes. On examination there was a ruptured umbilical cord hernia with stools are passing from bowel opening with excoriation of skin. Planned surgery by circum- umbilical incision. Sac opened adhesions released. Patent VID resected, end to end anastomosis of ileum done using absorbable sutures of vicryl and associated malrotation is corrected by Ladd's procedure. Post operative period is uneventful and discharged on 7<sup>th</sup> day.

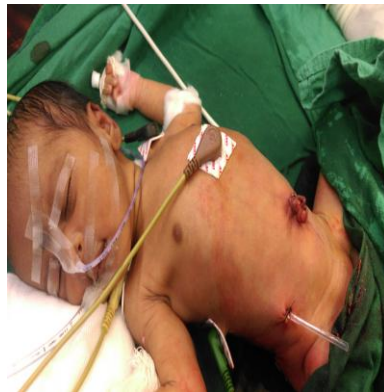#### VID in ruptured umbilical cord hernia and skin excoriation



VID at surgery



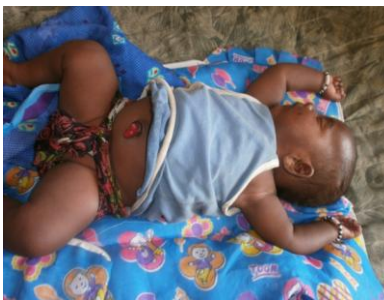**Anastomosis is completed**



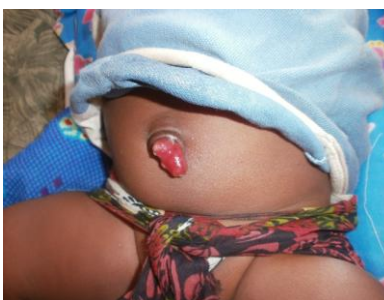**Umbilico Plasty**

**Case 2:**

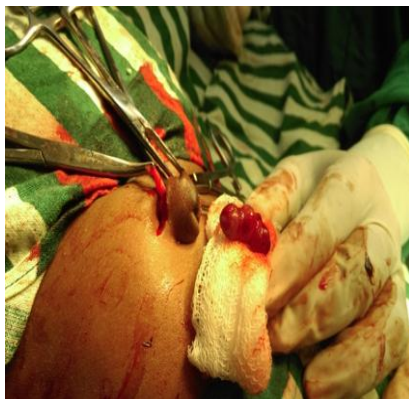A 2 months old, male baby delivered by normal vaginal delivery, weighing 3 kg referred to us with the complaints of passing stools from the Umbilical area since birth .antenatal scan was normal. On examination there was a Y shaped prolapse of VID and from one of its limb stools are passing. Early surgery by circum-umbilical incision done.Resection and end to end anastomosis of ileum done and discharged on 7<sup>th</sup> post operative day uneventfully.



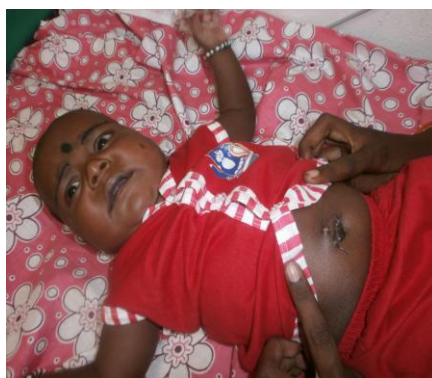**Prolapsed VID**



**Prolapsed VID**



**Excised VID by circum- umbilical incision**



**Umbilico Plasty**

### **III. Discussion**

Remnants of the VID or Omphalomesentric duct account for a wide variety of umbilical abnormalities. These include fistula, sinus, cysts and congenital bands. If the VID is patent from the terminal ileum to the umbilicus faecal discharge will be noted [1]. Incidence of patent VID is reported as 0.0053% [2]. Bowel prolapse with the patent VID is rare and prolapsing proximal as well as distal loop is extremely rare. Although Meckel's diverticulum is the most common VID anomaly, patent VID is the most common symptomatic embryological defect [3,4]. Patient may present with the anomaly itself or due to its complications like intestinal obstruction secondary to volvulus, Intussuseption and Adhesions. Complications of patent VID may be minor like feculent discharge leading to periumbilical skin excoriation. Cord tying in such neonates should be done with great care to avoid injury to the bowel. Resection and anastamisis following reduction of the prolapsed loop by a circum-umbilical incision and umilicoplasty is the treatment of choice.

### **IV. Conclusion**

Though patent VID is rare easily recognizable. Parents may be reassured that prompt and early surgical correction is simple and accurate.

### **References**

- [1]. Cilley RE. Disorders of the umbilicus. In: Grosfeld JL, O' Neill JA Jr, Coran AG, Fonkalsrud EW, (ed). Pediatric Surgery, 6<sup>th</sup> edn. St. Louis: Mosby Elsevier. 2006:ppl 143-56.
- [2]. Chang LS. Vitelline Duct ramanant appearing as a hemorrhagic umbilical mass. JAMA. 1982; 247:2812- [pub Med]
- [3]. Mohite PN, Bhatnagar AM, Hathila VM, Mistry JH. Patent vitellointestinal duct with prolapse of inverted loop of small intestine. J Med Case Rep. 2007;1:49.[PMC free article] [Pub Med]
- [4]. Ameh EA. Symptomatic vitelline anomalies in children. S Afr J Surg. 2005;84-5. [Pub Med].