

## A rare case of vertebral artery pseudoaneurysm- as an iatrogenic complication

Dr.Malla Uma Maheswara Rao<sup>1</sup>, Dr.B.Swetha<sup>2</sup>

1(Associate professor,Department of Radio-Diagnosis,Andhra Medical College,Visakhapatnam,India)

2(Post-Graduate in Department of Radio-Diagnosis,Andhra Medical College,Visakhapatnam,India)

---

**Abstract:** Pseudoaneurysms of vertebral artery are extremely rare and can be caused by penetrating or blunt trauma. Injuries of vertebral artery are far less common compared to other extracranial carotid arteries due to its deep location and anatomical protection in vertebra. We are reporting a case of a 30 year old male patient who developed a pseudoaneurysm of vertebral artery following anterior decompression surgery for cervical spinal stenosis.

**Key Words:** angiography, embolization, pseudoaneurysm, vertebral artery.

---

### I. Case Report

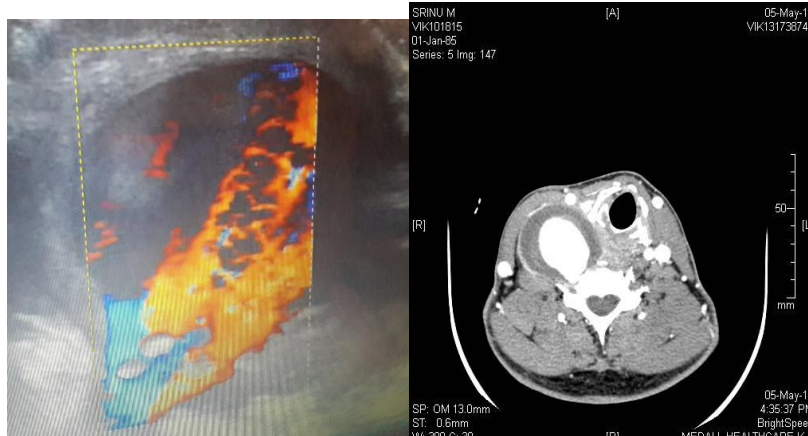
A 30 year old male presented with neurological symptoms like radiating pain, tingling and numbness of left upper limb for 3 years. These symptoms aggravated over a period of 3 months and there is decrease in muscle power and unable to move arm due to pain. Radiograph of cervical spine showed cervical spondylotic changes and narrowing of spinal canal. MR imaging of cervical spine revealed spinal canal, left neural foraminal stenosis and left C5 nerve root compression at C4-C5 intervertebral level due to central disc extrusion. Anterior decompression of the disc is done and cervical spine is stabilized with plate and screw fixation at C4-C5 level six months back. Surgery was uneventful, except for excessive bleeding which was stopped after applying pressure. Post-operatively, there was relief of neurological symptoms and patient was discharged. But after 3 months, patient complained of reeling sensation and swelling on right side of his neck which was gradually increasing in size with restricted neck movements.

Ultrasonography and Color Doppler evaluation revealed an anechoic swelling of 68x51x48 mm size on right side of neck deep to sternocleidomastoid muscle with peripheral echogenic rim and patent lumen. Lumen is showing "yin-yang sign" indicating bidirectional flow due to swirling of blood into lumen from vertebral artery - suggesting a diagnosis of pseudo aneurysm. "Fig 1". Patent Common carotid artery and internal jugular vein are seen separately but displaced anterolaterally and showed normal blood flow.

CT angiogram confirmed the diagnosis of the pseudoaneurysm, with mural thrombus and a patent lumen of 47x43x32mm size. Communication of pseudo aneurysm with right vertebral artery in foramen transversarium of C5 vertebra through 3mm wide neck is also well demonstrated "Fig 2". Distal to the pseudoaneurysm, right vertebral artery caliber is narrowed with normal contrast opacification. No evidence of vertebral artery dissection.

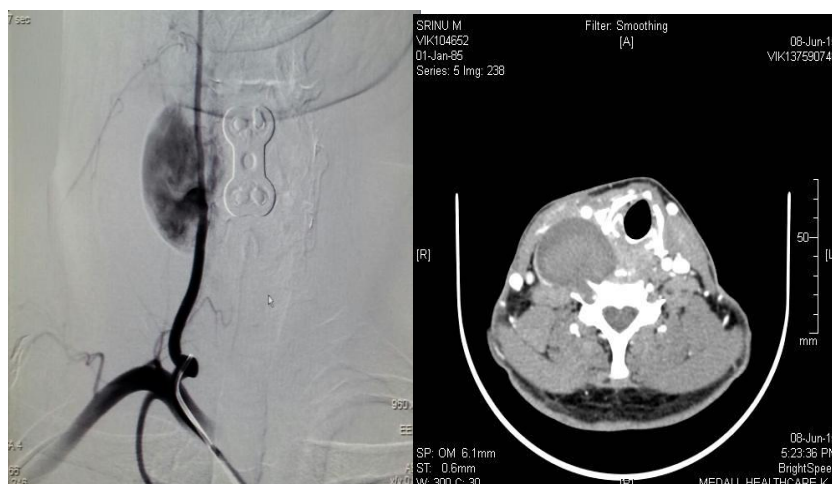
### II. Discussion

VA pseudo aneurysms may be iatrogenic or follow penetrating trauma of the neck; whereas the dissecting VA aneurysms may be caused by sudden violent rotational movement of the neck; both may be sources of significant morbidity and mortality (1). Due to delayed appearance of clinical manifestations, these injuries are often overlooked. Patients may present late with posterior circulation stroke symptoms like dizziness, syncope, vertigo, tinnitus, gait ataxia, hemi-sensory or motor deficit, dysarthria, visual disturbance and occipital or neck ache (2). Otherwise symptoms may also be due to local pressure by the aneurysm itself. In our patient the aneurysm was causing local swelling, restriction of neck movements and reeling sensation.



*Color dopplerUltrasound –Fig 1*

*Pre – operative CT-Fig 2*



*Angiogram-Fig 3*

*Post –operative CT-Fig 4*

Pseudoaneurysm formation resulting from trauma is far more common in carotid arteries than in vertebral arteries. This is because of the relatively unprotected location of the carotid arteries in the soft tissues of the neck. The vertebral arteries are protected, coursing within the bony canal formed by the transverse foramina of the cervical vertebrae. Among civilians in a study of arterial injuries, vertebral artery injuries constituted for only 0.5% of all arterial injuries [3]. According to Rich and Spencer vertebral artery injuries include 0.12% of 7,048 arterial trauma incidences in human body reviewed by them (4). However, Meier et al. reported 19.4% of vertebral artery lesions in their vascular cervical trauma patients (5).

On review of the literature, several etiological factors are found for development of aneurysms of the extracranial vertebral artery, such as: penetrating injuries from sharp objects or bullets (6) or due to blunt trauma to neck (7). In addition iatrogenic trauma such as a percutaneous jugular vein catheterization, subclavian arteriography and chiropractic manipulation of neck [8] also contributes for vertebral artery injury or pseudoaneurysm formation. In our patient, late development of pseudoaneurysm occurred following anterior cervical decompression for spinal canal stenosis.

Aneurysms of the vertebral artery are classified as acquired or congenital aneurysms. The acquired causes are already discussed. The congenital ones develop in patients who have disorders of the connective tissue (Ehler-Danlos syndrome and neurofibromatosis) (9). The diagnosis should be suspected depending on the type of lesion and symptoms present.

The pathophysiology of the pseudoaneurysm development is not known, but it is believed that the interruption of the intima of the artery is the major contributing factor. Intimal injury may lead to more devastating consequences due to the formation of a thrombus resulting in occlusion of artery or distal embolisation of thrombus to vertebrobasilar circulation. Occasionally, dissection may occur by the lesion of the intima which may lead to thromboembolism or vessel occlusion (10).

The most common finding is a cervical mass, may be pulsatile, with bruit on auscultation. It is also possible to find changes in the cranial nerves, cerebellar dysfunctions, Horner's syndrome and neurological symptoms with ischemic episodes. The patient may develop symptoms related to the compression of the adjacent structures or as a result of the mechanical effects of aneurysmal dilatation itself. In our case, the

symptoms were limited to the presence of a cervical mass causing reeling sensation and restricted neck movements.

Angiography is still the gold standard for the exact localization of the neck of the aneurysm and for planning of treatment“Fig 3”. Color Doppler imaging, spiral CT angiography and MR angiography are all very useful as noninvasive imaging modalities. Of these, Color Doppler imaging is most easily available and can diagnose aneurysms in the neck. Throughout the cardiac cycle, a swirling pattern of blood flow is seen and a "to-and-fro" spectral waveform is seen at the neck of pseudoaneurysm are classical signs (3). The neck of the aneurysm be localized by identifying the high velocity jet of blood flow.

Management of the VA injuries varies. The location of the injury influences the management. Immediate exploration is mandatory when patient presents with uncontrollable bleeding, expanding hematomas or airway compromise. But in situations where patient is stable but vascular injury is clinically suspected in the presence of penetrating neck wound, immediate angiography is mandatory(11). However, in symptomatic patients if routine angiography is not performed, lesion may be missed. On the other hand majority of asymptomatic patients can be managed safely without intervention(12).

The pseudo aneurysms have to be treated due to fear of rupture / hemorrhage and distal embolization as well as for local pressure effects. Two therapeutic options available for treating such aneurysms are the surgical ligation or percutaneous transfemoral approach to occlude the ipsilateral vertebral artery, provided there is adequate blood flow to the posterior circulation by the contralateral vertebral artery. . Others believe that pseudo aneurysms should be repaired and vertebral artery lumen should be preserved for patients whose angiography demonstrate inadequate collateral circulation(13).

The pseudoaneurysms of the extra cranial vertebral artery are unusual and the review of literature showed 18 patients with pseudo aneurysm of this artery who were treated by surgery or embolization(14). The ligation of the vertebral artery may produce serious complications such as ischemia of the vertebrobasilar system (6),(9) with an incidence of 8% SI. The incidence of brainstem ischemia following unilateral VA ligation is 3.1% for the left and 1.8% for the right. In the largest series of VA trauma, Reid and Weige et al. suggested that surgical exploration with proximal and distal ligation should be the procedure of choice. Similarly Meises et al claimed that surgical ligation could be employed if contralateral VA is normal. The direct surgical approach to the vertebral artery is difficult and results in more complications due to extensive periarterial plexus, collateral circulation, anatomical site and the risk of ischemic attack and infarction of the vertebrobasilar system during its manipulation(15).

In case of aneurysms arising from the distal vertebral artery near the foramen magnum, surgical access is generally difficult and hence a transfemoral approach, is the preferred mode of treatment. Balloon occlusive devices or intraluminal coils can be deployed to occlude the artery. Alterations in the neurological status of the patient may be observed when the vertebral artery is temporarily occluded using the balloon. Occlusion of the artery proximal as well as distal to the neck of the aneurysm is desirable to avoid the risk of refilling of the aneurysm from the contralateral side. Interventional endovascular techniques have great advantages over surgical procedures as they can be done under local anesthesia and reduces the morbidity of surgery and hospital stay(16).

With the advances in the radiological interventions more and more patients are being treated by embolisation of the aneurysm or occlusion of the vertebral artery by detachable balloon. Our patient declined radiological intervention, which we believe should be the treatment of choice. As the aneurysm in our patient originated from the V2 segment of the VA, dissection of its neck was impossible. So the vertebral artery was ligated at VI and V3 segments above and below the pseudo aneurysm after checking the refilling of posterior circulation from contralateral side “Fig 4”. Patient remained asymptomatic for Twelve weeks following surgical ligation of VA.

### **III. Conclusions**

In ventral approaches to the cervical spine, precise preoperative planning and a detailed knowledge of the surgical anatomy are mandatory. In cases of injury to the vertebral arteries, direct surgical repair is most appropriate to prevent complications arising from fistulas, late-onset hemorrhages, pseudo aneurysms, thrombosis, and emboli. Alternatively, endovascular techniques or even clipping or ligation of the affected artery should be considered.

### **References**

- [1]. Halbatch VV, Fligashida RT, Dowd CF. et al. Endovascular treatment of vertebral artery dissections and pseudoaneurysms. *J Neuro. Surg.*, 1993;79: 183-91.
- [2]. Molnar RG, Naslund TC. Vertebral artery surgery. *Surg. Clin. North. Am.*, 1998; 78: 901 -13.
- [3]. Wilkinson DL, Polak JF, Grassi CJ, Whittemore AD and O'n Leary DH. Pseudoaneurysm of the vertebral artery: appearance on Colour Flow Doppler Sonography. *AJR* 1988; 151:1051-1052
- [4]. Rich NM, Spencer FC. Carotid and vertebral artery injuries, In Rich NM, Spence FC. *Vascular Trauma*. Philadelphia: WB Saunders, 1978;260-286.

- [5]. Meier DE, Brink BE, Fry WJ. Vertebral artery trauma. Arch Surg 1981 ;116:236-239
- [6]. Ross DA, Olsen WL, Halbach V, Rosegay H, Pitts LH. Cervical root compression by a traumatic pseudoaneurysm of the vertebral artery. Neurosurgery 1988;22:414-417
- [7]. McLean JM, Wright RM, Henderson JP, Lister JR. Vertebral artery rupture associated with closed head injury. J Neurosurg 1985;62:135-138.
- [8]. Aoki H, Mizobe T, Nozuchi S, Hatanaka T and Tanaka Y. Vertebral artery pseudoaneurysm: a rare complication of internal jugular vein catheterization. Anesth Analg 1992; 75: 296-298
- [9]. Sherman DG, Hart RG, Easton JD. Abrupt changes in head position and cerebral infarction. Stroke 1981; 12:2-6.
- [10]. Willis BK, Greiner F, Orrison WW, Benzei EC: The incidence of vertebral artery injury after midcervical spine fracture or subluxation. Neurosurgery 1994;34:435-441.
- [11]. Jeffery P, Immelman E, Beningfield S. A review of (he management of vertebral artery injury. Eirr. J. Vase Endovasc Surg., 1995;10: 391-93.
- [12]. Webb TH, Gewertz BL Penetrating and blunt vertebral artery trauma In: Emst CB, Stanely IS, (eds.). Current therapy in vascular Surgery. St Louis: Mosby, 1995:pp. 604 -8.
- [13]. Islamogin F, Posacioglu H, Memis A, et al. Endovascular Intracatheter occlusion for traumatic vertebral artery pseudoaneurysm. Eur - J, Endovase. Surg., 2000; 20:576 - 78.
- [14]. de los Reyes RA, Moser FG, Sachs DP, Boehem FH. Direct Repair of an extracranial vertebral artery pseudoaneurysm: case report and review of the literature. Neurosurgery 1990;28:528-533.
- [15]. Blickenstaff KL, Weaver FA, Yellin AE, Stain SC, Finck E. Trends in the management of traumatic vertebral artery injuries. Am J Surg 1989;158:101-106.
- [16]. Higashida RT, Halbach VV, Tsai FY, Norman D, Pribram HF, Mehringer CM, Hieshima GB. Interventional neurovascular treatment of traumatic carotid and vertebral artery lesions: results in 234 cases. AIR 1989; 153:577-582