

Cogan- Reese Syndrome :A Variant Of Iridocorneal Endothelial Syndrome-A Case Report

Dr.Anitha S Maiya¹,Dr.Reagan Madan²,Dr Basavaraj zalaki³,Dr Pavan Kumar Reddy.D⁴

¹Assistant professor,Department of Ophthalmology,Adichunchanagiri Institute of Medical Sciences, BG Nagar,India.

²Junior Resident,Department of Ophthalmology,Adichunchanagiri Institute of Medical Sciences,BG Nagar,India.

³Junior Resident,Department of Ophthalmology,Adichunchanagiri Institute of Medical Sciences,BG Nagar,India.

⁴Junior Resident,Department of Ophthalmology,Adichunchanagiri Institute of Medical Sciences,BG Nagar,India.

Abstract: Cogan Reese syndrome belongs to a group of ocular disorders known as Iridocorneal Endothelial Syndrome(ICE).It is a unique ophthalmic disorder characterized by the presence of an abnormal corneal endothelium which leads to varying degrees of corneal edema,progressive iris atrophy and secondary angle closure glaucoma without pupillary block.We report a 32year old male patient who was diagnosed to have the Cogan-Reese variant of ICE Syndrome based on clinical findings.

I. Introduction

ICE syndrome encompasses a group of disorders characterized by a primary corneal endothelial abnormality¹. ICE syndrome is an acquired,unilateral disorder which typically manifests in young adults and predominantly affects women.

ICE syndrome encompasses three clinical variants:

- 1.Chandler's Syndrome
- 2.Essential/Progressive iris atrophy
- 3.Iris neavus/Cogan- Reese syndrome²

Table 1. Clinical Features Of Ice Syndrome

Progressive Iris Atrophy	Chandler's Syndrome	Cogan- Reese Syndrome
Iris Features Such As Marked Corectopia, Atrophy, And Hole Formation.	Changes In Iris Are Mild To Absent, While Corneal Oedema, Often At Normal Intraocular Pressure Is Typical.	Nodular, Pigmented Lesions Of The Iris Are Hallmark ,And May Be Seen With The Entire Spectrum Of Corneal And Other Iris Defects.

The underlying mechanism is the presence of abnormal endothelial cells which secrete an abnormal basement membrane which grows over the iris and trabecular meshwork.Contraction of this membrane leads to the structural changes in the iris,iridotrabecular synechiae and secondary glaucoma^{3,4}.

The exact etiology of ICE Syndrome is still unclear.However a viral etiology has been proposed for this corneal endotheliopathy.Herpes simplex viral DNAhas been detected by polymerase chain reaction in the corneal specimens of the patients with the ICE syndrome.

II. Case Report

A 32 year old male patient presented to our clinic with complaints of pain and discomfort in his right eye of 2 weeks duration.

A comprehensive ophthalmic work revealed an uncorrected visual acuity of 6/6,N/6 in both eyes and IOP of 14mmhg in both eyes using Goldmann applanation tonometer.Slit lamp examination revealed a clear cornea, 5mm vertically oval pupil with ectropion uveae, 3 broad areas on the iris at 3, 6o clock and 12 o clock positions showing numerous dark pigmented nodules in the iris stroma. (Fig. 1). Examination of the left eye was unremarkable. (Fig. 2)

Gonioscopy showed broad high peripheral anterior synechiae extending about 2 clock hours in the superior , inferior and nasal quadrants corresponding to the areas of the iris showing the nodular changes.(Fig. 3)

Posterior segment evaluation revealed a normal optic nerve and retina. The patient has been started on the ocular lubricants and is being kept on close follow up to monitor the occurrence of glaucoma and/or corneal decompensation.

Fig 1: Slit lamp photograph of the right eye patient showing a vertical oval distorted pupil with multiple pedunculated iris nodules in the superior, inferior and the nasal quadrants of the iris.

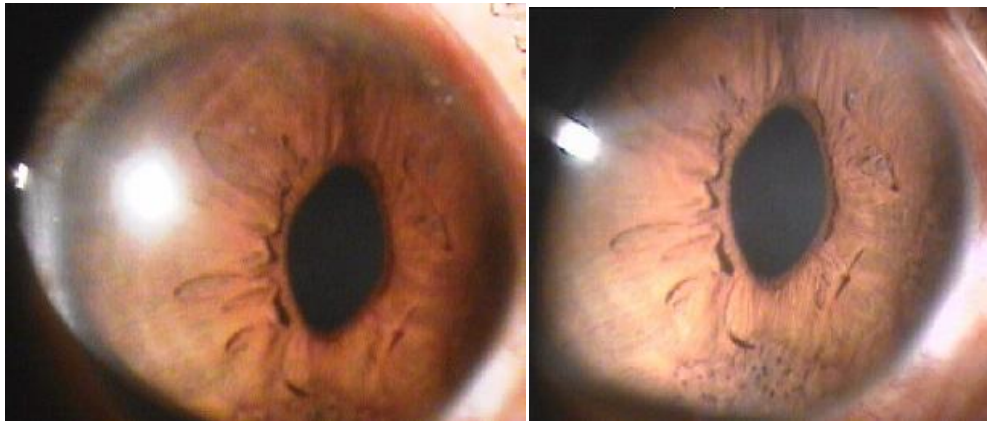


Fig 3: Slit lamp photograph of the normal left eye

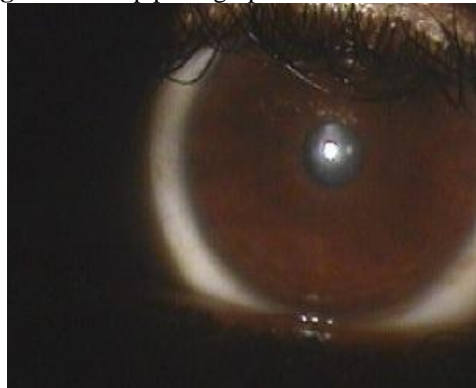


Fig 3: Gonioscopic photograph of the right eye of the patient showing a broad peripheral anterior synechia in the inferior quadrant.



III. Discussion

Cogan Reese syndrome is less common among the three variants of ICE syndrome.

The differential diagnosis of ICE syndrome includes corneal conditions like posterior polymorphous dystrophy and Fuch's endothelial dystrophy, anterior segment dysgenesis syndrome such as Rieger's syndrome and aniridia and miscellaneous conditions such as anterior uveitis with nodules and neurofibromatosis (Lisch

nodules). However most of these conditions are bilateral and hence when the findings are unilateral, it should raise the possibility of ICE syndrome⁵.

The diagnosis of ICE syndrome may be difficult in the early stages due to subtle changes in the iris and cornea

Management of patients with ICE syndrome involves the treatment for corneal oedema, glaucoma or both which may develop during the course of the disease. The unpredictable course of the disease warrants regular monitoring of these patients.

The prevalence of glaucoma in patients of ICE syndrome is reported to be around 82%³. Glaucoma is initially treated medically with aqueous suppressants, however a high percentage of patients require surgical intervention in the form of trabeculectomy or glaucoma drainage devices.

Corneal oedema may be treated by hypertonic saline solutions and soft bandage contact lenses. Concurrent reduction of IOP also results in the improvement of corneal edema. However eventually some of these patients may require penetrating keratoplasty.

Prognosis for patients with ICE syndrome depends upon the development of complications (corneal edema and glaucoma). Patients with subtle forms of the disease have a better prognosis, while those with the aggressive disease tend to suffer extensive vision loss from severe corneal edema and advanced glaucoma.

In the future, development of therapies targeting the specific disease process is required. Treatment with the antiviral agents may be helpful if the viral cause can conclusively be proven.

References

- [1]. Eagle RC, Font RL, Yanoff M, et al. Proliferative endotheliopathy with iris abnormalities. The iridocorneal endothelial syndrome. *Arch Ophthalmol.* 1979;97(11):2104-2111
- [2]. Shields MB. Progressive essential iris atrophy, Chandler's syndrome, and the iris nevus (Cogan-Reese) syndrome: A spectrum of disease. *Surv Ophthalmol.* 1979;24:3
- [3]. Hirst LW, Quigley HA, Stark W, et al. Specular microscopy of iridocorneal endothelial syndrome. *AmJ Ophthalmol* 1980;89:11-21. Cambell DG, Shields MB, Smith TR. The corneal endothelium and the spectrum of essential iris atrophy. *AmJ Ophthalmol* 1978;86:317-324.
- [4]. Alvarado JA, Underwood JL, Green WR et al. Detection of herpes simplex viral DNA in the iridocorneal endothelial syndrome. *Arch Ophthalmol.* 1994;112:1601-1609