

## Pseudo Ventricular Fibrillation: A Case Report

Dr. Rahul Rathee<sup>1</sup>

<sup>1</sup>(Department of General Medicine, B.P.S. Govt. Medical College for Women,  
Khanpur Kalan, Distt. Sonapat, Haryana, India)

**Abstract:** Patients who are misdiagnosed with ventricular fibrillation because of electrocardiographic artifact may be subjected to unnecessary procedures. Physicians should include artifact in their differential diagnosis of ventricular fibrillation to minimize unneeded procedures and interventions.

### I. Introduction

Arrhythmias may be documented in patients with cardiac or serious medical disorders admitted to intensive cardiac care units (ICCU) equipped with continuous cardiac monitoring<sup>[1]</sup>. Ventricular tachycardia and ventricular fibrillation (VF) are of particular prognostic significance because of their associated risk of sudden cardiac death. However, artifacts on the electrocardiographic (ECG) strips recorded routinely in the ICCU can mimic VF and may lead to unnecessary and potentially risky therapeutic interventions.

### II. Case Presentation

A 52-year-old male patient was admitted in the intensive cardiac care unit (ICCU) with an acute anterior wall myocardial infarction. Tenecteplase was administered with clinical and electrocardiographic evidence of reperfusion. On the fourth day of admission, the following ECG strip (figure 1) was recorded on the monitor after the alarm went off. The patient had no clinical symptoms and the episode was documented as "transient asymptomatic ventricular fibrillation" by the resident on duty at that particular time. The patient was presented to the consultant on evening round on the same day.

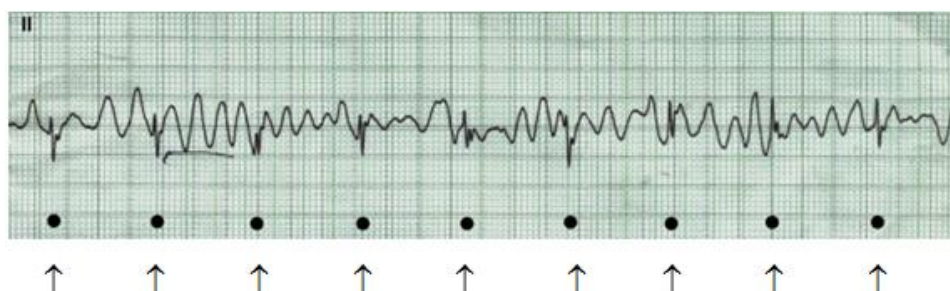


Figure 1

"Ventricular fibrillation" – markings at the bottom of the ECG strip coincides with QRS complexes. Indeed, at first look the ECG strip appears to show ventricular fibrillation, which has significant prognostic and therapeutic implications on the fourth day of post myocardial infarction. However, on careful analysis, QRS complexes can be seen (marked with dots at the bottom of ECG strip), confirming that the apparent fibrillation was nothing else but an artifact. Such artifacts can be produced by gel drying up due to exposure to air for long time, motion artifacts due to shivering/tremors/skeletal muscle contractions, poor skin contact, electrocautery, damaged cables and loose monitor lead connections<sup>[2,3]</sup>. If not analysed carefully and correctly, such electrocardiographic artifacts may lead to unnecessary and expensive diagnostic and therapeutic interventions.<sup>[4]</sup>

### III. Conclusion

The development of artifacts during electrocardiographic monitoring is not uncommon and often of no clinical significance. Most of the times, artifacts may be easily recognizable and therefore are neglected. However, sudden and unexpected appearance of some artifacts can be confusing and deceiving, knowledge and careful analysis of the characteristics of artifacts will lead to their correct diagnosis and exclusion as a cause of concern. Due to the widespread use of continuous cardiac monitoring in patients now a day, artifacts on ECG tracings are inevitable. Physicians and cardiologists should keep such artifacts in mind while analyzing and reviewing ECG recordings depicting ventricular fibrillation, particularly when other clinical characteristics of this potentially fatal arrhythmia are not present. Careful inspection will usually clarify the diagnosis and prevent risky and unnecessary therapeutic interventions that would otherwise be indicated in a genuine case.

**References**

- [1]. Tarditi DJ, Hollenberg SM. Cardiac arrhythmias in the intensive care unit. *Semin Respir Crit Care Med* 2006;27:221–9.
- [2]. Srikureja W, Darbar D, Reeder GS. Tremor-induced ECG artifact mimicking ventricular tachycardia. *Circulation* 2000;102:1337–8.
- [3]. Vereckei A. Pseudo-ventricular tachycardia: electrocardiographic artefact mimicking non-sustained polymorphic ventricular tachycardia in a patient evaluated for syncope. *Heart* 2004;90:81.
- [4]. Knight BP, Pelosi F, Michaud GF, Strickberger SA, Morady F. Clinical consequences of electrocardiographic artifact mimicking ventricular tachycardia. *N Engl J Med* 1999;341:1270–74.