

Custom made hook plate for osteoporotic communitied distal fibular fractures

Dr Ram Kumar Reddy K¹, Dr. Venkateswarlu J², Dr Jaisingh R³

¹Department of orthopedics, Kakatiya Medical College/ NTRUHS, India

²Department of orthopedics, Kakatiya Medical College/ NTRUHS, India

³Department of orthopedics, Kakatiya Medical College/ NTRUHS, India

Abstract : The accurate fixation of distal fibula is achieved by plating of fibula. Lack of subcutaneous tissue, tight skin, and communitied fracture of distal fibula are the common problems. Hook plate osteosynthesis is the solution for these difficult fractures, but high cost and uniform availability is a problem. A custom made hook plate from economical and easily available semi tubular plate applied by MIPPO technique bypassing the fracture offers a good option, having advantage in fixing this subcutaneous bone.

Keywords: Lateral malleolus fixation; custom made hook plate; MIPPO technique; distal fibula fixation

I. Background

Internal fixation of osteoporotic ankle fractures is technically difficult and may fail because of unreliable purchase. The communitied fracture and unyielding skin with lack of subcutaneous tissue at that place adds to the problem in secure fixation^[1]. Here we present use of a custom made hook plate providing an easy and secure fixation yet cheap alternative for these communitied distal fibular fractures.

II. Introduction

Fibular fractures usually associated with communitied especially in old age, osteoporotic patients and high energy trauma. The accurate fixation of these fractures is essential to achieve good reduction of associated tibial fractures^[2]. The tight soft tissues pose a problem especially to use a space occupying implants. This set of patients are benefited by the use of hook plate, which give a secure fixation without causing soft tissue stuffing or extensive exposure but these implants are costly and unavailable at times. In view of these issues we have using this plate prepared from easily available and economically priced plates.

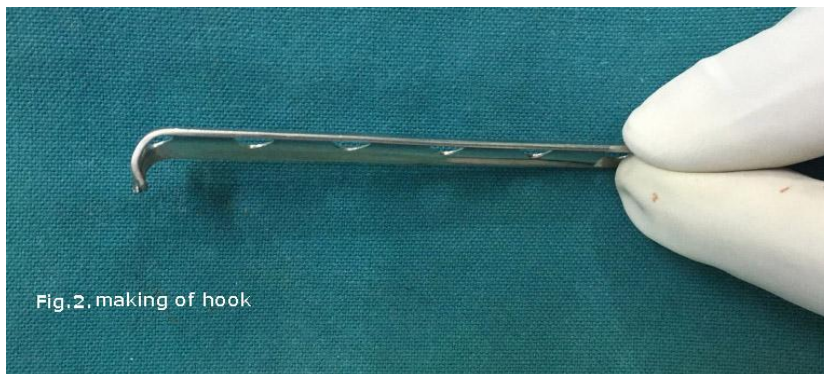III. Procedure

The patients with distal fibular fracture at or below level of the syndesmosis are selected. For these fractures pre-operative planning of plate length is estimated so as to have 3 screws proximal to fracture. A 1/3 tubular [semi tubular] Plate is taken, its ends are cut in 'v' shape (Fig.1) the loose piece discarded and




Fig.1. Distal cut of 1/3 semitubular plate

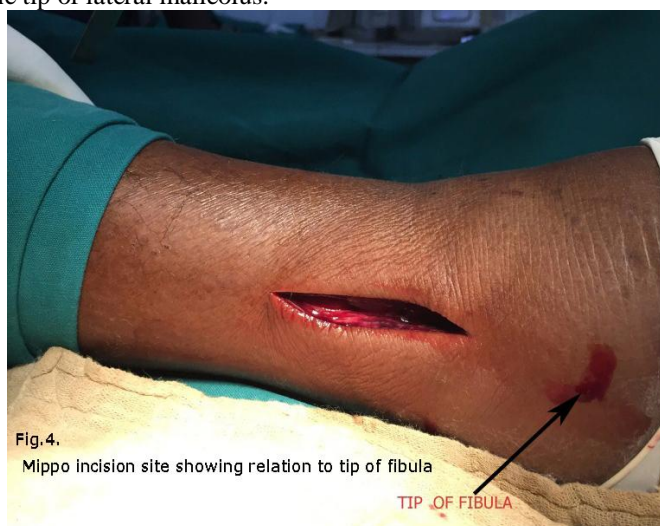then the sharp ends are bent to attain a hook shape (fig.2), so as to hitch on to the tip of fibula which gives a hold for counter traction force on traction effect of lateral collateral ligament .



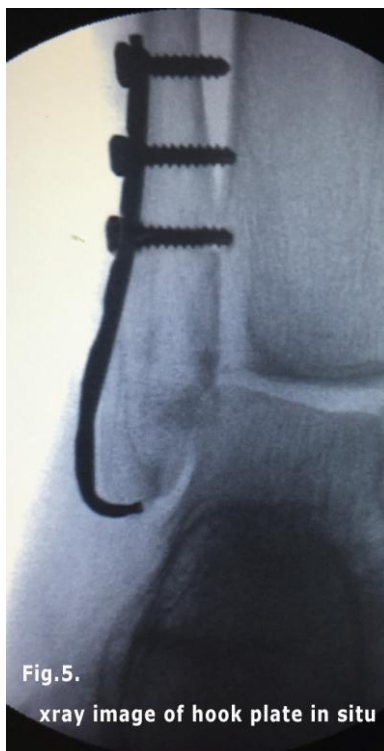
The plate is also pre-contoured to fit to lateral malleolus, by which the hook reaches to middle of tip of lateral malleolus for better holding.



By MIPPO technique fibula proximal to fracture is exposed and from there a subperiosteal tunnel is made with a periosteal elevator till the tip of lateral malleolus.



In to this tunnel the pre-contoured plate is inserted. After hooking the hook below the tip of lateral malleolus plate is fixed proximally with 3.5mm cortical screws. A compression device (Muller) may be used if required, to get a tight hold of hook over the tip of lateral malleolus (Fig.5).



The postoperative protocol is as usual.

IV. Discussion

The procedure is simple, and minimal instrumentation is required. The C'arm is useful to ascertain the placement of hook and reduction of fracture. The fixation here is without much hardware without much trauma to soft tissue and the plate acts as buttress to the fracture fragments along with stable fixation. The hook along with the proximally fixed screws, act as tension band principle. This implant is applied subperiosteally made tunnel, which helps in preservation of fracture hematoma, thus helping early healing and preventing devitalisation of skin and plate exposure. Further the procedure is easy and simple, can be done with minimal equipment.

V. Conclusions

The custom made hook plate is a good choice of Implant, fulfilling the requirement of specific patients. The procedure is simple and easily reproducible. This novel technique provides stable fixation for osteoporotic ankle fractures in elderly patients until union is achieved with good clinical scores.

References

- [1]. Sutter PM, Peltzer J. Principles of operative treatment of malleolar fractures today. *Eur J Trauma Emerg Surg.* 2010;36:505–14
- [2]. Fernandez GN. Internal fixation of the oblique, osteoporotic fracture of the lateral malleolus. *Injury.* 1988;19:257–8.