

Fracture-Dislocation of Talar Body: A Case Report

Mahibul Islam¹, Rajarshi Roy², Bikash Agarwal³, Tridip Bharali⁴.

^{1,2,3,4} (Department of Orthopaedics, Gauhati Medical College and Hospital, India)

Abstract: Fractures of the body of the talus are uncommon. Their relatively low incidence makes treatment of these injuries a challenge to the surgeon. A 48 year old male fell from a ladder and presented to our emergency department with talar body fracture – dislocation which was fixed internally after open reduction with cannulated cancellous screws within 6 hours of injury. He was followed up for one year. The fracture was found to be healed without any evidences of any infection, wound complications and avascular necrosis. The rarity of the case has prompted us to report this case along with review of appropriate literature.

Keywords: Avascular necrosis, fracture-dislocation, Hawkins, internal fixation, talar body.

I. Introduction

Talar body fractures are extremely rare injuries and are reported as accounting for about 0.1 per cent of all fractures [1]. It accounts for 7% to 38% of all fractures of the talus [2, 3]. Accurate articular reduction will bring back congruity of the tibiotalar and subtalar joints. Rigid internal fixation may provide stability to facilitate early mobility of these joints. Surgical treatment, with these aims, may optimize foot and ankle function [4]. Like injuries to the talar neck, they are associated with a high rate of complications including malunion, avascular necrosis and degenerative arthritis [5]. The clinical outcome after talar body fractures is determined by the severity of the injury and the quality of reduction and internal fixation. The incidence of avascular necrosis is almost certainly determined by the fracture pattern and its disruption of the intrinsic blood supply to the talus [6]. The revascularisation process can be achieved by surgical reduction and stable internal fixation [7,8]. So the surgeons aim should be early reconstruction of the talus to align the articular surfaces anatomically along with ensuring that the remaining precarious blood supply to the talus is not iatrogenically reduced further [9]. The timing of definite internal fixation does not appear to affect the final result [9, 10]. However, the outcome after operative treatment remains inadequately understood. We report a case of a displaced coronal fracture successfully treated by internal fixation.

II. Case report

A 48-year-old man fell approximately 8 feet off a ladder with most of his weight onto his left foot. He was unable to bear weight. On examination there was swelling and tenderness involving the left ankle. In addition he was unable to dorsiflex his great toe which was held in 30 degrees of plantar flexion. The patient was hospitalized after applying below knee plaster slab to control pain and edema.

Radiographic examination showed a displaced fracture of the body of the talus. The fracture was coronally oriented with displacement of the posterior fragment outside the ankle mortise posterior to the posterior malleolus. There was also an associated medial malleolus fracture of the same side.

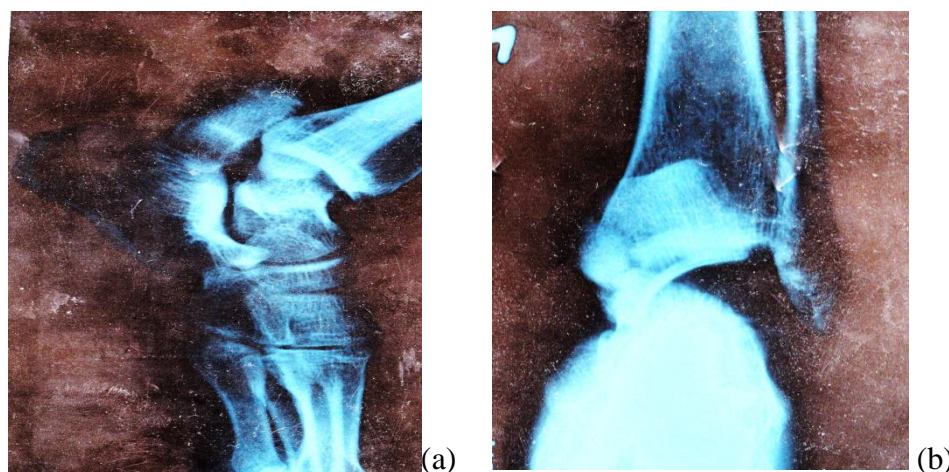


Fig 1a,b: preoperative radiograph Anteroposterior & Lateral

The patient was taken up for surgical intervention within 6 hours of injury. An incision, 10 cm long, beginning proximal and just anterior to the medial malleolus, curving distalward and plantarward toward the sole of the foot, and ending on the medial side of the body of the navicular, was given. Using the interval between the anterior and posterior tibial tendons the talus fracture site is exposed. As the medial malleolus was already fractured the exposure became even easier. The fragment was made free after exposing the tendons of flexor hallucis longus, flexor digitorum longus and tibialis posterior. The fracture was reduced and the ankle joint was irrigated well to remove any bony fragments or loose bodies. Provisional fixation was done with K-wires. Then a 4.0mm cannulated cancellous screw was inserted over a guidewire under the guidance of image intensifier television from lateral aspect of tendoachilles through Henry's approach dissecting the interval between flexor hallucis longus and peroneal tendons. The screw was placed from lateral projection of posterior process and was directed to the talar head. The medial malleolus was fixed with the help of a 4.0 mm cancellous screw.

The wound on both sides were closed in layers over a suction drain and the limb kept in a below knee slab. The drain was removed after 48 hours. The limb was kept in plaster for 2 weeks and then stitches were removed. No slough or skin dehiscence or any evidence of infection seen.

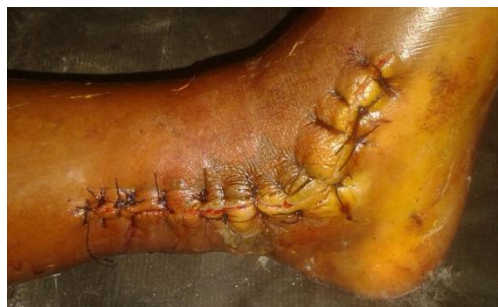

Fig 2: post operative wound

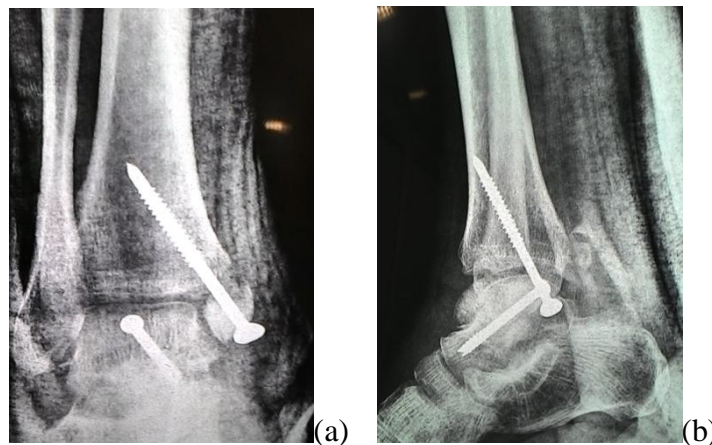


Fig 3a, b: immediate post operative radiographs

Ankle mobilisation was encouraged keeping the limb in non weight bearing for 3 months. On follow up radiographs the malleolus and the talus were found to be united. He was allowed to bear weight partially at three months and full weight bearing was commenced at four months. At 6 months follow up, he had full dorsiflexion and the plantar flexion was restricted to 20 degrees from neutral. He had full range of subtalar joint movements. He had pain free ankle movements and a normal gait. The radiographs taken at this time showed no evidence of avascular necrosis. The patient was followed up for one year.

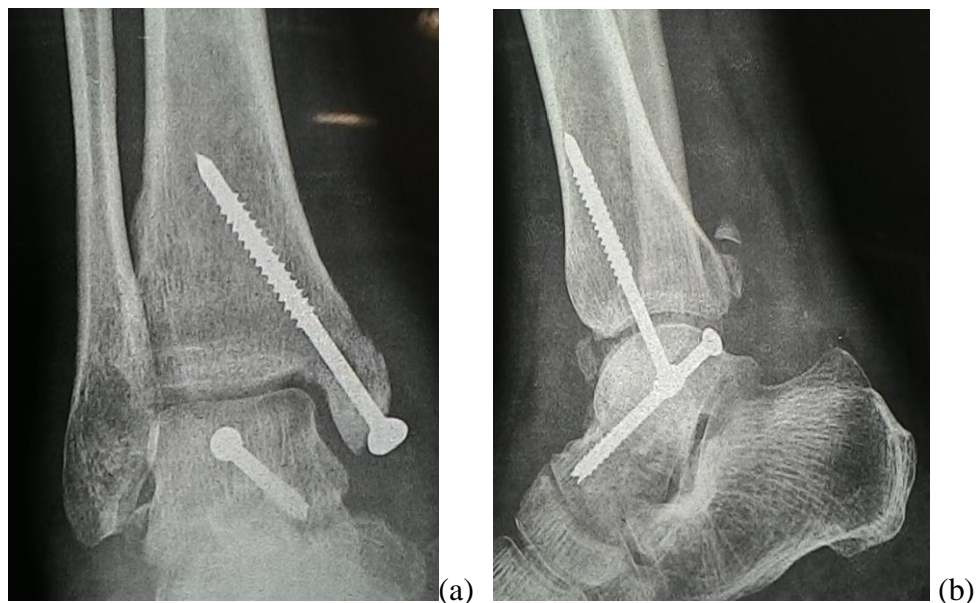


Fig 4a, b: Radiograph at 3 months showing union

III. Discussion

Talar body fractures are extremely rare. The body of the talus articulates with tibia, fibula and the calcaneus. The body of the talus carries the body weight during walking and is the main component of the most important joints of the foot. The prognosis of this fracture is often made worse by the development of avascular necrosis, due to disruption of the talar blood supply and/or degenerative arthritis. Avascular necrosis is less likely if an accurate reduction of any displaced fragment is stably held by internal fixation [11].

Shear fractures of the body of the talus are subdivided into coronal, sagittal and horizontal fractures. A shear fracture to the body of the talus is defined as one that has its dorsal fracture line extending into the articular surface of the dome of the talus. A coronal fracture is a more posterior location of a talar neck fracture. The prognosis after these fractures is poor [1,12].

Talar body fractures are produced by an axial compression of the talus between the tibial articular surface and calcaneus [13, 14]. In cases with a combined medial malleolar fracture, an additional inversion torque seems to distribute this force to the medial structures, producing a vertical split of the talar body and the medial malleolar fracture [15].

The customary treatment for comminuted fractures and fracture dislocations of the body of the talus has been talectomy or tarsal fusion. Results were, however, not satisfactory [16]. The risk of degenerative arthritis is minimized by anatomical reduction of the fracture [1]. So the trend shifted from joint fusion to fixation of the talus. Because posteroanterior screw position gave more stability in a biomechanical trial [19] our patient was operated in the same manner.

The diagnosis of talar avascular necrosis (AVN) was described by Hawkins in 1965. The appearance of a radiolucent zone 4-8 weeks after the injury at the subcortical bone of the talar dome indicating bone remodelling "Hawkins' sign" is highly predictive of a revitalisation of the talar body after a fracture. We have not seen AVN in our patient.

Skin necrosis and osteomyelitis can occur after talar body fracture. Arthritis in the ankle and subtalar joints can occur in the absence of avascular necrosis of the talus and joint incongruity [8].

IV. Conclusion

Fracture of talar body is a severe injury which is seen very rarely. Due to its rarity a clinician confronting such a fracture should be aware to ensure anatomical reduction of this fracture. This will provide the conducive biomechanical environment for revascularisation of talus. Successful surgical reconstruction can produce a pain free mobile patient with a good range of movement.

References

- [1]. Sneppen. et al. (1977) Fracture of the body of the talus. *Acta Orthop. Scand.* 48,317.
- [2]. Higgins TF, Baumgaertner MR: Diagnosis and treatment of fractures of the talus: a comprehensive review of the literature. *Foot Ankle Int* 1999, 20:595-605.
- [3]. Ebraheim NA, Patil V, Owens C, Kandimalla Y: Clinical outcome of fractures of the talar body. *International Orthopaedics (SICOT)*. DOI 10.1007/s00264-007-0399-5.
- [4]. Vallier HA, Nork SE, Benirschke SK, Sangeorzan BJ. Surgical Treatment of Talar Body Fractures. *J Bone Joint Surg Am*, 2004 Sep; 86 (1 suppl 2): 180 -192 .
- [5]. Charles M, Court-Brown. Fractures of talus. In Bucholz RW, Heckman JD, Court-Brown CM. *Rockwood and Green's Fractures in Adults*. 6th edition.
- [6]. Haliburton RA, Sullivan CR, Kelly PJ, Peterson LF: The extraosseous and intra-osseous blood supply of the talus. *J Bone Joint Surg Am* 1958, 40:1115-1120.
- [7]. Rammelt S, Zwipp H: Talar neck and body fractures Injury. *Int. J. Care Injured* 2009, 40:120-135.
- [8]. Morgan G, Ramaswamy R, Frost B, Hariharan K: Talar body fractures: A case report of successful surgical management and review of the literature. *Injury Extra* 2007, 38:39-42.
- [9]. Kilic A, Kabukcuoglu Y, Sokucu S. The treatment of talar body fractures with compression screws: a case series. *Cases Journal* 2009, 2:7953.
- [10]. Inokuchi S, Ogawa K, Usami N: Classification of fractures of the talus: clear differentiation between neck and body fractures. *Foot Ankle Int* 1996, 17:748-750.
- [11]. Pearse MF, Fowler JL, Bracey DJ. Fracture of the body of the talus. *Injury: the British Journal of Accident Surgery* (1991) Vol. 22/No.2;p155-6.
- [12]. Mindel E, Cieske E, Kartalian G. Late result of the injuries of the talus. *J Bone Joint Surg Am*, Volume 45, 1963, pp. 221–245
- [13]. Thordarson DB: Talar body fractures. *Orthop Clin North Am* 2001, 32:65-77.
- [14]. Verettas DAJ, Ververidis A, Drosos GI, Chatzipapas CN, Kazakos KI: Talar body fracture combined with bimalleolar fracture. *Arch Orthop Trauma Surg* 2008, 128:731-734.
- [15]. Devalia KL, Ismaiel AH, Joseph G, Jesry MG: Fourteen years follow up of an unclassified talar body fracture with review of literature. *Foot Ankle Surg* 2006, 12:85-88.
- [16]. Blair HC. Comminuted fractures and fracture dislocations of the body of the astragalus. *The American Journal of Surgery*. January 1943, Vol.59(1):37–43.
- [17]. Swanson TV, Bray TJ, Holmes GB Jr: Fractures of the talar neck. A mechanical study of fixation. *J Bone Joint Surg Am* 1992, 74:544-551.