

## Proximal Tibia Parosteal Osteosarcoma Treated With Total Knee Arthroplasty In A 40 Year Female Patient- A Case Report.

Tulasidas Bhattacharyya<sup>1</sup>, Rajarshi Roy<sup>2</sup>, Tridip Bharali<sup>3</sup>.  
<sup>1,2,3</sup> (Department of Orthopaedics, Gauhati Medical College and Hospital, India)

---

**Abstract:** Parosteal osteosarcoma is a rare low-grade bone tumour. Wide resection of a parosteal osteosarcoma usually prevents local recurrence. In literature, hemicortical resections of low-grade malignant bone tumors and allograft reconstruction are described. We have described a method of resection and reconstruction of parosteal osteosarcoma proximal tibia using custom made total knee replacement prosthesis. We are presenting a case of parosteal osteosarcoma of proximal tibia complicated with an unplanned biopsy scar in a 40yr female patient in whom initially R0 resection & stabilisation with K nail was done followed by total knee arthroplasty after 6 months. Patient was followed up for 1 year. There was no recurrence and she had knee ROM of 45 degree.

**Keywords:** arthroplasty, osteosarcoma, parosteal, proximal, tibia.

---

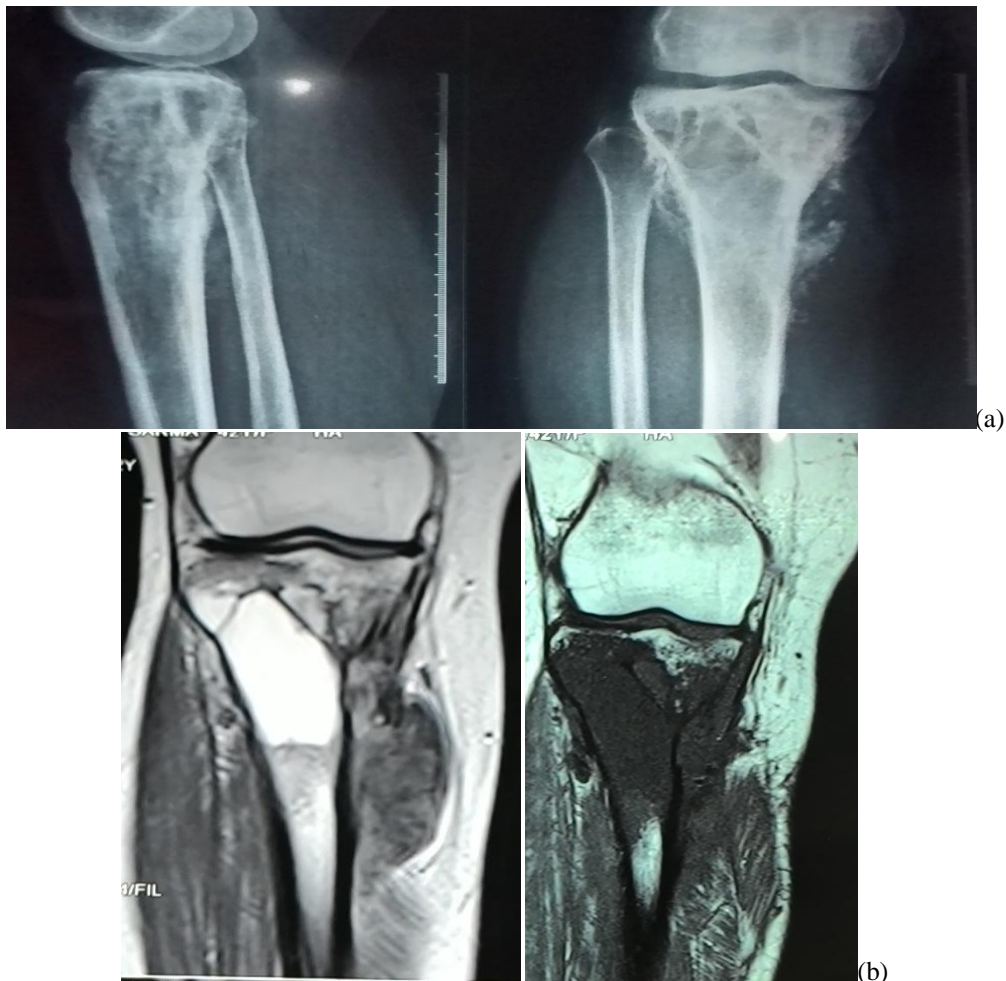### I. Introduction

Parosteal osteosarcoma is a rare low-grade bone tumour which usually arises on the surface of the metaphysis of long bones, representing 1–6% of all osteosarcoma. It occurs between 2<sup>nd</sup> and 7<sup>th</sup> decade of life. Parosteal osteosarcoma is an uncommon tumour and even large institutions mostly have limited experience of its management<sup>1,2,3,4,5</sup>. The most frequent location is the distal dorsal femur. Until clearly proven otherwise, a bone-forming tumour in this localisation must be regarded as parosteal osteosarcoma<sup>6</sup>.

The diagnostic criteria to designate a surface osteosarcoma as parosteal osteosarcoma were defined by Okada et al<sup>7</sup>. They concluded that radiographically, the lesion should arise from the surface of the bone, histologically, the tumour should be well differentiated (Grade 1 or 2); it should be characterized by well formed osteoid within a spindle-cell stroma and medullary involvement, if any, should be <25% of the medullary cavity. Resection with a wide operative margin is the most appropriate method of treatment. Treatment with wide resection and reconstruction with prosthesis has been advocated. The tumour is most commonly misinterpreted as osteochondroma or heterotrophic ossification<sup>3</sup>. Parosteal osteosarcoma shows unlike other tumours the necessity of close cooperation of all involved disciplines for diagnosis and therapy and should be treated only in specialized institutions for bone tumour surgery. The scarcity of adequate literature after extensive review has prompted us to report this case.

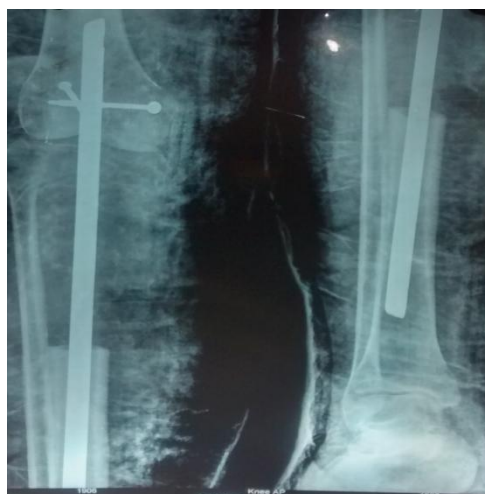### II. Case report

A 40 yr old female presented with a history of swelling over the anterior aspect of proximal part of right leg for 3 months. The swelling was gradually increasing in size associated with pain for last 1 month. At time of presentation the size of the swelling was 7cmX6cm. There was no history of fever, trauma, difficulty in walking and reduced knee range of motion. On clinical examination the swelling was ovoid in shape with irregular surface, firm in consistency and continuous with tibia. The skin overlying shows multiple healed linear surgical scars. The skin was not fixed to the swelling except for the areas of the scar. There was no distal neurovascular deficit. Radiography showed a relatively dense, well-demarcated ossified mass at a juxtacortical area on proximal part of tibia without joint involvement. MRI showed well defined multi lobulated soft tissue mass in the metadiaphysis of the proximal right tibia. Biopsy was taken outside our institute, which showed low grade parosteal osteosarcoma.

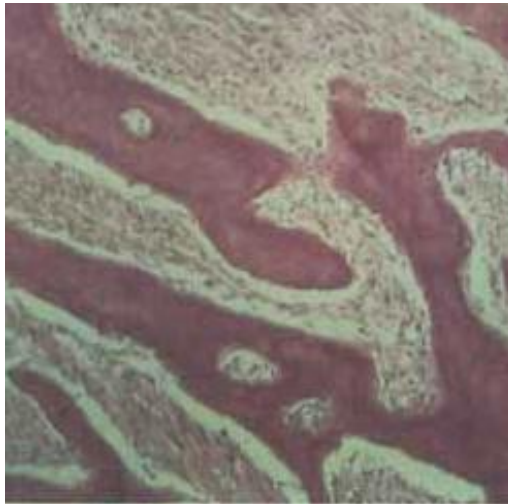


**Fig 1a,b:** preoperative radiograph and MRI

Debulking of the tumour mass was done outside our institute as evident from the scar over the anteromedial aspect of proximal leg. HRCT Thorax, CECT Abdomen and Bone scan did not reveal any skip or metastasis. In our institute resection of tumour through a separate anterior midline incision over the knee was done. The previous scar of debulking surgery was also excised along with the tumour. Sample was sent from the margin to check for clearance of tumour. Limb was stabilised with a K-nail. Patient was followed up regularly for 6 months to check for any recurrence of tumour and to assure full skin coverage.

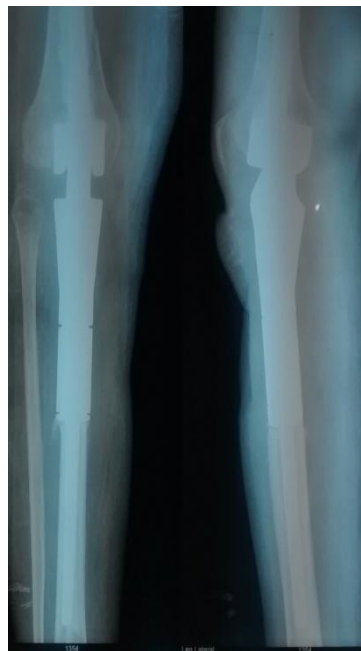

**Fig 2:** radiograph after tumour excision and stabilisation by K - nail



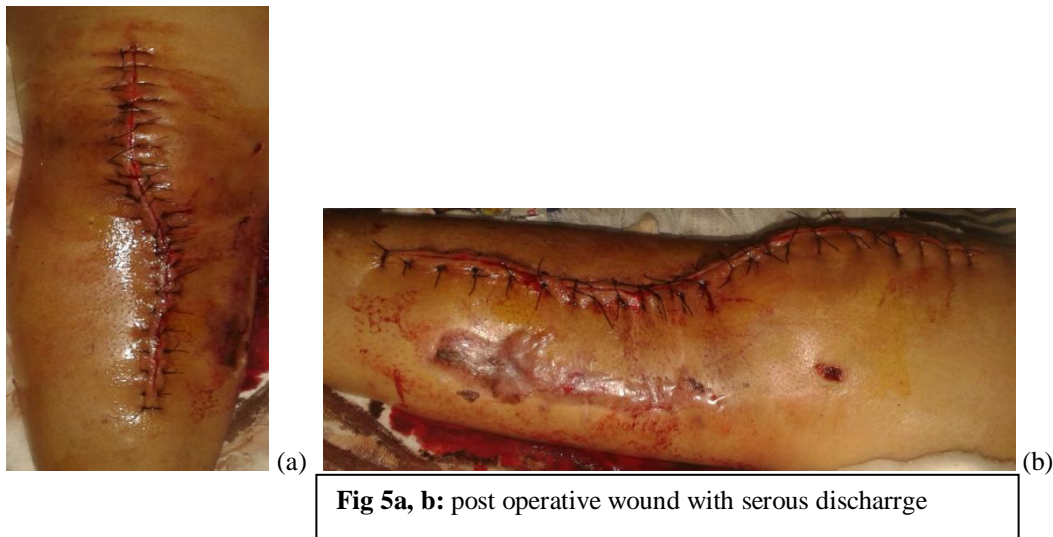
**Fig 3:** histopathological slide showing grade 1 differentiated parosteal osteosarcoma

After 6 months patient was electively planned for total knee arthroplasty with custom made prosthesis. Anterior midline incision was given incorporating the previous incision and sent for histopathology. The knee was exposed through medial parapatellar approach. The K-nail was removed and sample was taken from margin of tibia to reconfirm tumour clearance. After appropriate preparation of the distal femur and remaining tibia the prosthesis was fixed with bone cement. The skin was closed in layers.

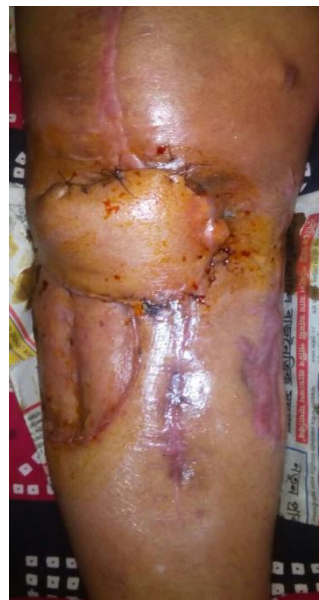

**Fig 4:** post operative custom made prosthesis

Patient was doing well immediate postoperatively but there was serous discharge from the middle of the wound after 5 days. The discharge was found to be sterile on culture and there was gaping of wound after another 10 days.



Patient was electively planned for plastic surgery intervention and wound was covered by Gastrocnemius musculocutaneous flap. The wound healed uneventfully.



**Fig 6:** gastrocnemius musculocutaneous flap

Knee movement and weight bearing were started after wound healing. Patient was followed up for 1 yr. There is no recurrence of tumour or wound complication till now. At present knee range of movement is 45 degree.

### III. Discussion

Parosteal osteosarcoma is an uncommon, low-grade and well-differentiated tumour with limited involvement of the medullary canal. In spite of a relatively favourable prognosis seen in most parosteal osteosarcoma, published series have also included cases with clinical course characteristic of aggressive and highly malignant tumours. In fact, it has been suggested that two basically different types of parosteal osteosarcoma exist. One originally benign but potentially malignant and the other primarily malignant<sup>8,9,10</sup>. Moreover, an extremely rare periosteal variant of osteosarcoma has been reported, differing from parosteal osteosarcoma clinically, radiographically and histologically<sup>3</sup>.

The most frequent location is the distal dorsal femur. Until evidences suggested otherwise, a bone-forming tumour in this localisation must be regarded as parosteal osteosarcoma. To determine the histopathological diagnosis the tumor is characterised by hyalinized fibrous stroma with low cell content

without substantial nucleus polymorphism and variably dense bony trabeculae. The operation material must undergo a careful histopathological analysis, because the extent of invasion of the medullary cavity and the extent of dedifferentiated areas determines the prognosis and occurrence of local recurrences and metastases<sup>3,4</sup>.

The duration of symptoms is generally reported to be considerably longer for patients with parosteal osteosarcoma than for those with intramedullary osteosarcoma.<sup>11</sup> This is confirmed by the study done by Larson et al<sup>12</sup> in which 55 per cent of the patients had symptoms for periods ranging from six months to several years: in comparison, it was found that 62 per cent of patients with intramedullary osteosarcoma sought medical advice within two months and an additional 26 per cent within six months<sup>12</sup>. The opinion was put forward by Unni and coworkers (1976)<sup>3</sup>, that a slow-growing, painless and hard mass in the popliteal region should arouse suspicion of parosteal osteosarcoma. Radiographs are usually very characteristic<sup>13</sup>. Lesions such as myositis ossificans, osteocartilaginous exostosis, extra-osseous osteosarcoma and intramedullary osteosarcoma should be considered as differential diagnoses.

Many procedures were described in the literature for the treatment of parosteal osteosarcoma. Inadequate resection can cause local recurrence and distant metastases. Marginal but histological negative surgical margin seems adequate for local control of parosteal osteosarcoma and to prevent distant metastases. Since parosteal osteosarcomas are low grade lesions, they can be treated by wide excision without adjuvant chemotherapy and they require either marginal or wide excision. The technique of hemicortical resection for treating parosteal osteosarcomas was first described by Campanacci et al. in 1982<sup>14</sup>. The decision on whether a lesion can be treated by hemicortical excision should be taken after carefully evaluating the preoperative imaging modalities and histopathological grade.

The aim of repair after partial resection of one condyle of the femur or tibia at the knee is to preserve movement: for this the patella from the same knee with supporting cortico-cancellous autogenous grafts can be used<sup>15</sup> or a massive homogenous articular graft can be substituted for the excised part<sup>16</sup>.

In classical osteosarcoma without evidence of "skip's metastases, an adequate surgical margin must include continuous compartmental muscular cover over a lesion involving the medullary cavity and with or without a limited extracortical extension. The transmedullary margin should include the entire circumference of the shaft 5 to 10 cm from the nearest point of abnormality on a bone scan or computerised tomogram. In parosteal osteosarcoma the tumour is, by definition originally extracortical, and it most often presents in an extracompartmental area such as the popliteal fossa or the axilla. In these regions the tumour is not covered by muscle, nor included within a muscular compartment, but grows into the loose fibro-fatty tissue adjacent to neurovascular structures. If these neurovascular structures can be dissected away from a freely movable fibrofatty tissue plane completely covering and encasing the entire tumour and the contiguous bone, then we believe that this is an adequate surgical margin, regardless of the histological grade<sup>17</sup>.

When the whole distal end of the femur or proximal end of the tibia has to be resected any attempt to save movement of the knee may be a risky option and should be reserved for rare and selected cases. The percentage of good results from replacement of the whole end of a femur or tibia using a homogenous massive graft is low, no more than 25 per cent<sup>18</sup>: the operation has several complications which make it difficult to attain a sufficient range of movement and moreover there is a high risk of resorption and fracture of the grafted epiphysis. On the other hand, the use of a total hinged prosthesis is rarely indicated. While total prostheses are suitable substitutes for the distal femur in a case of resection of the proximal tibia the covering of soft tissue would be sparse and it would be impossible to reattach the quadriceps tendon.

The decision of whether or not to perform limb salvage<sup>19</sup> or amputation depends on the individual case. Local recurrence was more common after limb salvage, but it did not seem to predispose to metastases.

Since in our case the whole metadiaphyseal region of the upper tibia is involved hemicortical resection could not be planned. The unplanned debulking done outside our institute, which left a contaminated scar away from the conventional incision sites for definitive management, has prompted us to plan for total knee replacement in 2 stages. This helped us to manage the skin coverage over the prosthesis.

#### **IV. Conclusion**

Surface osteosarcomas are distinct clinicopathological entities. Radiological tools such as CT scan and MRI are vital to the diagnosis and surgical planning of these lesions. Parosteal osteosarcoma can be treated by upfront surgery without neo-adjuvant chemotherapy, while high grade lesions should be subjected to neo-adjuvant protocol similar to conventional osteosarcoma. Wide margin resection with arthroplasty has given satisfactory result to our patient with respect to functional outcomes. The special attention given to skin coverage of the prosthesis, though was cumbersome to the patient due to unplanned initial biopsy incision, had eventually given reasonably satisfactory function to the limb.

### References

- [1]. Campanacci M, Giunti A, Grandesso F. Sarcoma periostale ossificante (31 osservazioni). *Chir Organi Moz'* 1968 ;57 : 3-28.
- [2]. Campanacci M, Giunti A. Periosteal osteosarcoma : review of 41 cases, 22 with long-term follow-up. *Ital J Orthop Traumatol* 1976; 1 : 23- 35.
- [3]. Unni KK, Dahlin DC, Beabout JW, Ivins JC. Parosteal osteogenic sarcoma. *Cancer* 1976 :37 : 2466-75.
- [4]. Ahuja SC, Villacin AB, Smith J, Bullough PG, Huvos AG, Marcove RC. Juxtacortical (parosteal) osteogenic sarcoma. *J Bone Joint Surg [Am]* 1977 :59-A :632-47
- [5]. Lorentzon R, Larsson S-E, Hoquist L. Parosteal (juxtacortical) osteosarcoma: a clinical and histopathological study of 11 cases and a review *J Bone Joint Surg [Br]* 1980 :62-B: 86-92.
- [6]. Samardziski M et al. Parosteal osteosarcoma. *Bratisl Lek Listy* 2009; 110 (4)
- [7]. Okada K, Frassica FJ, Sim FH, Beabout JW, Bond JR, Unni KK. Parosteal osteosarcoma. A clinicopathological study. *J Bone Joint Surg Am.* 1994;76:366—78.
- [8]. Scaglietti O, Clandriello B. Ossifying parosteal osteosarcoma. *J Bone Joint Surg Amer* 1962 44-A: 635 647.
- [9]. Farr GH, Huvos AG. Juxtacortical osteogenic sarcoma: an analysis of fourteen cases. *J Bone Joint Surg [Am]* 1972 :63—A: 1205-16.
- [10]. Lichtenstein L. *Bone tumors*, 4th ed. Saint Louis: CV Mosby Company. 1972.
- [11]. Van der Heul RO, von Ronnen JR. Juxtacortical osteosarcoma: diagnosis, differential diagnosis, treatment, and an analysis of eighty cases. *J Bone Joint Surg [Am]* 1967:49—A:415-39.
- [12]. Larsson SE, Lorentzon R. The geographic variations of the incidence of malignant primary bone tumors in Sweden. *J Bone Joint Surg Amer* 1974: 56-A: 592 600.
- [13]. Dahlin DC, Unni KK. Osteosarcoma of bone and its important recognizable varieties. *Am Surg Pathol* 1977;1(1):6[-72.
- [14]. Campanacci M, Capanna R, Stili S. Posterior hemiresection of the distal femur in parosteal osteosarcoma. *Ital J Orthop Traumatol.* 1982;8:23—8. [PubMed] Merle d'Aubigné, R., and Alexandre, G. (1966)
- [15]. Reconstruction condylienne fémorale par greffe rotulienne pédiculée. *Revue de Chirurgie Orthopédique et Réparatrice de l'Appareil Moteur*, 52, 611—633.
- [16]. Campanacci, M., Giunti, A., and Olmi, R. (1975) Tumore a cellule giganti dello scheletro. *Giornale Italiano di Orthopedia e Traumatologia*. 1, 249-277.
- [17]. M. Campanacci, P. Picci, F. Gherlinzoni, A. Guerra, F. Bertoni, J. R. Neff. Parosteal osteosarcoma. *J Bone Joint Surg* 1984;66B:3:313-21.
- [18]. Parrish, F. F. (1966) Treatment of bone tumors by total excision and replacement with massive autologous and homologous grafts. *Journal of Bone and Joint Surgery*. 48-A. 968—990.
- [19]. Luck J V Jr. Luck J V, Schwinn C P. Parosteal osteosarcoma: a treatment oriented study. *Clin Orthop* 1980: 153: 92—105.