

Pre-Operative ERCP Is a Significant Difficulty Predictor For Laparoscopic Cholecystectomy – An Analysis

Dr. Ranjith Rao M.¹, Dr. Sunil Kumar Math², Dr. Sathyanarayana N.³

*Assistant Professor Dept. of Surgery Kasturba Medical College (Affiliated to Manipal University)
Light House Hill Road, Mangalore PIN 575001, Karnataka State, India*

Senior Resident, Department of General Surgery Kasturba Medical College, Mangalore (Affiliated to Manipal University) Light House Hill Road, Mangalore PIN 575001, Karnataka State, India

Consultant GI & Laparoscopic Surgeon, K.M.C. Hospital, Mangalore, Centre for Digestive Surgery, Mangalore Nursing Home campus 575001 and K.I.M.S Hospital, Kasaragod, India

Abstract:

Background: Laparoscopic cholecystectomy (LC) is the standard treatment following ERCP & Endoscopic Sphincterotomy (ES) for CBD stones and gall stone pancreatitis. This surgery may be difficult needing longer operating times with risk for conversion and bile duct injury. We analyzed factors which could be overcome to minimize complications.

Methods: We evaluated all cases from 2008 to 2014 who underwent LC following ERCP & ES. The time interval between the two procedures was noted along with pre-operative and intraoperative factors making surgery difficult or leading to conversion. The difficulty in handling the gall bladder, changes in Calot's triangle anatomy and appropriate technical modifications in the approach were documented.

Results: The study analyzed 56 patients who underwent LC following ERCP & ES. Changes in anatomy observed were a frozen Calot's triangle in 32 cases, short and wide cystic duct difficult to clip in 22 cases, difficult to handle gall bladder in 36 cases, lateral rent in the cystic duct in 8 cases, an adherent cystic duct and CHD like in Mirizzi syndrome in 10 cases. 3 cases had bile duct injuries and 8 cases were converted.

Discussion: LC after ERCP & ES is often a technical challenge. The surgeon can educate the patient regarding the anticipated difficulties and the need for long operating times or conversion in advance. Meticulous dissection close to gall bladder with a ligature for handling ensures opening of cystohepatic triangle. Wide cystic duct requires ligation. The timing of the surgery after ERCP & ES should be within 48-72 hours to reduce the difficulty which may otherwise arise in delayed cases.

Key words: Laparoscopic cholecystectomy, difficulty, predictor, post-ERCP, bile duct injury, conversion

I. Introduction

Laparoscopic cholecystectomy (LC) is the procedure of choice for symptomatic gall stones. In the presence of bile duct stones or gall stone pancreatitis the standard of care has been ERCP with Endoscopic Sphincterotomy (ES) and stenting. Such patients are treated subsequently with a laparoscopic cholecystectomy to prevent recurrent biliary symptoms and complications. The decision to perform LC depends on the type of presentation of symptoms and the recovery of the patient.

LC following ERCP & ES has been considered difficult needing longer operating times and having higher conversion rates. The treating surgeon should anticipate problems that may arise when performing the procedure and should be prepared in advance to convert the procedure so as to safe guard the biliary apparatus or to reconstruct any damage that may have occurred inadvertently.

There are certain structural changes that develop after ERCP & ES which obscure the anatomy and make handling difficult. Fibrosis around the Calot's triangle and adhesions due to inflammatory process or pancreatitis also add to the difficulty. Dissection in such a situation may be hazardous leading to bleeding or injuries to the bile duct. One has to be aware of these changes during surgery so that one can technically deal with such a situation accordingly and avoid untoward outcomes.

The patients undergoing LC can be educated regarding their condition and made aware of the anticipated difficulty and need for a possible conversion. The aim of the study was to analyze pre-operative and intra-operative factors leading to significant difficulty or conversion when treating such patients along with measures taken to minimize complications.

II. Material & Methods

We evaluated all consecutive patients from 2008 to 2014 who underwent ERCP & ES and subsequently planned for LC. Valid informed consent was taken from all the patients informing them about the difficulties that may be encountered and the possible conversion to an open procedure. All the cases presented with pain abdomen and on evaluation were found to have gall stones with altered liver function tests in the form of increased bilirubin with increased ALP and increased serum amylase levels. None of them had features of cholangitis or clinical jaundice. All of them were subjected to ERCP with sphincterotomy with the clinical suspicion of bile duct stones and all had stones varying from sludge to 3mm size. Patients with features of acute cholecystitis or previous recurrent episodes were excluded from the study.

Patients were taken up for LC once they recovered from the procedure in the form of general well being, decrease in pain abdomen with drop in serum amylase levels in those patients with elevation post procedure. The time interval between the two procedures was noted and assessment of the preoperative & intraoperative factors leading to a difficult LC or conversion was done. The number of cases with difficulty in handling the gall bladder, changes in Calot's triangle anatomy and the appropriate technical modifications done in the operative approach were documented. The operating time was recorded in all cases. Statistical analysis of the data was done using the Chi square test with a p value of less than 0.05 considered significant.

III. Results

We collected data of 56 patients who underwent LC following ERCP & ES. The average age group was 45 years (25-65 years). There were 38 females and 18 males in the study. All the procedures were performed by 2 surgeons with experience of more than 200 individual cases. Standard port positions were used. None of the patients had previous abdominal surgeries. Creation of pneumoperitoneum was not difficult. There was no need for the use of extra ports.

Varying changes in anatomy were observed which included a Frozen Calot's triangle having difficulty identifying cystic duct, artery and bile duct in 32 cases, short and wide cystic duct difficult to clip in 22 cases, difficult to handle gall bladder due to inflammatory adhesions and increased wall thickness in 36 cases, lateral rent in the cystic duct in 8 cases, an adherent cystic duct and CHD leading to Mirizzi syndrome like picture in 10 cases. Most of these findings correlated with the timing of surgery after ERCP & ES with more difficulty encountered in cases operated after a delayed time interval between the two procedures as enlisted in Table 1. We found that a delay of more than 72 hours post ERCP resulted in difficult LC and more rates of conversion ($p < 0.001$). 6 cases had intraoperative bleeding of which 4 needed blood transfusions. 3 cases had bile duct injuries, all recognized intra operatively and one among them present with bile leak post operatively. Total of 8 cases were converted to an open procedure, 3 cases with bile duct injuries and 5 cases having suspicion of bile duct injuries due to unclear anatomy and bleeding. 3 cases underwent sub-total LC. There were no major vascular or bowel injuries. All the above have been enlisted in Table 2.

Performance of visual cholangiogram¹ to identify CBD and hepatic duct was done in all the cases. This meant that structures were visually identified without any dissection to get oriented to the anatomy at the Calot's triangle and hilum of liver. Intra operative cholangiogram was done in 6 cases having significant difficulty in identifying anatomy. One case of Mirizzi syndrome with a cholecysto-cholecho fistula was recognized & managed with closure of the defect using cystic duct stump as a flap. This case presented with bile leak post operatively which stopped spontaneously after 3 days. Another case of bile duct injury at the junction of cystic duct and common hepatic duct was also managed with flap closure using the cystic duct stump. This case had uneventful post-operative period. 5 other cases with unclear anatomy were also converted although none having bile duct injuries. 1 case of complete common hepatic duct transection was detected intraoperatively & managed with a retro-colic Roux-en-Y Hepatico-jejunostomy.

The operative time recorded showed that the procedure was completed in less than 1 hour in 22 cases, 1-2 hours in 26 cases and more than 2 hours in 8 cases (35- 230 mins, average 84.8 mins).

IV. Discussion

An elective LC is the standard of care in patients with pre-operative ERCP & ES for choledocholithiasis and gall stone pancreatitis². LC in such a scenario is considered a difficult procedure requiring longer operating hours and having a higher rate of conversion compared to LC in symptomatic uncomplicated gall stone disease^{3,4,5}. We included 56 such cases in our study and analysed various factors that were associated with difficulty and conversion to open procedure. In the due course of this study we made certain modifications in the operative approach to certain cases ensuring reduction in complications.

Pre-operative endoscopic sphincterotomy has been considered to be associated with significant difficulty during LC by several authors^{4,6,7}. In our study we witnessed a linear relationship between the time interval of post ERCP and LC and the difficulty encountered during surgery (Table 1). Conversion rates were more in cases operated 72 hours after ERCP to beyond 7 days post ERCP⁶. The reasons for difficulty were due to changes in anatomy and presence of dense adhesions. All patients underwent surgery after recovery from the endoscopic procedure. Early in the study we had a tendency to delay the surgery till the patient recovered completely in terms of symptoms and generalized well being. Later on in the due course of the study we relied on the normalization of the biochemical markers as a guide to initiate LC. Some individuals though were asymptomatic following endoscopic sphincterotomy the presence of abnormal biochemical markers made us to wait before LC as we anticipated problems as a result of pancreatitis. None of these patients had serum amylase levels beyond three times the upper limit though. These periods varied in each individual which led to surgeries being performed at different intervals.

The causes for changes in anatomy that can be attributed to pre-operative inflammatory process or ERCP have also been studied by few authors^{8,9}. We eliminated patients with acute symptoms like cholangitis and acute cholecystitis from the study. It has been postulated that repeated passage of small gallstones through the cystic duct into the biliary tract, multiple previous ERCPs & contrast material injection may cause obstruction, inflammation, or distortion of anatomy at Calot's triangle^{4,10}. It is also a known fact that ERCP and stenting increases the bacterial colonization in the bile which may be a factor that may induce inflammation simulating cholangitis. All of our patients had only one successful ERCP with a single stent in situ pre operatively. Pre-operative inflammation may be the factor responsible for the changes that explain the fibrotic process as more time period should have elapsed for such changes. Many of the patients had history of taking treatment for dyspepsia but none of them had previous admissions or acute symptoms pertaining to gall stones.

In a study by one of the authors regarding scoring method for predicting difficult laparoscopic cholecystectomy it was seen that pre-operative ERCP is a factor responsible for a difficult Calot's triangle dissection¹¹. The change in gall bladder structure is also a factor which makes handling difficult. Gall bladder tends to become thickwalled as a result of fibrosis secondary to previous inflammation. The ERCP-triggered inflammatory reaction in the biliary tree and Calot's triangle maybe the cause for scarring and fibrosis of the gallbladder in the long run^{10,12}. Such an atrophic and sclerotic gall bladder following ERCP is associated with higher rates of bile duct injury. We noticed in many cases that the cystic duct was short and wide and difficult to clip with the usual sized clips (Fig. 1). We had to ligate the duct with sutures or apply long clips to divide safely without having the risk of stump bile leak post operatively. Whether this pre-existing short and wide cystic duct led to choledocholithiasis or whether it was a secondary change is a subject for future research but the feasibility of such a study is questionable as it is a factor that cannot be modified.

The inflammatory response was most evident in the Calot's triangle with cystic duct and common hepatic duct appearing frozen with the inability to differentiate individual structures. An attempt to make a window in the Calot's triangle resulted in a rent in the lateral aspect of cystic duct in few initial cases.

The dissection process was also made difficult due to the bleeding happening around Calot's triangle and pericholedochal region. The bleeding was diffuse making visibility a problem and the subsequent fear of inadvertently damaging structures with an attempt to control the bleeding. Liver bed bleeding was also higher as the plane of dissection was altered due to the adhesions and liver capsule tears. Use of surgical gauze during the dissection alleviated much of this difficulty.

A Mirizzi Syndrome like picture was seen in few cases with adherent cystic duct and common hepatic duct. We had to adopt certain modifications in the operative procedure in later cases to ensure minimal iatrogenic injury to the bile duct. Two of our cases with injury were as a result of cholecysto-choledochal fistula. Early in the surgery a plane was tried to develop in between the gall bladder near the Hartmann's pouch and the

liver bed keeping close proximity to the former. A ligature was passed at this junction around the gall bladder and was held in traction outwards and laterally trying to open the Calot's triangle and dissection proceeded caudally with caution (Fig. 2). This maneuver made handling of gall bladder easy and prevented the development of lateral rent in the cystic duct in later cases.

The conversion rate was 14% in our study (Table 2), though the numbers were higher in the initial cases due to the unfamiliarity with the situations encountered. The above mentioned modifications ensured the prevention of bile duct injuries and increased the threshold for conversions. Six out of the eight cases were converted in the first half of our study showing that modifications in the surgical technique were crucial in reducing morbidity. Most of the later cases were also operated within the time interval of 48 to 96 hours post ERCP. Pre-operative ERCP with sphincterotomy has been associated with difficulty and longer operating time with a high probability for conversion as shown in our study. An analysis of this factor enables the surgical team to modify the surgical strategy and adapt to the situation in demand so as to perform the procedure without complications. Timely conversions reduce the operative morbidity and risk of injuring the biliary apparatus. Application of certain technical modifications minimizes the risk of iatrogenic morbidity. This also makes possible for education of the patient in advance regarding the possible change in course of the surgery with an aim to minimize complications. The procedure when performed within 72 hours post ERCP by an experienced surgeon with relevant technical modifications can lead to shorter operative times with lesser conversion rates. More studies may be needed to validate the above findings and arrive at a conclusion.

Acknowledgements

We thank the team of Doctors and nurses from the above mentioned hospitals for their kind cooperation in all our surgical work.

References

- [1]. Katkhouda N, Mavor E, Mason RJ. Visual identification of the cystic duct-CBD junction during laparoscopic cholecystectomy (visual cholangiography): an additional step for prevention of CBD injuries. *Surg Endosc* (2000) Jan;14(1):88-9.
- [2]. Reinders JS, Goud A, Timmer R. Laparoscopic cholecystectomy improves outcomes after endoscopic sphincterotomy for choledochocystolithiasis. *Gastroenterology* (2010) Jun; 138(7):2315-20. Epub 2010 Mar 2.
- [3]. Sarli L, Iusco DR, Roncoroni L. Preoperative endoscopic sphincterotomy and laparoscopic cholecystectomy for the management of cholecystocholedocholithiasis: 10-year experience. *World J Surg* (2003);27:180-186
- [4]. Boerma D, Rauws EA, Keulemans YC, et al. Wait-and-see policy or laparoscopic cholecystectomy after endoscopic sphincterotomy for bile-duct stones: a randomised trial. *Lancet* (2002) Sep 7;360(9335):761-5.
- [5]. Ishizaki Y, Miwa K, Yoshimoto J, Sugo H, Kawasaki S. Conversion of elective laparoscopic to open cholecystectomy between 1993 and 2004. *Br J Surg* (2006); 93: 987-991
- [6]. Anandi HWS, Marc GHB, Djamila B, et al. Timing of cholecystectomy after endoscopic sphincterotomy for common bile duct stones. *Surg Endosc* (2008) 22:2046-2050
- [7]. Salman B, Yilmaz U, Kerem M, et al. The timing of laparoscopic cholecystectomy after endoscopic retrograde cholangiopancreatography in cholelithiasis coexisting with choledocholithiasis. *J Hepatobil Pancreat Surg* (2009); 16:832-836
- [8]. Erdal BB, Metin E, Ilter O, et al. Timing of elective laparoscopic cholecystectomy after endoscopic retrograde cholangiopancreatography with sphincterotomy: a prospective observational study of 308 patients. *Langenbecks Arch Surg* (2010) 395:661-666
- [9]. Christos PG, Theodoros NM, Georgia CK, et al. Is inflammation a significant predictor of bile duct injury during laparoscopic cholecystectomy? *Surg Endosc* (2008) 22:1959-1964
- [10]. Metin E, Birol EB, Zafer T, et al. Predictive Factors for Conversion to Open
- [11]. Surgery in Patients Undergoing Elective Laparoscopic Cholecystectomy. *J Laparoendosc Adv Surg Tech A* (2010) 20:5; 427-34
- [12]. Vivek MK, Augustine AJ, Rao R. A comprehensive predictive scoring method for difficult laparoscopic cholecystectomy. *J Min Access Surg* (2014);10: 62-7.
- [13]. Luis CD, Aura R, Charles B, Wilmar H. Analysis of factors for conversion of laparoscopic to open cholecystectomy: a prospective study of 703 patients with acute cholecystitis. *Cir Esp* (2011); 89(5):300-306

Pre-operative Factors	No. of cases (n=56)	Operative time needed			Conversion to Open (n=8)	p value
		<1hr	1-2hr	>2hrs		
Time interval between ERCP & ES & LC						
Less than 72 hours	28	18	9	1	1	p= 0.001
72 hrs to 1 week	18	4	12	2	2	
More than 1 week	10	0	5	5	5	

Table 1: Pre-operative factors leading to difficulty & conversion.

Difficulty encountered	No. of cases (n=56)	Operative time	
		<1 hr	>1 hr
Frozen Calot's triangle	32(57.1)	12	20
Short & wide cystic duct	22(39.3)	8	14
Difficult to handle GB	36(64.3)	14	22
Lateral rent in cystic duct	8(14.3)	0	8
Cystic duct adherent to CHD (Mirizzi Syndrome)	10(17.9)	1	9
Conversion to open	8(14.3)	0	8
Bile duct injury	3(5.4)	0	3
Intra operative bleeding	6(10.7)	1	5
No difficulty	20(35.7)	20	0
Total no. of cases	56	22(39.3)	34(60.7)

Table 2: Factors associated with increased operating time.

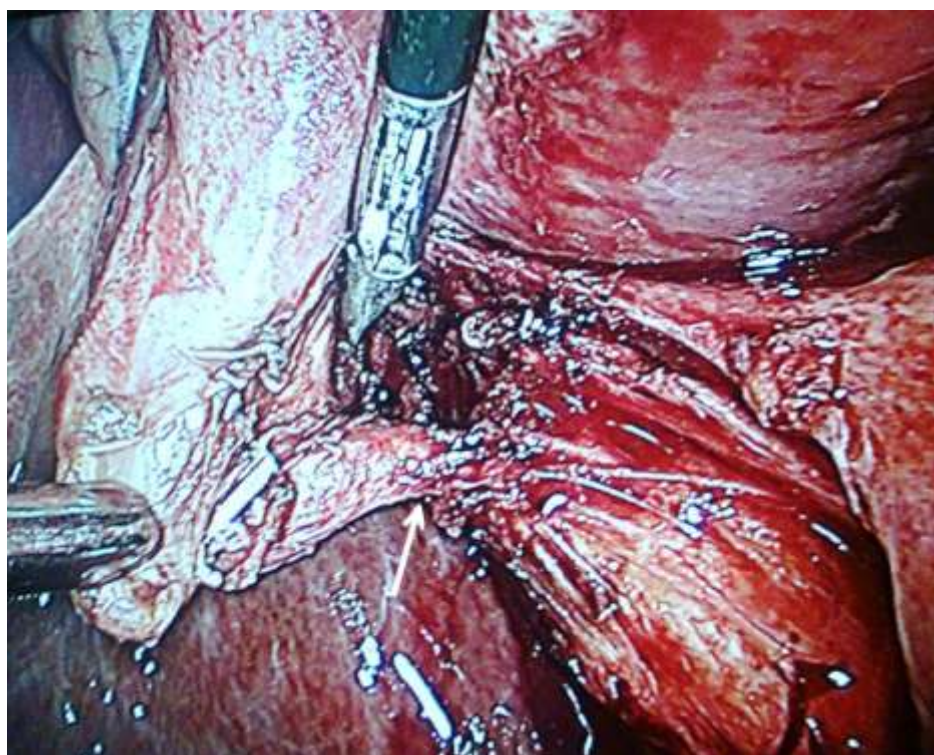


Figure 1(Original): Intra-operative picture of short & wide cystic duct (white arrow) and difficult handling

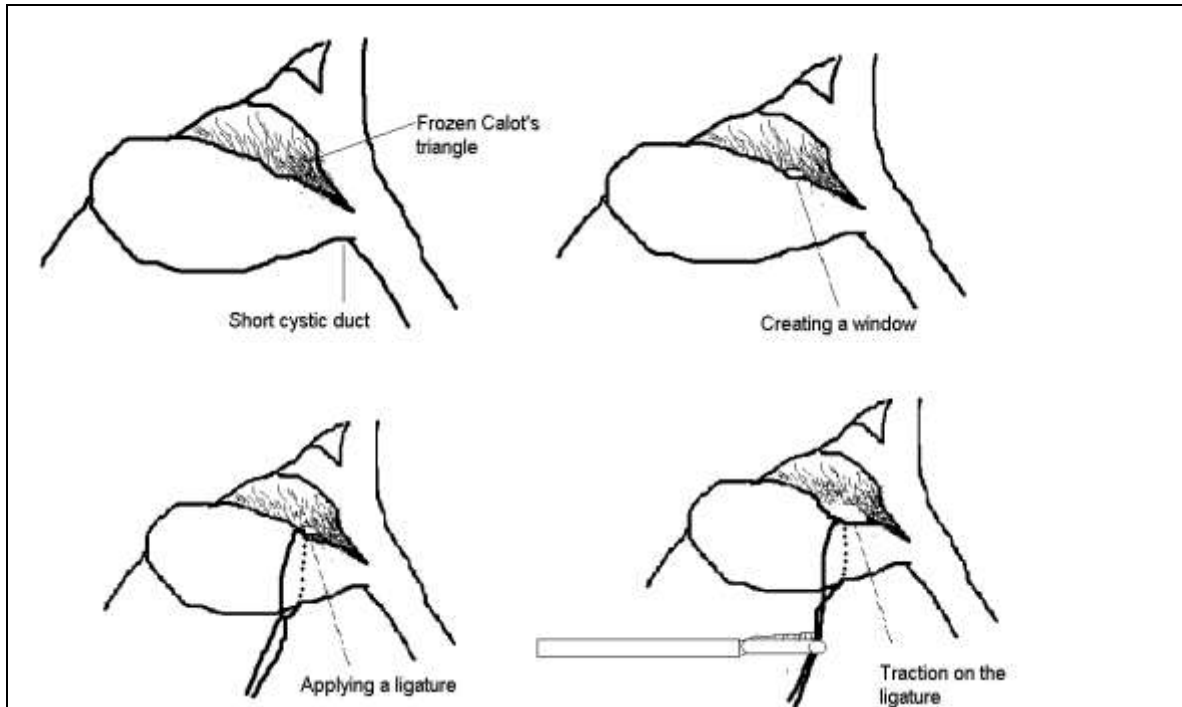


Figure 2 (Original): Diagram showing the technical modification adopted during surgery