

## Primary Mycobacteria tuberculosis following intralesional steroid

Dr. Shabab Ahmed Damji<sup>1</sup>, Dr. Deep Anurag<sup>2</sup>

---

**Abstract:** Contracting *Mycobacterium tuberculosis* exogenously through intralesional steroid injection for keloid is an unique phenomenon not so far mentioned in literature. Primary cutaneous tuberculosis developing at keloid following intralesional steroid (ILS) which is negative for routine bacterial cultures & insensitive to routine antimicrobials warrants high index of suspicion for Mycobacterial infection.

**Keywords:** Keloid, intralesional steroid, *Mycobacterium tuberculosis*.

---

### I. Introduction

*Mycobacterium* continues to haunt human beings in its different forms. Studies have shown that skin tuberculosis accounts for 0.025% of all patients with tuberculosis and nearly 15% of patients with extrapulmonary tuberculosis.<sup>[1]</sup> Incidence of nontuberculous mycobacterial infection has increased in the past two decades, especially in immunocompromised hosts.<sup>[2]</sup> Skin involvement of *Mycobacterium* has always been known for its varied clinical presentation, with many of them diagnosed years after the onset of symptoms. The occurrence of cutaneous nontuberculous mycobacterial (NTM) infections is being increasingly reported. Although most pathogenic species of NTM may cause skin and soft tissue infections, *Mycobacterium marinum*, *Mycobacterium ulcerans* and the rapidly growing mycobacteria such as *Mycobacterium fortuitum*, *Mycobacterium chelonae* and *Mycobacterium abscessus* are the most frequent causes.<sup>[1]</sup> However there is rarely any report of infection with *Mycobacterium tuberculosis* in patients of keloid following intralesional steroid injection. Cutaneous infections by NTM usually occur following contact of surgical or traumatic wounds with water or other contaminated source although cutaneous infections with *Mycobacterium tuberculosis* following surgical and traumatic wounds is very rare. Among the immunosuppressed it can occur as a consequence of a disseminated mycobacterial disease. A high index of suspicion about *Mycobacterium tuberculosis* and NTM infections is necessary, in those with chronic infections of the skin and soft tissue, to ensure prompt and appropriate treatment.<sup>[3]</sup> Abscess formation at the site of the puncture wound is most often due to rapidly growing mycobacteria. Wallace and coworkers noted that *M. fortuitum* and *M. chelonae* were the predominant isolates when they reviewed 125 cases of human infections caused by rapidly growing mycobacteria. Among these 59% had cutaneous infections following surgery, accidental trauma or needle injections.<sup>[4]</sup> We report a case of subcutaneous abscesses due to *M. tuberculosis* following intralesional steroid in a patient with keloid. Literature from our subcontinent suggests association of mycobacterial infection following yellow jacket sting and recurrent soft tissue infections.<sup>[5,6]</sup> However, we were unable to retrieve literature regarding association of keloids with *M. tuberculosis* following a PubMed search, which emphasizes the uniqueness of our report.

### II. Case Report

A 43-year-old man who is a non diabetic and non hypertensive, presented with keloid lesions of 10-years duration. He noticed that the size increased gradually over a period of time which prompted him to consult a dermatologist, who administered intralesional steroid injection given once a month for 7 months. The patient noticed progressive increase in size of the lesion followed by drainage of pus when he was referred to our facility at Dermatology OPD of School of Tropical Medicine, Calcutta. A diagnosis of pyogenic infection in a keloid was made and he was advised oral and topical antibiotics, but there was no improvement.

On examination he was afebrile and there were no palpable lymph nodes. Single keloid was observed over the manubrium, (3 × 1.5 × 1.5 cm) The lesion was associated with sinuses which was discharging pus. He had no family history of keloids. No abnormal findings were seen in his blood picture and chest X-ray. Sputum for acid-fast bacilli (AFB) and Mantoux test were negative. Serology for HIV and VDRL were non-reactive. Histopathology was not performed apprehending flaring up of keloid following punch biopsy induced trauma.

Pus was aspirated from the lesions for microbiological studies. Gram stain showed plenty of pus cells but no bacteria, while Ziehl-Neelsen stain revealed plenty of acid-fast bacilli in a background of polymorphs raising the possibility of mycobacteria. Routine bacterial culture of the pus showed growth of *Klebsiella pneumoniae* and MRSA for which he was given antibiotics according to sensitivity, but still there was no improvement. BACTEC was done which showed growth of *Mycobacterium tuberculosis* and line probe assay did not show any resistance to INH or Rifampicin. Following this Interferon Gamma Release Assay was done

which came to be positive (2.66 IU/ml). It was diagnosed as a case of cutaneous *Mycobacterium tuberculosis* in a patient of keloid.

### III. Discussion

Keloids appear spontaneously or following trauma, may expand beyond the margin of the wound, and persists for years as encountered in our case. *M. tuberculosis* is not particularly virulent, as only 5% to 10% of infections lead to clinical disease. This bacterium has a worldwide distribution; it is more prevalent in regions with a cold and humid climate but can also occur in the tropics. The incidence of cutaneous TB parallels that of pulmonary TB and is therefore seen more commonly in low-income countries and impoverished populations. *M. tuberculosis* is the predominant etiologic agent in cutaneous TB. *M. tuberculosis* is a slender, non-motile, aerobic, non-spore-forming, filamentous rod. It is an acid- and alcohol-fast bacillus that has a waxy coating with a high lipid content, which makes it resistant to degradation after phagocytosis. *M. tuberculosis* disseminates primarily via inhalation of aerosolized droplets of saliva from individuals with active disease; transmission by ingestion or inoculation can also occur. Intact skin provides an effective protective barrier against invasion of the organism, but a break in the mucocutaneous barrier can facilitate its entrance. We presume that bacilli were introduced into the keloid along with the steroid injection, which also reduced the local immunity.

Infection with mycobacterium may follow injection with contaminated needles. The infection may follow cosmetic surgery breast implantation. Post surgical infection presents with painful nodule, ulcer, abscess, sinus tract or cellulitis. Although most of these are due to non-tubercular mycobacterium (NTM), infection with *M. tuberculosis* following injection has not been reported.

<sup>[7]</sup> Steroids can cause a decrease in local immunity following injections. <sup>[8]</sup> Thus, they predispose to infection with bacteria following injections with improper antisepsis of skin, unsterilized syringe or contaminated steroid vial.

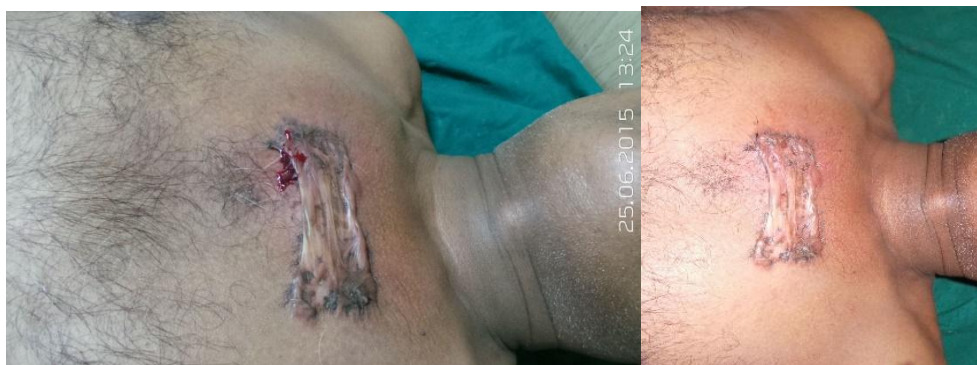
<sup>[9,10]</sup> Delayed diagnosis of cutaneous infections due to *M. tuberculosis* is a common clinical issue. Causes of delayed diagnosis are multiple and include resemblance to pyogenic infections, lack of awareness and a low index of suspicion among physicians. Some skin lesions may occur at the site of trauma, including those developing at the site of invasive diagnostic and therapeutic procedures. If they follow a chronic course and do not respond to antibiotics, a mycobacterial etiology should be considered.

### IV. Conclusion

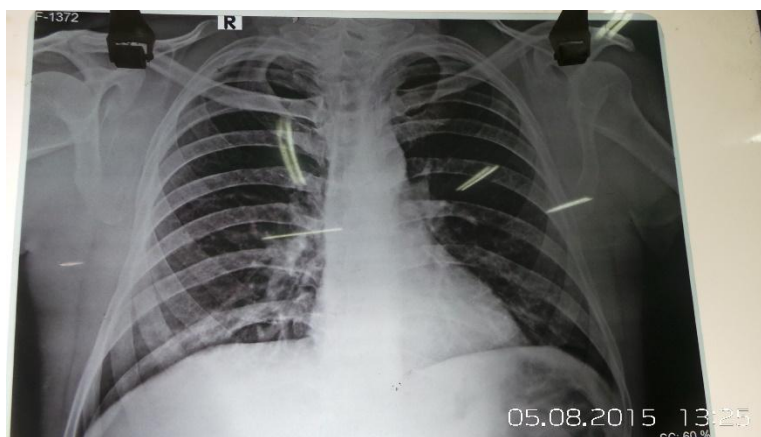
Physicians should think outside the box when faced with chronic skin lesions, as the consequence of failing to make an early diagnosis may lead to necrosis, destruction of underlying bones and cartilage. With increasing clinical use of intralesional steroids, treating physicians will probably identify more of these cases based on the awareness that this report presumably will create.

### References

- [1]. Ramam M. Cutaneous Tuberculosis. In: Sharma SK, Mohan A, editors, 2<sup>nd</sup> ed. New Delhi, India: Jaypee Brothers Medical Publishers (P) LTD; 2009. p. 384-96.
- [2]. Blackwell V. *Mycobacterium marinum* infections. *Curr Opin Infect Dis* 1999;12:181-4.
- [3]. Chen HY, Chen CY, Huang CT, Ruan SY, Chou CH, Lai CC, et al. Skin and soft-tissue infection caused by non-tuberculous mycobacteria in Taiwan, 1997-2008. *Epidemiol Infect.* 2011;139:121-9. [PubMed]
- [4]. Wallace RJ, Jr, Swenson JM, Silcox VA, Good RC, Tschen JA, Stone MS. Spectrum of disease due to rapidly growing mycobacteria. *Rev Infect Dis.* 1983;5:657-79. [PubMed]
- [5]. Singh S, Rattan A, Kumar S. Severe cutaneous *Mycobacterium chelonae* infection following a yellow jacket sting. *Tuber Lung Dis.* 1992;73:305-6. [PubMed]
- [6]. Sarma S, Thakur R. Cutaneous infection with *Mycobacterium fortuitum*: An unusual presentation. *Indian J Med Microbiol.* 2008;26:388-90. [PubMed]
- [7]. Aldabagh BA, Tomecki KJ. Cutaneous nontuberculous mycobacterial infections. *Dermatol Nurs* 2009;21:179-82, 189. [PUBMED]
- [8]. Saigal G, Donovan Post MJ, Kozic D. Thoracic intradural aspergillus abscess formation following epidural steroid injection. *AJNR Am J Neuroradiol* 2004;25:642-4. [PUBMED]
- [9]. Sehgal VN, Bhattacharya SN, Jain S, Logani K. Cutaneous tuberculosis: The evolving scenario. *Int J Dermatol.* 1994;33:97-104. [PubMed]
- [10]. Chin PW, Koh CK, Wong KT. Cutaneous tuberculosis mimicking cellulitis in an immunosuppressed patient. *Singapore Med J.* 1999;40:44-5. [PubMed]



Serosanguinous discharge at ILS site 4 wks after Anti tubercular therapy



Chest X ray PA view

INVESTIGATIONS	RESULT
MANTOUX (10 TU PPD)	ERYTHEMA 3mm X 3mm } NEGATIVE INDURATION 2 mm X 2mm }
Chest X Ray	Within normal limit
Smear from keloidal discharge for AFB	Plenty of Acid fast bacilli present
BACTEC culture of the pus from keloid	Shows growth of <i>M.tuberculosis</i>
Interferon Gamma Release Assay	2.66 IU / MI (Positive)