

## Management of partial Glossectomy patient with resorbed mandibular ridge using simplified technique- A Case Report

Dr. A. Meenakshi<sup>1</sup>, Dr. S.V.Suresh kumar<sup>2</sup>, Dr. Vinay Bharti<sup>3</sup>

<sup>1</sup>(Professor, Department of Prosthodontics, Tamil nadu Government Dental College & Hospital, Chennai, India)

<sup>2,3</sup>(Postgraduate student, Department of Prosthodontics, Tamil nadu Government Dental College & Hospital, Chennai, India)

---

**Abstract:** The objective of any prosthodontic service is to restore the patient to normal function, contour, esthetics, speech and health. An optimum denture stability is difficult to achieve in conventional complete dentures especially in case of extremely resorbed mandibular ridges. Often patients with oral carcinomas have resection of the tongue, the floor of the mouth or the bone of the mandible. Post operatively, these patients encounter chewing, swallowing and speech problems. When both partial glossectomy and resorbed mandibular ridge are encountered together, oral rehabilitation of such patients is a challenge to the clinician. This case report describes management of 65yr old male patient with partial glossectomy and resorbed mandibular ridge using neutral zone technique.

**Keywords:** Partial glossectomy, Resorbed mandibular ridge, Oral Rehabilitation.

---

### I. Introduction:

Construction of complete dentures for patients with normal and well formed residual alveolar ridges can be done following the conventional techniques. An optimum denture stability is difficult to achieve in conventional complete dentures especially in case of extremely resorbed mandibular ridges.

Squamous cell carcinoma is one of the conditions in which surgical removal of the involved part becomes mandatory. Therefore patient has to undergo series of surgeries, which involves resection of hard and soft tissues. When less than 50% of the tongue portion is removed it is known as partial glossectomy. Often patients encounter problems in speech, mastication and swallowing after partial glossectomy. Many challenges are encountered when constructing complete dentures for these patients, which include difficulty in impression making, difficulty in stabilizing record bases, difficulty in speech and mastication, reduced surface area and hence reduced support and inadequate peripheral seal.

Treatment options :Management of such patients include surgical and non-surgical procedures. Surgical options like vestibuloplasty, ridge augmentation and implant supported dentures could be possible. Non surgical options include conventional complete dentures, dentures made with neutral zone concept, hollow dentures if adequate interarch space exists, liquid supported dentures and multicup dentures which reduce further resorption of residual ridge and to Increase the retention of the denture respectively.

### II. Case report:

A 65 yr old man reported to the department of prosthodontics, government dental college and hospital, Chennai {india} with a chief complaint of loose denture and inability to chew and difficulty in speech. He was edentulous since 2 years and he was a denture wearer since 1 year. His medical history revealed that he underwent surgery 3 years before for carcinoma of tongue.

Extraoral examination showed facial asymmetry in the lower half of the face with sunken cheek on the left side. The right half of the lower lip was everted giving a palsic appearance.

Intraoral examination revealed resected left half of the tongue extending from the tip of the tongue posteriorly upto the retromylohyoid region. Obliterated alveololingual sulcus in the left side with no sulcus depth. The maxillary residual ridge was favourable but the mandibular residual ridge was unfavourable due to extreme resorption.

Several treatment options were presented to the patient to develop functional and esthetic complete denture. The patient declined surgical procedures involving vestibuloplasty and implant therapy. Hence a conventional complete denture with neutral zone technique was planned to increase the stability of the lower complete denture and to improve the phonetics and esthetics.

### III. Neutral zone concept:

It is an area or position in an edentulous mouth where during function the forces of the tongue pressing outward are neutralized by the forces of the cheek and lips pressing inward. The central thesis of the neutral zone approach to complete dentures is to locate that area in the edentulous mouth where the teeth should be

positioned so that the forces exerted by the muscles will tend to stabilize the denture rather than unseat it. This concept was first described by sir Wilfred fish in 1931. He also described how dentures should be constructed in the dead space.

The aim of the neutral zone is to construct a denture in muscle balance. This is the zone where the natural dentition exists.

### **3.1 Materials used for recording neutral zone:**

Various materials have been used to record neutral zone impression. Each has its own advantages and disadvantages. These include impression plaster, impression waxes, impression compound, regular bodied silicone, tissue conditioner, polyether, hard relining material. Because of easy availability, good handling properties, extended working time, impression compound has been used in this patient to record the neutral zone.

### **3.2 Procedure:**

- 1- Primary impression of the maxillary and mandibular edentulous ridges were made with irreversible hydrocolloid impression material. Soon after making primary impression, the impression was poured with plaster of paris and primary casts were prepared. The custom trays were fabricated with self cure resin over the primary casts keeping the borders 2mm short of the sulcus.
- 2- The borders of the trays were molded with green stick impression compound and the secondary impressions were made with zinc oxide eugenol impression material. The master casts were poured in dental stone.
- 3- The master cast was duplicated and a permanent record base was prepared in order to increase the stability and retention of the record bases during recording the neutral zone. Permanent record bases were prepared in heat cure resin.
- 4- Wax occlusal rims were made over the permanent record bases for recording the jaw relation. Centric jaw relation was recorded using standardized niswongers method. Vertical dimension at occlusion and rest position were established with 4mms of freeway space. The models with occlusal rims were articulated in mean value articulator.

### **3.3 Neutral zone recording:**

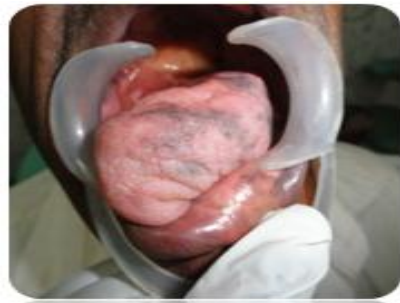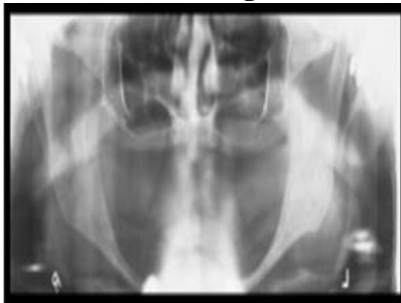
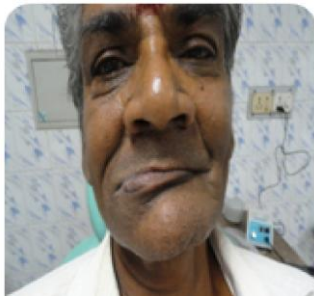
The wax from the lower occlusal rim was removed. Apply hot red modeling impression compound to the record base to facilitate adhesion of the rim. In a waterbath set to 140f warm the compound, knead the material thoroughly and adapt it to the record base, forming a recording rim. Seal the edges of the recording rim to the record base using a heated spatula. Place the completed record base and recording rim in the water bath for approximately 2 minutes in preparation for the procedure. Avoid using the maxillary occlusal rim during clinical registration of the mandibular neutral zone as to avoid occlusal and movement interferences.

Remove the base and rim from the waterbath and quickly place intraorally. Instruct the patient to do functional movements by asking the patient to talk, whistle and pursing the lips. Provide a cup of warm water to the patient and instruct the patient to sip and swallow , have the patient repeat the exercise several times. Now the compound has been molded according to the muscle movements. When the record has cooled and hardened ,remove and inspect the record for accuracy and completeness. If necessary repeat the procedure to ensure proper recording of the entire neutral zone.

- 5- The record base with compound is placed back in the articulator with the upper occlusal rim. Now, the articulator is closed and ensure that the straight pin touches the table. If it is raised try scraping the excess material from the occlusal surface of the impression compound until the pin touches the table. Always ensure the exact height of the occlusal rim hence neutral zone varies according to varying height.
- 6- next step was to make plaster indices surrounding the neutral zone impression. V shaped notches were made on the mandibular cast in order to guide the placement and removal of plaster indices properly. Then the impression compound was removed from the mandibular record base. The empty space which exists is the neutral zone space. Molten wax was made to flow in this space, to create a rim for setting the teeth.
- 7- According to the neutral zone recorded, the mandibular teeth were arranged and in accordance with this maxillary teeth arranged. Each time when teeth were set, the plaster index was placed repeatedly to ensure the proper placement of the mandibular teeth within that zone.
- 8- try in was done in order to evaluate the stability, esthetics and occlusion intraorally. Then the dentures were processed by compression moulding technique.
- 9- denture insertion was done and again it was evaluated for stability, esthetics and occlusion. Results were found to be satisfactory and patient was also satisfied with the denture. Patient was recalled after 24hrs, he had no specific complaints.

10- Monthly interval two recall visit had been done. The phonetics of the patient was much improved and the facial asymmetry of the lower half of the face showed significant improvement. The masticatory ability of the patient was also greatly enhanced.

**IV. Figures:**



**Showing facial Asymmetry OPG showing resorbed mandibular ridge Intra oral view showing resected tongue**



**Upper cast**



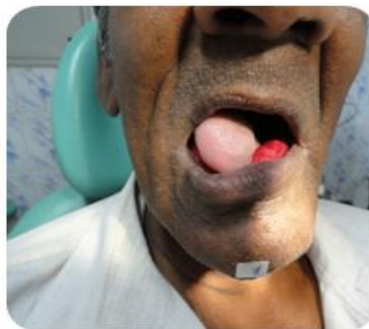**Lower cast**



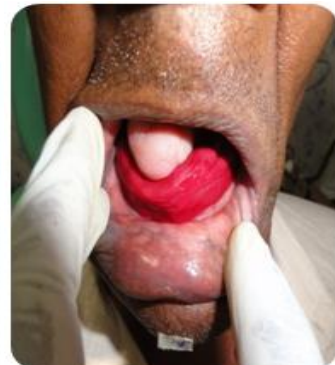**Vertical jaw relation record**



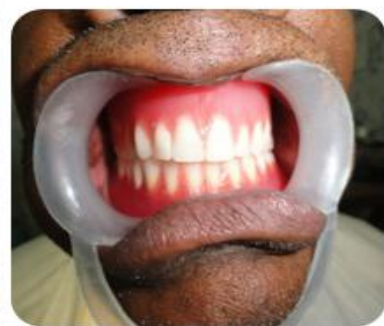**Articulation in Mean value Articulator**



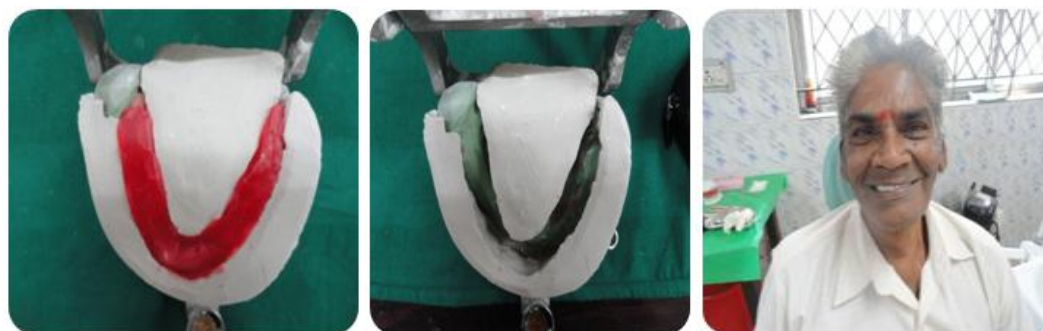**Neutral zone recording**



**Articulation with neutral zone.**



**Wax tryin**



**Plaster indices**

**Denture insertion.**



**Preoperative**

**Postoperative**

### **V. Conclusion**

The neutral zone philosophy is based upon the concept that for each individual patient, there exists within the denture space a specific area where the function of the musculature will not unseat the denture and when forces generated by the tongue are neutralized by the lips and cheeks. It is one of the best alternative techniques in case of highly atrophic mandibular ridge and in this case it also improves phonetics of the patient by coordinating the tongue movement in accordance with the lips and cheeks. Many complete denture failures are often related to noncompliance with neutral zone factors. Thus neutral zone must be evaluated as an important factor during complete denture construction especially in situations of extremely resorbed mandibular ridge and in neuromuscular dysfunctions.

### **References**

- [1]. The neutral zone in complete dentures and partial dentures- victor E beresin Frank.j.schiesser
- [2]. the neutral zone revisited-jpd 2009;101:405-412 david R.cagna, joseph j.massad
- [3]. j.indian prosthodontic society- 2010 june:10[2]
- [4]. enhancement of stability for mandibular complete denture- j advanced dental research, viraj patil, RB hallikcrimmah
- [5]. payne AG Factors influencing the position of artificial upper anterior teeth. J prosthet dent 1971;26:26-32
- [6]. Gupta KL, Agarwal S ,Salvation of a severely resorbed mandibular ridge with a neutral zone technique. [Journal Article]Indian J Dent Res 2011 Nov-Dec; 22(6):883.