

## Platelet Rich Plasma Injection Compared To Corticosteroid Injection in the Treatment of Chronic Plantar Fasciitis

Dr.Sandesh Reddy Yaratapalli<sup>1</sup>, Prof. Jambu Nageswaran<sup>2</sup>,  
Prof.Samuel Chittaranjan.B<sup>3</sup>

<sup>1</sup>(Department of Orthopaedics, Sri ramachandra University, India)

<sup>2</sup>(Department of Orthopaedics, Sri ramachandra University, India)

---

**Abstract:** To Compare The Efficacy Of Patients Treated With Platelet Rich Plasma Vs Corticosteroid Injection In Chronic Plantar Fasciitis. This is a prospective cohort study and a total of 110 patients were studied. They were divided into group-A(PRP injection) and group-B(Corticosteroid injection). All patients were diagnosed as plantar fasciitis by clinical and radiological evaluation. Group-A(60 patients) were given PRP injection and Group-B(50 patients) were given Corticosteroid injection. 6 cases lost in follow up were excluded from the study. Patients were assessed functionally using VAS and FAOS scores and radiologically by Ultrasound of the foot and X-ray lateral view of the foot. The PRP and Corticosteroid injection groups at the initial visit had VAS of 6.85 and 6.95 respectively which was reduced to 1.80 and 2.82 at the end of 6 months. The PRP and Corticosteroid injection groups at the initial visit had FAOS of 32.8 and 34.1 respectively which increased to 86.93 and 81.18 at the end of 6 months. On sonographic evaluation the plantar fascia thickness in PRP and Corticosteroid group are at the same baseline prior to injection. After injection the PRP group had significant reduction(36.45%) in the thickness of plantar fascia as compared to Corticosteroid group(28.33%). Chronic heel pain is a difficult condition to treat and takes a long time to resolve. Our study has shown that local Corticosteroid injection is effective for immediate pain relief which may last upto 3months. We have established the efficacy of our method of extracting PRP from peripheral blood by low spin technique. Our study has shown that PRP injection is effective long term treatment for chronic heel pain with no side effects. Further study needs to be done to see the effects of combined Corticosteroid and PRP injection for chronic heel pain.

**Key words:** corticosteroid, foot and ankle outcome score(FAOS), plantar fasciitis, platelet rich plasma(PRP), visual analog pain score(VAS)

---

### I. Introduction

Plantar fasciitis is one of the most common cause of heel pain. It is thought to result from chronic overload and is characterized by pain at the calcaneal origin of the plantar fascia, exacerbated by weight bearing after prolonged periods of rest. **Diagnosis** of plantar fasciitis warrants a thorough clinical history and physical examination. It usually presents with a sharp morning heel pain and first-step pain that improves with normal use during day and worsens with heavy use. **Physical examination** is marked by localized tenderness at the medial tubercle of the calcaneus, loss of ankle dorsiflexion due to gastrocnemius muscle or Achilles tendon tightness, and in more severe cases, increased heel discomfort with passive toe dorsiflexion. Critical reviews of **Cortisone injection therapy** have yielded equivocal short-term results and disappointing long-term results. Potentially disabling complications have also been reported, such as rupture of the plantar fascia. Early success in using the PRP to treat chronic refractory tendinopathy has led to consideration for its use in the management of recalcitrant cases of plantar fasciitis. **PRP**, the plasma fraction of the autologous blood having a platelet concentration above baseline, contains various growth factors that have been found to be involved in a host of biosynthetic pathways<sup>10</sup>. By injecting a aliquot of concentrated platelet enriched plasma into a localized area, the various growth factors are thought to jumpstart the regenerative process in degenerative conditions. Earlier results of using the PRP to treat plantar fasciitis have been favorable but there is no study, which shows its comparable effectiveness to other agents. In this study we have tried to compare the efficacy of the patients treated with PRP and hydrocortisone injection<sup>11,12</sup>.

### II. Aim Of The Study:

To Compare The Efficacy Of Patients Treated With Platelet Rich Plasma Vs Corticosteroid Injection In Chronic Plantar Fasciitis

### III. Materials And Methods:

Study was done in Sri Ramachandra Medical Centre, Done between June 2012 – October 2014. This is a prospective cohort study and a total of 110 patients were studied. They were divided into group-A(PRP

injection) and group-B(Corticosteroid injection). All patients were diagnosed as plantar fasciitis by clinical and radiological evaluation. Group-A(60 patients) were given PRP injection – ( 45 females, 15 males ). Platelet count in blood and PRP was estimated randomly for some samples (undergoing PRP injection). Group-B(50 patients) were given Corticosteroid injection – ( 36 females, 14 males ).

### **3.1: Technique:**

#### **Platelet Rich Plasma Preparation:**

We adopted a PRP (low spin) technique for platelet rich plasma preparation<sup>12</sup>(by Augustus D. Mazzocca et al. in 2012,JBJS).

#### **Prp Injection Technique:**

- Patient in supine position, involved foot is identified. The site of maximal tenderness i.e medial aspect of the foot at the origin of plantar fascia usually is marked using a marker. 3ml of sensocaine is infiltrated into the skin and subcutaneous tissue. Later 3ml of PRP is injected using 22G wide bore needle in a fan shaped fashion, a technique called peppering. Post injection, patients are rested for 15min and then allowed to walk. This technique(peppering) of PRP injection was based on the studies by Mark W. Scioli MD<sup>3</sup>, Joost C Peerbooms et al<sup>6</sup>. patients are adviced to avoid strenous activities and rest for 2 weeks. They are reviewed after four weeks second injection of PRP and the same procedure is followed. 0.5ml of the PRP solution is sent for platelet count estimation in the sample.

#### **Corticosteroid Injection Technique:**

- Patient is similarly positioned and prepared like above. 3ml of sensocaine is injected and anesthetised, followed by injection of 40mg Depo-medrol solution. Only single injection of Corticosteroid is given at initial visit.

**Patients who had received PRP injection are given a second dose after 4 weeks after follow-up evaluation using VAS and FAOS scores. Patients who had received Corticosteroid injection, only follow-up evaluation is done using VAS and FAOS at 4 weeks.** Two injections of PRP are given because studies by **Nicolo Martinelli et al<sup>13</sup>**, **Martin J. O'Malley<sup>7</sup>**, MD suggest a minimum of two injections. Patients are followed up at 8 weeks, 12 weeks and 6 months.VAS and FAOS score outcomes are compared with previous visits at each follow-up.

## **IV. Results:**

### **4.1: Visual Analog Score (Vas):**

The PRP and Corticosteroid injection groups at the initial visit had VAS of 6.85 and 6.95 respectively. On injection of PRP and Corticosteroid in respective groups, 4 weeks evaluation of VAS showed a significant decrease in Corticosteroid group as compared to PRP group. At the end of 8 weeks the VAS decreased significantly in Corticosteroid group compared to PRP group.

At the end of 3 months, the VAS decreased significantly in Corticosteroid group as compared to PRP group. At the end of 6 months, the PRP group showed significant reduction in VAS compared to Corticosteroid group. This shows that Corticosteroid is more effective for short term relief and PRP is more effective for long term relief.

### **4.2: Foot And Ankle Outcome Score (Faos):**

The PRP and Corticosteroid injection groups at the initial visit had FAOS of 32.8 and 34.1 respectively. On injection of PRP and Corticosteroid in respective groups, 4 weeks evaluation of FAOS showed a significant increase in Corticosteroid group as compared to PRP group. At the end of 8 weeks the FAOS increased significantly in Corticosteroid group compared to PRP group.

At the end of 3 months, the FAOS increased significantly in Corticosteroid group as compared to PRP group. At the end of 6 months, the PRP group showed significant increase in FAOS compared to Corticosteroid group. This shows that Corticosteroid is more effective for short term relief and PRP is more effective for long term relief.

### **4.3: Sonographic Evaluation:**

On sonographic evaluation the PRP group and Corticosteroid group are at the same baseline prior to injection. After injection the PRP group had significant reduction(36.45%) in the thickness of plantar fascia as compared to Corticosteroid group(28.33%). The post treatment sonographic evaluation was done after 6 months following injection.

**4.4: Recurrence:**

**7 patients(8.5%)** in PRP group(among 60 patients) and **5patients(10%)** in Corticosteroid group(among 50 patients) reportedly were in pain with some loss of function at 6 months follow-up, typically **VAS from 2→4** and **FAOS 70.6→54.2** on an average.

**V. Discussion:**

Chronic heel pain is a difficult condition to treat. Traditionally it has been treated by Physiotherapy, use of soft heel foot wear and local Corticosteroid injections. It is well known that pain does not subside quickly, but can persist for several weeks and this results in significant disability. There are reports in literature that injection of PRP may be effective in this condition.

Researchers like **Lee et al, Barrett et al, Martin.J.O'malley et al** have done studies using PRP in the treatment of plantar fasciitis and also comparing the effectiveness of PRP and Corticosteroid injections. Therefore we decided to do this study comparing local Corticosteroid with PRP injection.

The method of PRP preparation was based on a study by **Augustus D. Mazzocca et al<sup>12</sup>**, in 2012 (JBJS) who showed that PRP lp(low spin) method showed a higher growth factor levels and higher platelet counts in the sample. Hence this method was adopted.

The technique of PRP injection(peppering) was based on the studies by **Mark W. Scioli MD<sup>3</sup>, Joost C Peerbooms et al<sup>6</sup>**, which found this method to be very effective.

Earlier **Lee et al<sup>16</sup>**, conducted prospective randomised, controlled study of 64 patients for a period of 6 months by comparing PRP with corticosteroid injection. The authors found that there is significant reduction in VAS for both the groups over a time. At 6 weeks and 3 months, the corticosteroid group had significantly lower VAS than the PRP group, but the difference was not significant at 6 months. But in our study, we found a significant reduction in VAS score at 4 weeks, 6 weeks and 3 months with corticosteroid group, whereas at 6 months there was significant reduction in VAS with PRP group compared to corticosteroid group.

In a similar study, **Barrett et al<sup>17</sup>**, applied single injection of PRP in 9 patients and reported 78% symptomatic relief for a short term follow up of 2 months. However direct comparison with our study is difficult because of less sample size, shorter duration of follow up, single injection and different methodology.

In another retrospective review of 23 consecutive patients treated with PRP by **Martin J.O'malley et al<sup>7</sup>**, showed that the mean VAS score improved from 7 to 4. But our study in contrast showed reduction in VAS from 6.9 to 1.8. In Martin J.O'malley et al. study FAOS scores improved from 57 to 70, whereas in our study it improved from 33 to 87.

In a similar study by **Mukesh Tiwari et al<sup>1</sup>**, the VAS score significantly reduced in both PRP and corticosteroid groups at one month, but at 3 months following treatment it increased in corticosteroid group and remained constant in PRP group till 6 months. In contrast, our study showed a lower VAS scores with corticosteroid till 3 months and with PRP at the end of 6 months. In our study, we observed significant reduction in pain. We noticed that Corticosteroid group had very good immediate response better than the PRP group. However by 6 months, the PRP group had better results (P value significant).

Similarly in our study, we evaluated the thickness of plantar fascia pre-injection and post-injection at 6 months which showed a significant reduction in plantar fascial thickness with PRP compared to Corticosteroid at 6 months(P value significant).

**VI. Tables:**

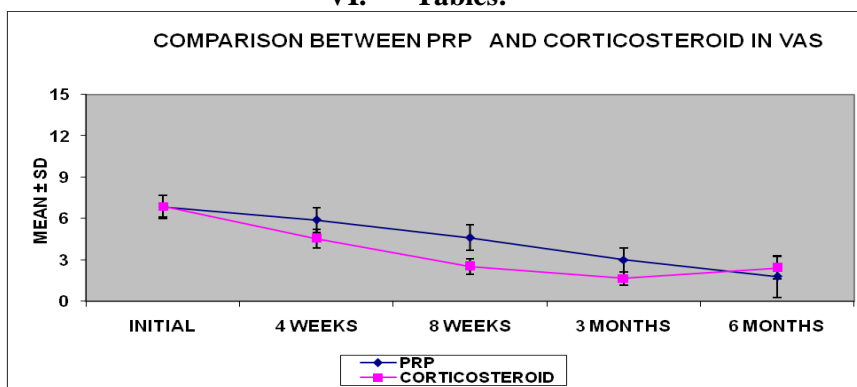


Table 1: graph depicting VAS scores at various intervals following PRP and Corticosteroid injection

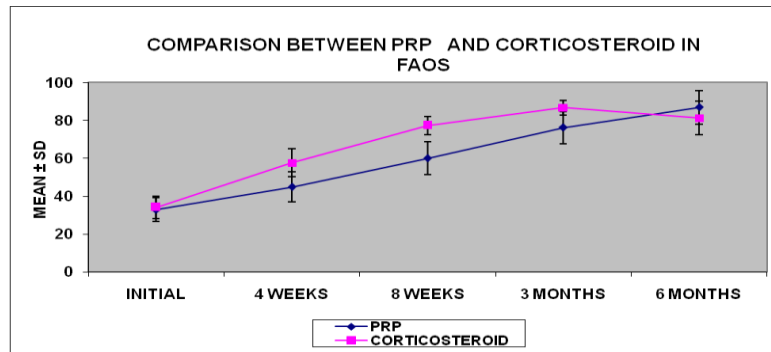


Table 2: graphical representation of FAOS at various intervals following PRP and Corticosteroid injection

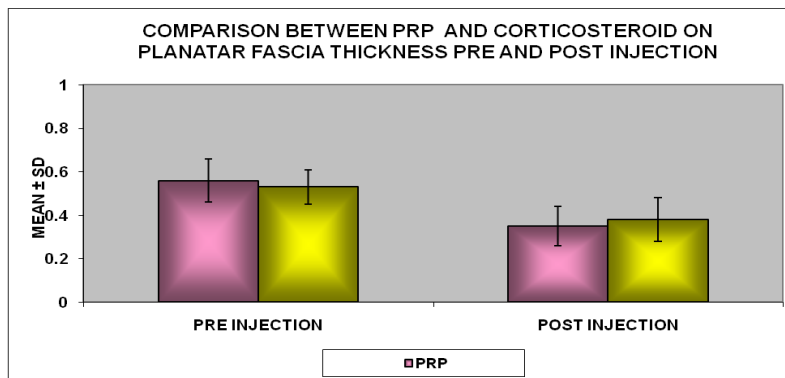


Table 3: diagram showing the mean pre and post injection(6 months) USG thickness of plantar fascia following PRP and Corticosteroid injection

## VII. Figures:

### CASE 1: PRP injection

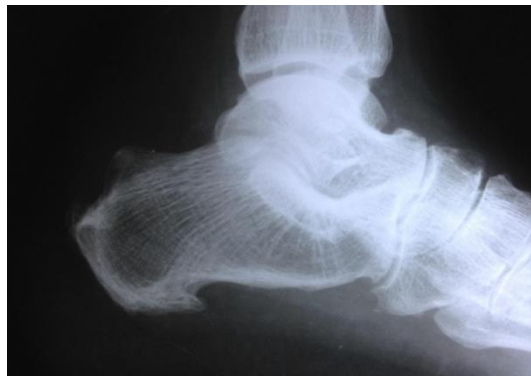

Figure 1.1: lateral radiograph of foot showing a calcaneal spur

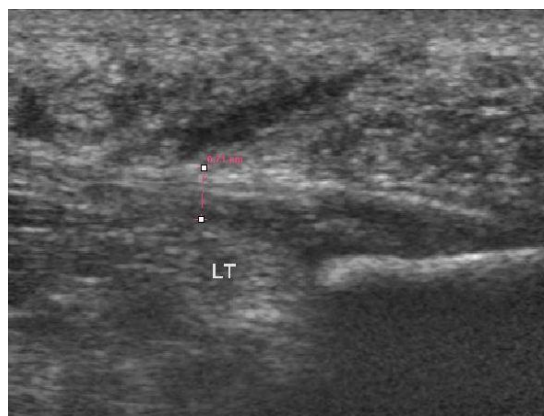


Figure 1.2: pre-injection USG of left heel showing thickened plantar fascia(0.71cm) and surrounding edema

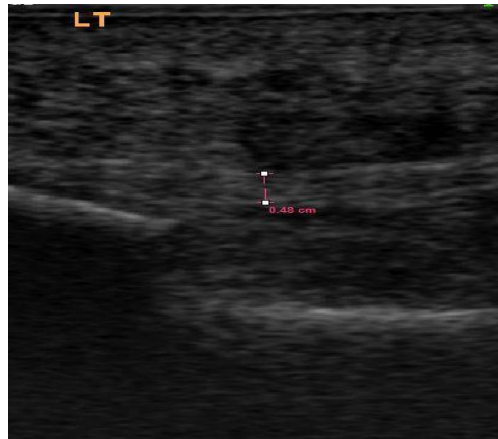

Figure 1.3: post-injection USG of left heel showing reduction in the thickness of plantar fascia(0.48cm) at 6 months

**CASE 2: Corticosteroid injection**

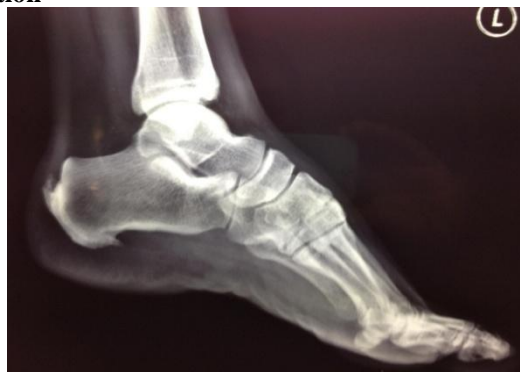

Figure 2.1: x ray left foot showing a calcaneal spur

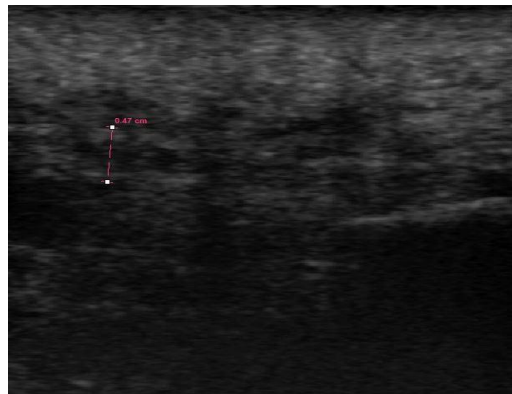


Figure 2.2: pre-injection USG of left heel showing thickened plantar fascia(0.47cm) and surrounding edema

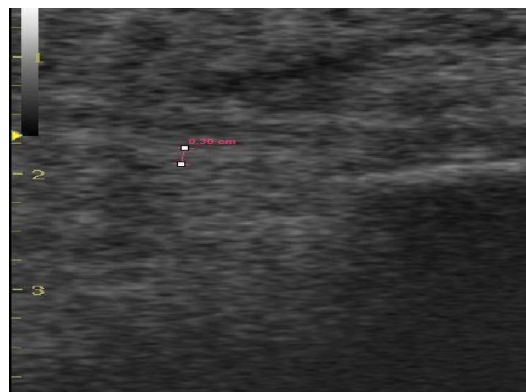


Figure 2.3: post-injection USG of left heel showing reduction in the thickness of plantar fascia(0.30) at 6 months

## VIII. Conclusion

Chronic heel pain is a difficult condition to treat and takes a long time to resolve. Our study has shown that local Corticosteroid injection is effective for immediate pain relief which may last upto 3months. Our study has established the efficacy of our method of extracting PRP from peripheral blood by low spin technique. Our study has shown that PRP injection is effective long term treatment for chronic heel pain with no side effects. Further study needs to be done to see the effects of combined Corticosteroid and PRP injection for chronic heel pain.

## References:

- [1]. Tiwari M, Bhargava R. Platelet rich plasma therapy: A comparative effective therapy with promising results in plantar fasciitis. *Journal of Clinical Orthopaedics and Trauma*. 2013;4(1):31-5.
- [2]. Thing J, Maruthappu M, Rogers J. Diagnosis and management of plantar fasciitis in primary care. *British Journal of General Practice*. 2012;62(601):443-4.
- [3]. Scioli MW. Platelet-rich plasma injection for proximal plantar fasciitis. *Techniques in Foot & Ankle Surgery*. 2011;10(1):7-10.
- [4]. Schwartz EN, Su J. Plantar Fasciitis: A Concise Review. *The Permanente Journal*. 2014;18(1):e105.
- [5]. Sabir N, Demirlenk S, Yagci B, Karabulut N, Cubukcu S. Clinical utility of sonography in diagnosing plantar fasciitis. *Journal of ultrasound in medicine*. 2005;24(8):1041-8.
- [6]. Peerbooms JC, van Laar W, Faber F, Schuller HM, van der Hoeven H, Gosens T. Use of platelet rich plasma to treat plantar fasciitis: design of a multi centre randomized controlled trial. *BMC Musculoskelet Disord*. 2010;11:69.
- [7]. O'Malley MJ, Vosseller JT, Gu Y. Successful Use of Platelet-Rich Plasma for Chronic Plantar Fasciitis. *HSS Journal*. 2013;9(2):129-33.
- [8]. Monto RR. Platelet-Rich Plasma Efficacy Versus Corticosteroid Injection Treatment for Chronic Severe Plantar Fasciitis. *Foot & Ankle International*. 2014;35(4):313-8.
- [9]. Monto RR. Platelet-rich plasma and plantar fasciitis. *Sports medicine and arthroscopy review*. 2013;21(4):220-4.
- [10]. Monto R. Platelet-rich plasma is more effective than cortisone for chronic plantar fasciitis. *Journal of Bone & Joint Surgery, British Volume*. 2012;94(SUPP XXXIX):55-.
- [11]. McMillan AM, Landorf KB, Gilheany MF, Bird AR, Morrow AD, Menz HB. Ultrasound guided corticosteroid injection for plantar fasciitis: randomised controlled trial. *BMJ: British Medical Journal*. 2012;344.
- [12]. Mazzocca AD, McCarthy MBR, Chowanec DM, Cote MP, Romeo AA, Bradley JP, et al. Platelet-rich plasma differs according to preparation method and human variability. *The Journal of Bone & Joint Surgery*. 2012;94(4):308-16.
- [13]. Martinelli N, Marinozzi A, Carni S, Trovato U, Bianchi A, Denaro V. Platelet-rich plasma injections for chronic plantar fasciitis. *International orthopaedics*. 2013;37(5):839-42.
- [14]. Cutts S, Obi N, Pasapula C, Chan W. Plantar fasciitis. *Annals of the Royal College of Surgeons of England*. 2012;94(8):539.
- [15]. Cardinal E, Chhem RK, Beauregard CG, Aubin B, Pelletier M. Plantar fasciitis: sonographic evaluation. *Radiology*. 1996;201(1):257-9.
- [16]. Lee TG, Ahmad TS. Intralesional autologous blood injection compared to corticosteroid injection for treatment of chronic plantar fasciitis. A prospective, randomized, controlled trial. *Foot Ankle Int*. 2007;28(9):984-990.
- [17]. Barret S, Erredge S. Growth factors for chronic plantar fasciitis. *Podiatry Today*. 2004;17:37-42.
- [18]. Aziza Sayed Omar, Maha Emad Ibrahim, Amal Sayed Ahmed, Mahmoud Said. Local injection of PRP and corticosteroid in treatment of lateral epicondylitis and plantar fasciitis. Randomized clinical trial. *The Egyptian Rheumatologist Journal*. 2012;34:43-49.
- [19]. Eugene G. McNally, Shilpa Shetty. Plantar Fascia: Imaging Diagnosis and Guided Treatment. *Seminar in musculoskeletal radiology*. 2010;14(3):334-343.
- [20]. Michelle Wright. Plantar Fasciitis, EMIS, patient.co.uk. peer review article. 2012.