

Giant retroperitoneal lipoma presenting as ovarian tumour-the diagnostic dilemma :case report

Mehboob Alam Pasha¹, Faiz Ahmed Mukriz², Nik Ahmad Zuky³

^{1,2}Department of Surgery, School of Medical Sciences, Universiti Sains Malaysia, Kubang Kerian, Malaysia

³Department of Obstetrics and Gynaecology, School of Medical Sciences, University Sains Malaysia, Kubang Kerian, Malaysia

Abstract:

Background-Retroperitoneal lipoma is a rare benign tumour forming 2.9% of all retroperitoneal tumours . About 80% of all Retroperitoneal tumours are malignant

Case Presentation : We present the case of a 32 year old Malay female with a giant retroperitoneal lipoma measuring 20x20cm. and weighing 3.36Kg. The mass had progressively increased in size and she had only minimal discomfort .A preoperative presumption of mature ovarian cystic teratoma was made based on clinical and imaging study. On exploration the uterus and both ovaries were normal. A giant retroperitoneal lipoma was found to be responsible for the abdominal mass. It was excised entirely and histologically confirmed later.

Conclusion: Retroperitoneal lipoma though rare should be entertained in the differential diagnosis of gynaecological pelvic masses. Imaging studies can be misleading. Complete excision is the norm .

Key Words: Difficult diagnosis, Ovarian mature cystic teratoma, retroperitoneal lipoma, resection

I. Introduction

Lipomas are benign tumours composed of mature adipocytes [1]. While commonly found in the superficial areas of extremities and trunk , their presence in the retroperitoneal mesenchymal space is considered to be extremely rare[2]. Since 80% of all primary retroperitoneal tumours are considered to be malignant, the diagnosis of lipoma in this region should be made with caution and confirmed microscopically[3]. Sizes greater than 10 cm diameter or weight greater than 1 kg. are considered to be giant lipomas[4]. Giant retroperitoneal lipomas are known to produce difficulties in diagnosis and management [5]. Besides ,retroperitoneal lipoma can be confused morphologically with well differentiated liposarcomas, which are four times more common ,and also malignant [1]. Many instances of retroperitoneal liposarcomas presenting as ovarian tumours have been reported [6,7]. However there are very few reports of benign retroperitoneal lipomas manifesting as ovarian tumour[8]. We present the case of a 32 year old Malay female with a giant retroperitoneal lipoma who initially presented to the Gynaecological Department as Ovarian cystic teratoma.

II. Case Presentation

32 year old Malay female , gravida I, presented to the O and G Department with a mass per abdomen which had progressively increased in size over the past 3 years . Except for abdominal discomfort and low back ache, she did not have any other symptoms. Her 4 year old daughter had been delivered vaginally at full term . Subsequent menstrual history was regular. There was no history of malignancy in the family. On examination the abdomen was grossly distended, more prominent over the right side. A well circumscribed 20x20 cm sized firm , nontender , mass occupied the right flank, extending across the midline ,and into the epigastrium and upto the pubis. It was mobile vertically and transversely. Rest of the abdomen was soft. Pelvic examination showed a mobile ,cystic adnexal mass ,nontender, not fixed to the cervix. **Abdominal ultrasound (Fig.1)** showed a huge heterogeneous hyperechoic mass 264.5x216.5 mm occupying the entire right side of the abdomen and encroaching on the left. Superiorly it extends to the epigastrium and inferiorly into the pelvis.. There was no obvious calcification or cystic area, no increased vascularity. Ovaries were not visualised and the mass did not appear to arise from the uterus which appeared homogeneous. The mass displaced the liver upwards and the right kidney superolaterally. Mild hydronephrosis of right kidney noted .IVC was compressed by the mass but still patent. Bowel loops were displaced to the left. No ascites noted. Impression : Large intraabdominal mass – for further CECT examination.

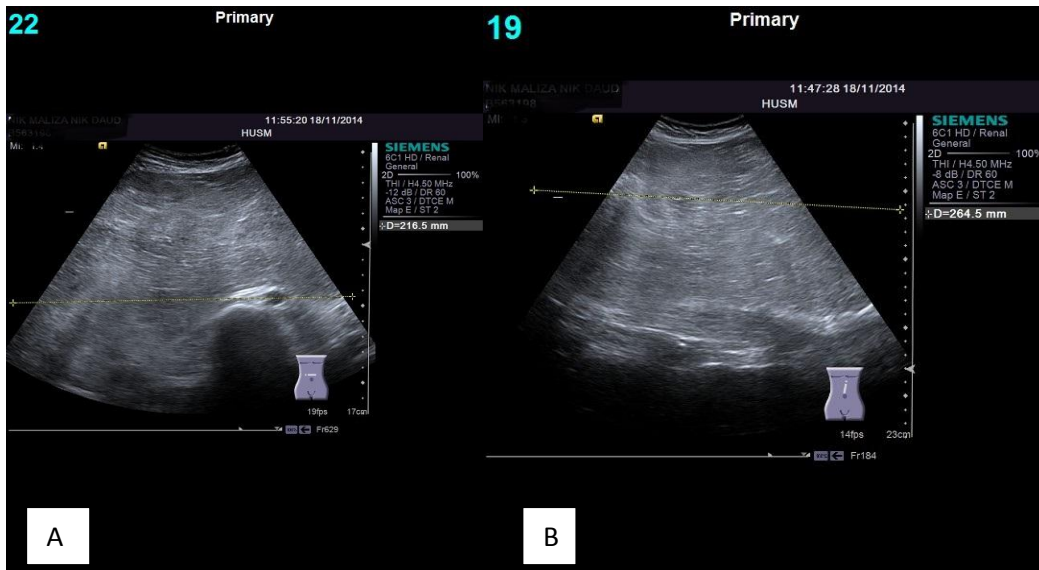


Figure 1. Abdominal Ultrasound A. Transverse and B. Sagittal, showing huge solid hyperechoic mass

Contrast Enhanced Computerised Tomography (CECT) : demonstrated a large multiseptated mass occupying the pelvic and abdominal region measuring 12.5cm(AP) x19.20cm(W)x22.7cm(CC), containing predominantly fatty soft tissue density with calcification at posteroinferior wall, Septae in the superior aspect though thickened were non enhancing . Right ovary was seen pushed superiorly and lying adjacent to the mass with lost plane of demarcation. Right ureter was compressed with mild hydronephrosis of the right kidney. Left kidney was normal.. IVC appeared to be compressed but patent. . Uterus and left ovary were normal. (Fig.2)

Based on the clinical and imaging study, a possible diagnosis of mature teratoma of the right ovary was made. Tumour markers CA-125, CEA, LDH, alpha FP were within normal limits. At exploratory laparotomy, both ovaries and uterus were normal. There was a huge 20cm.x20 cm. retroperitoneal mass, displacing the caecum, ascending colon and bowel loops to the left. The mass was well circumscribed, encapsulated, not adherent to adjacent structures, soft in consistency and mobile. After ascertaining resectability, through a laterally placed incision over the posterior peritoneum the mass which appeared to be an encapsulated lipoma was excised entirely with the capsule (Fig.3 A and B).

She was discharged on the fourth postoperative day, and remains well at followup 4 months later. Grossly, the huge lobulated specimen which had a smooth outer surface, measured 240x250x130mm, weighing 3.36 kg. Cut section showed a homogeneous yellowish surface with areas of fibrosis, but no haemorrhage or necrosis. Microscopically it was composed of mature univacuolated adipocytes interspersed with thin and thick fibrous septae. Foamy macrophages, fibrosis and lymphoid aggregates were also noted in a few areas. There were no lipoblasts. No atypical spindle cells seen in the stroma. **HPE: retroperitoneal lipoma**, no evidence of malignancy. (Fig.4)

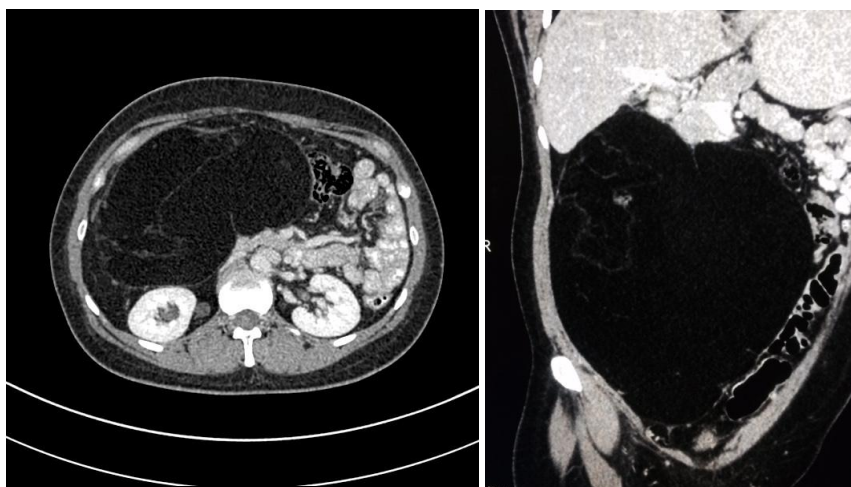


Figure 2. CECT :A. Axial and B. Coronal view showing large mass displacing bowels, mild right hydronephrosis, and encapsulated mass with homogeneous fat density and septations

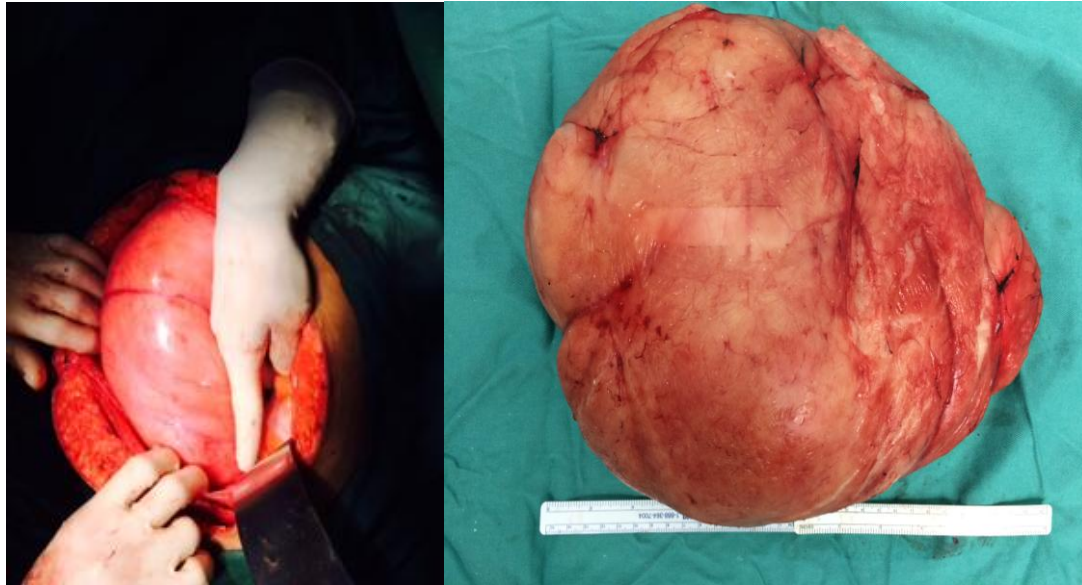


Figure 3.A.Exploratory laparotomy showing the giant retroperitoneal tumour, **B.** Specimen after complete excision

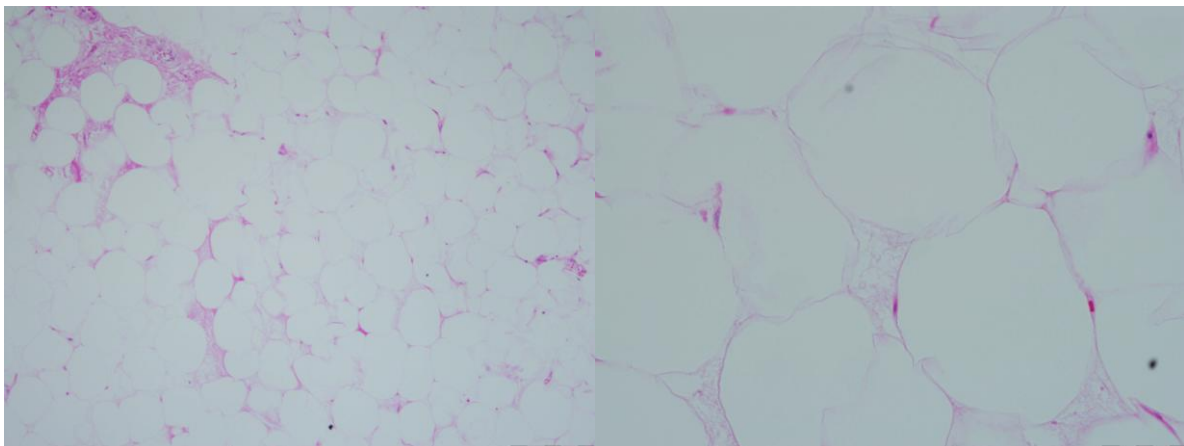


Figure 4.A.Photomicrograph of the lipoma showing mature univacuolated adipocytes interspersed with thin and thick fibrous septae (H&E,20X) , **B.** Mature univacuolated adipocytes(H&E,40X)

III. Discussion

Giant retroperitoneal lipoma in adults is rare[9]. The exact cause remains obscure. Clinically the patients are asymptomatic initially. Abdominal distension occurs late , probably due to the diffuse space in the retroperitoneum which can allow the slow growth and expansion of the tumour[3]. Patients may present with abdominal mass, pain or pressure effects from the tumour on the neighbouring organs [4]. The clinical significance of retroperitoneal lipoma lies in its ability to mimic other intra-abdominal and pelvic lesions. The diagnosis of retroperitoneal tumour is made by radiological imaging and confirmed with histopathology.

Ultrasound can differentiate between solid and cystic tumours. Retroperitoneal lipomatous tumours are characteristically well defined homogeneous echogenic masses on ultrasound [10]. On the other hand mature cystic ovarian teratomas are described as heterogenous and hyperechoic due to the presence of fat, fluid, hair, sebum or teeth (dermal plug) within the cyst that produce distal acoustic shadowing. Occasional calcification or septation may also be seen[11]. Characteristic sonographic features should include at least two of these features to confidently diagnose teratomas[12]. In our patient, ultrasound revealed a diffuse hyperechoic mass with no evidence of cyst formation or calcifications. Moreover ,evidence of compression of right ureter and IVC was reported which is probably more in favour of soft tissue mass.

Contrast Enhanced CT scan can delineate the finer features within the retroperitoneal tumour making differentiation between retroperitoneal lipoma and liposarcoma possible[3].Retroperitoneal lipoma has well defined outline with internal density resembling fat , with occasional fibrous septae and non -enhancement after contrast administration. On the other hand a mature cystic ovarian teratoma due to the presence of fat or sebum can mimic a retroperitoneal lipomatous tumour [13]. Fat attenuation within a cyst with or without wall

calcification is indicative of mature cystic teratoma. Fat is present in 93% of ovarian tumours whereas calcification or teeth is only seen in 56% of reported cases[14].Mature cystic teratoma is the commonest gynaecological tumour especially in younger women . This fact, combined with appearances at imaging and the extreme rarity of retroperitoneal lipomas , may explain the diagnostic dilemma in our patient. Foshager also noted that due to lack of specificity ,it is extremely difficult to diagnose gynaecological masses based on imaging studies alone. He suggested that additional features like vascular compression or encasement, ureteric displacement or compression and bowel displacement should be taken into account while interpreting results of imaging studies[15]. The role of FNAC and Core needle biopsy remains controversial. In a recent study Chew reported that preoperative biopsy has no value in the clinical and radiological assessment of patients with resectable large retroperitoneal masses[16].

In this patient the correct diagnosis was made on exploration , and the surgeon was summoned to proceed further. The large size of the retroperitoneal mass, with displaced organs , distorted anatomy combined with the lack of prior histological knowledge proved to be challenging. Intraoperative judgement about characteristics of the tumour, and the decision to determine the extent of resection are important considerations[9]. In case of doubt , a wide resection which should include any infiltrated contiguous structures should be done to achieve adequate margins. If oncological resections are not feasible , debulking can be considered to relieve symptoms. For all these reasons it has been suggested that such tumours are better managed in specialised high volume sarcoma centres [9]. In our case , the tumour resembled a lipoma macroscopically , was encapsulated entirely inspite of its size and well circumscribed with no obvious infiltration.Hence it could be removed entirely . Pathology was confirmed as benign lipoma . Recent reports suggest that cytogenetic and molecular studies should be done to definitely confirm the diagnosis. Retroperitoneal lipomas are known to be associated with rearrangements of chromosome 1 and 8,unlike liposarcomas which have different rearrangements [17]. Also these types of tumours are known to recur and undergo malignant transformation . Hence careful followup of operated patients should be done . Our patient after 4 months is doing well and we intend to continue her observation .

IV. Conclusion

In conclusion we report the case of a 32 year old female presenting with a large abdominal tumour initially diagnosed as a mature cystic ovarian teratoma,based on clinical and imaging studies. The on table diagnosis and subsequent surgical management presented challenges. Though extremely rare , retroperitoneal lipoma should be considered in the differential diagnosis of ovarian masses to avoid misadventures and plan appropriate surgical strategies in advance.

Acknowledgements:

We wish to thank Dr. Siti Hajar from the Radiology Department and Dr.Nur Asjilla from the Pathology Department of Hospital Universiti Sains Malaysia for help in the interpretation of the Imaging and Histopathology findings.

Conflicts of interest : Nil

References

- [1] S.W.Weiss,Lipomatous Tumours,Monographs in Pathology,38,1996,207-239
- [2] M.R.Pai,R. Naik, C.V.Raughveer,Primary retroperitoneal tumours:a 25 year study,Indian Journal Medical Sciences,49,1995,139-141
- [3] Wei Wei Wee-Stekly,Michael David Mueller ,Retroperitoneal tumors in the pelvis:a diagnostic challenge in gynaecology,Frontiers in Surgery,1(49),2014,1-4
- [4] C.A.R.Martinez,R.T.Palma,J.Waisberg,Giant retroperitoneal lipoma-a case report,Arq.Gastroenterol.,40(4),2003,251-255
- [5] S.Constantinoiu,R.Birla,C.Iosif,et al, Difficulties in diagnosis and surgical treatment of giant retroperitoneal lipoma, Chirurgia-Romania,104(3),1990,363-367
- [6] A.J.Spillane,J.M.Thomas,Gynaecological presentation of retroperitoneal tumours, British Journal of Obstetrics and Gynaecology, 107(2),2000,270-273
- [7] P.Kuppuvelumani,S.P.Rachagan,N.Syed,et al, Rare case of large retroperitoneal liposarcoma presenting as a gynaecological problem, European Journal of Obstetrics and Gynaecology and Reproductive Biology,48,1993,220-222
- [8] H.T.Weiner-Muram,D.Muram,Retroperitoneal lipoma manifested as an adnexal mass, Journal of Tennessee Medical Association 81(4),1998,225-226
- [9] M.Weneger, J.G.DeHesse,W.Kunz et al,EnBloc resection of giant retroperitoneal lipoma:a case report and review of the literature,BMC Research Notes,8(1),2015,1038
- [10] W.B.Hull, M.L.Blumenfeld,D.Jacques,Large paravaginal pelvic lipoma;a case report,Journal of Reproductive Medicine,44,1999,636-638
- [11] D.Guttman,In search of the elusive benign cystic ovarian teratoma:application of 'tip of the iceberg sign' , Journal of Clinical Ultrasound,5(6),1977,403-406
- [12] B.S.Hertzberg,M.A.Kliwer,Sonography of benign cystic teratoma of the ovary: Pitfalls in diagnosis, American Journal of Roentgenology,167, 1996,1127
- [13] D.U.Dodd,R.P.Budzik, Lipomatous tumours of pelvis in females-spectrum of imaging findings, American Journal of Roentgenology, 155,1990,317-322

Giant retroperitoneal lipoma presenting as ovarian tumour-the diagnostic dilemma :case report

- [14] E.K.Outwalker,E.S.Siegelman,J.L.Hunt et al,Ovrian teratomatous tumor type and imaging characteristics, Radiographics,21,2001,475-490
- [15] M.L.Foshager,L.L.Hood,J.W. Walsh,Masses simulating gynaecological diseases at CT ,MR imaging, Radiographics,16,1966,1085-1099
- [16] R. Chew,R.Reid,P.J.O'Dywer,Value of a biopsy in the assessment of a retroperitoneal mass, Surgeon, 4(2),2006,79-81
- [17] C.Foa, C.Mainguene,F.Dupre et al, Rearrangement involving chromosomes 1 and 8 in a retroperitoneal lipoma, Cancer Genetics and Cytogenetics,133, 2002,156-159