

## Treatment of Temporomandibular joint Ankylosis using modified Myrhaug's incision

Dr Channaveer V Pattanshetti<sup>1</sup>, Dr Banashree S Sankeshwari<sup>2</sup>

<sup>1</sup>(Department of Oral and Maxillofacial Surgery, Bharati Vidyapeeth Dental College and Hospital, Sangli, India)

<sup>2</sup>(Department of Prosthodontics, Bharati Vidyapeeth Dental College and Hospital, Sangli, India)

---

**Abstract:** Ankylosis of the temporomandibular joint (TMJ) is an intracapsular union of the disk-condyle complex to the temporal articular surface that restricts mandibular movements, including the fibrous adhesions or bony fusion between condyle, disk, glenoid fossa and eminence. The treatment of temporomandibular joint ankylosis poses a significant challenge because of the high incidence of recurrence. A variety of techniques for its treatment have been described in the literature. However, no single method has produced uniformly successful results. This report presents 5 cases with 3 unilateral post-traumatic and 2 post infection temporomandibular joint ankylosis that showed almost nil mouth opening (1-2mm) along with dental occlusion abnormalities. Gap arthroplasty and contralateral coronoidectomy was performed and passive interincisal mouth opening of at least 36 mm was achieved post surgically. The outcome of treatment was satisfactory in all cases, stating that wide gap arthroplasty if followed by vigorous physiotherapy is sufficient in treating temporomandibular joint ankylosis.

**Key words:** ankylosis, arthroplasty, coronoidectomy, gap arthroplasty, temporomandibular joint

---

### I. Introduction

Temporomandibular joint (TMJ) ankylosis is a disorder that leads to restriction of the mouth opening from partial reduction to complete immobility of the jaw. It is most commonly associated with trauma (13% to 100%), local or systemic infection (0% to 53%), or systemic disease, such as ankylosing spondylitis, rheumatoid arthritis, or psoriasis.<sup>1,2</sup>

TMJ ankylosis may be classified by a combination of location (intra- or extra-articular), type of tissue involved (bony, fibrous, or fibro-osseous) and extent of fusion (complete, incomplete).<sup>3</sup> Literature classifies ankylosis as true and false. Any condition that gives rise to osseous or fibrous adhesion between the surfaces of the temporomandibular joint is a true ankylosis. False ankylosis results from pathologic conditions not directly related to the joint.<sup>1,4</sup>

The TMJ ankylosis is an extremely disabling affliction that causes problems in mastication, digestion, speech, appearance, and hygiene.<sup>5</sup> In growing patients, deformities of the mandible and maxilla may occur together with malocclusion.<sup>6,7</sup>

There are no consensus in the existing literature of the best treatment for TMJ ankylosis. Several authors studied and developed different techniques, but recurrence still remains the major problem when treating TMJ ankylosis.<sup>1,2,5,8-11</sup>

Inadequate exposure of the TMJ region due to fear of damage to the adjacent structures (facial nerve, carotid, jugular and maxillary vessels) often leads to insufficient removal of the ankylotic bone, thus leading to a recurrence of the problem.<sup>3,7</sup>

The purpose of this paper is to show that gap arthroplasty along with contralateral coronoidectomy improves the mouth opening when treating TMJ ankylosis.

### II. Case Report

5 patients were treated for temporomandibular joint ankylosis which included 3 males and 2 females. Ankylosis occurred unilaterally in all the cases. Etiology of ankylosis is as follows: trauma (3 cases), temporal space infection (2 case). Preoperative restriction of mouth opening was 0 to 2 mm (Fig 1). Clinical findings included micrognathia; deviation of mandible to affected side and facial asymmetry. Radiographic investigation included orthopantomogram followed by computed tomography with 3D reconstruction which confirmed true bony ankylosis (Fig 2) and elongated coronoid process on the contralateral side.

The treatment planned was

- 1) Surgery
- 2) Physiotherapy

### III. Surgical Treatment

General anesthesia was administered with nasotracheal fibre optic intubation. An infiltration of 1.8 ml lidocaine with epinephrine 2% was carried out in the surgical field. A modified preauricular incision (Myrhaug's) was placed on the affected side of TMJ (Fig 3), preventing the facial nerve damage, after having previously maintained asepsis and antisepsis of the surgical field and placement of sterile drape.

A dissection was made to access the articular capsule and a condylar retractor was placed behind the neck of the condyle to protect the maxillary artery during arthroplasty. The Gap arthroplasty of 1.5cm was performed (Fig 4) using the micromotor 702 straight fissure surgical bur and the osteotomy was completed using chisel and mallet. A manual guided mouth opening was done to observe condylar movements with direct vision of protrusive, lateral and retrusive movements observing the persistence of ankylosis, the contralateral coronoid apophysis was located and coronoidectomy and temporalis myotomy was carried out intra orally (Fig 5). Condylar movements with mouth opening were rectified, the articular surfaces

were remodeled with a bone file, a Penrose drain under negative pressure was placed for homeostasis and the incision was closed by planes with 3-0 vicryl for muscle, subcutaneous cellular tissue and nylon 4-0 for skin.

Post operatively antibiotics and pain medication was prescribed. The Penrose drain was removed 48 hours after the surgery and physiotherapy started to prevent hypo mobility secondary to fibrous adhesions. The patients are under close follow-up from past 2years with adequate mouth opening of 24mm (Fig 6).

#### IV. Discussion

Temporomandibular joint (TMJ) ankylosis is a disorder that leads to restriction of the mouth opening from partial reduction to complete immobility of the jaw. It is most commonly associated with trauma (13% to 100%), local or systemic infection (0% to 53%), or systemic disease, such as ankylosing spondylitis, rheumatoid arthritis, or psoriasis.<sup>1,2</sup> The kind of trauma that usually results in ankylosis of the TMJ is predominantly experienced in childhood, and if no treatment is undertaken for a fracture of the condyle, the myositic mass grows in the juxta-articular tissue, resulting in a bone mass. Of particular significance is the decision as to the indication and timing of surgical treatment during childhood. The facial remodeling is greater when the release is done in childhood. Remodeling of the mandible after surgery, especially in unilateral ankylosis, is a phenomenon that has no similarity elsewhere in the body.<sup>5</sup>

The main objectives of the ankylosis treatment are: to get a maximum mouth opening, to achieve optimal joint mobility, to avoid inflammation and pain and to restore the initial occlusion in order to obtain facial symmetry.<sup>12</sup>

The administration of anesthesia to patients with TMJ ankylosis is a challenge, as securing the airway can be very difficult. It requires considerable expertise and adequate monitoring facilities. The technique followed in this case is nasal fiberoptic assisted intubation as it is considered the safest technique for securing the airway with the patient awake and under local anesthesia.<sup>5</sup>

The joint was approached by Myrhaug`s incision to prevent facial nerve damage and better surgical exposure.<sup>13</sup>

To prevent surgical recurrence in cases afflicted with ankylosis, radical removal of the bony or fibrous ankylotic segment is essential.<sup>7,9</sup> Several techniques have been described in the literature with different degrees of success. Irrespective of the technique chosen by the surgeon, aggressive resection of the bony or fibrous ankylotic segment is crucial to avoid recurrence. In addition, a dissection of the muscles of the mandibular ramus and ipsilateral coronoidectomy must be carried out to prevent inadequate intraoperative interincisal opening, because the coronoid process may be elongated in long-standing cases. If a 35 mm opening without force is not achieved, a contralateral intraoral coronoidectomy should be done.<sup>14</sup>

The surgical technique followed in this article is the resection of the ankylosed segment creating a gap of 1.5cm following remodeling of the remaining bone structures that formed the joint without alloplastic or autologous grafts between the glenoid cavity and the condyle with contralateral coronoidectomy. Roychoudhury et al<sup>5</sup> recommended a gap of at least 15 mm between the recountoured glenoid fossa and the mandible and subjected this gap to extensive active jaw opening exercises to prevent re-ankylosis when using gap arthroplasty.

According to Kaban et al<sup>9</sup> the advantages of gap arthroplasty are its simplicity and short operating time. A careful surgical technique and subsequent meticulous attention to long-term physiotherapy are both considered essential to achieve a satisfactory result. Interposition of autogenous or alloplastic material at the osteotomy site is a mechanism to prevent recurrence; however, there are possible disadvantages, such as morbidity at the donor site and unpredictable resorption when autogenous material is used, and the risk of a foreign body reaction when alloplastic material is used.<sup>10</sup>

#### V. Figures

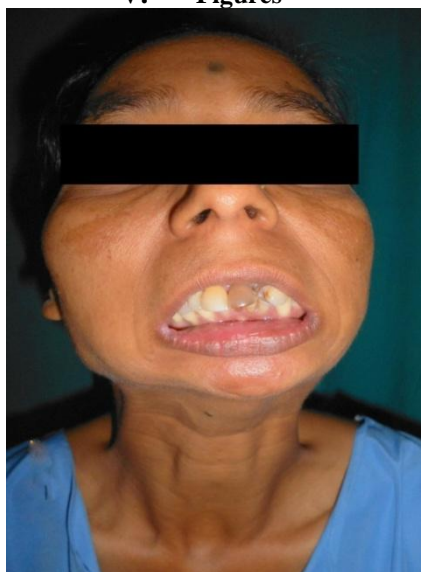

Fig 1: Mouth opening of about 1-2mm

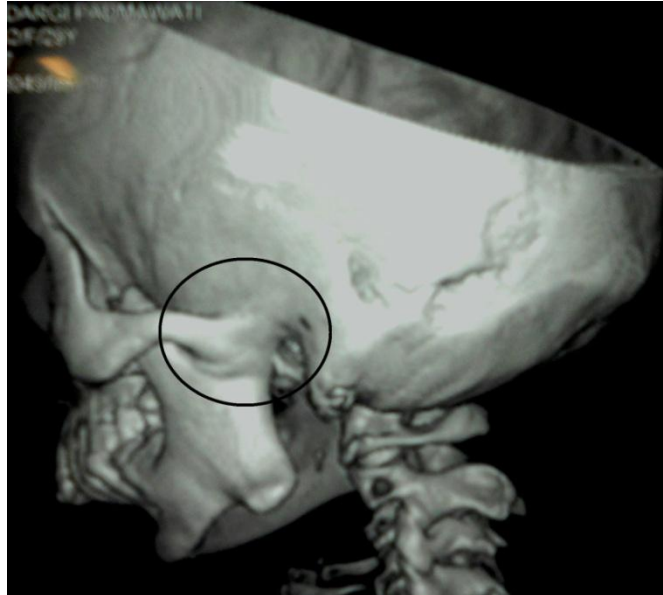


Fig 2: Computed tomography showing bony ankylosis

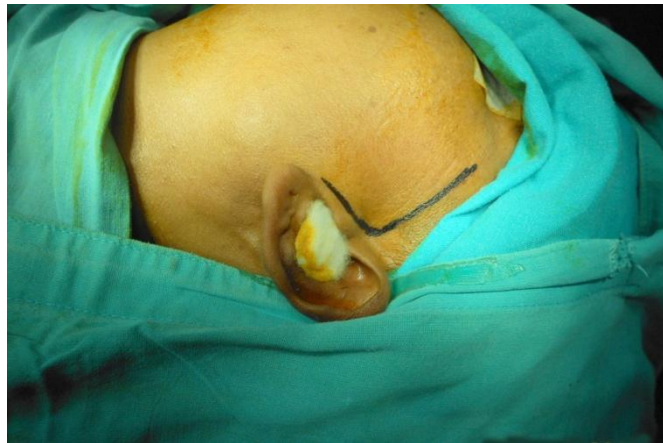

Fig 3: Myrhaug`s preauricular incision

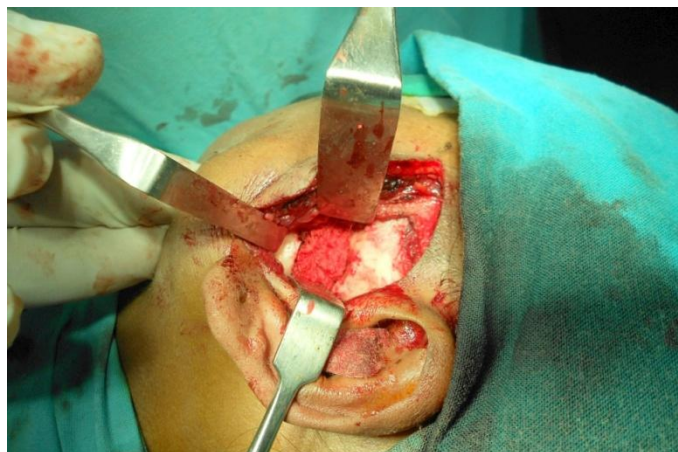

Fig 4: Affected side gap arthroplasty

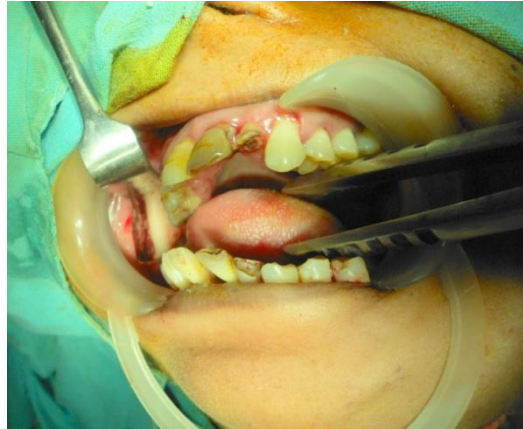
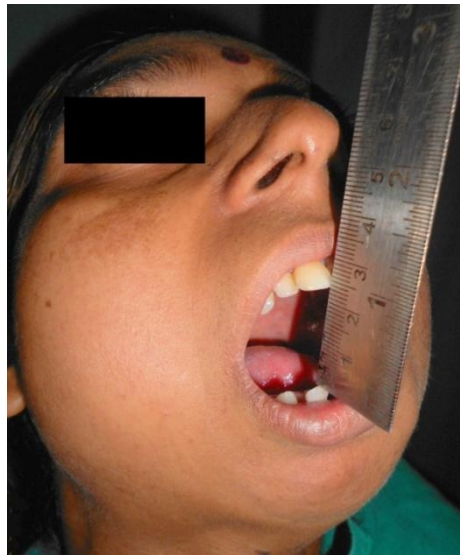
Fig 5: Contralateral coronoidectomy



VI. Fig 6: Mouth opening of 24mm

## VII. Conclusion

Ankylosis of the TMJ is a challenging problem for both the patient and surgeon. Creation of sufficient gap at the ankylosed site by removing adequate bone with contralateral coronoidectomy gave successful results. However, the ultimate success was also dependent to a large extent on proper mouth opening exercises instituted in the immediate postoperative period continued for 6 to 8 months.

## References

- [1]. Gay-Escoda C, Arguero M. La corrección quirúrgica de la anquilosis de la articulación temporomandibular. Descripción de siete casos. Avances en Odontostomatología 1994;10:74.
- [2]. Kaban L, Pogrel MA, Perrott DH. Complications in oral and maxillofacial surgery (1st ed. Philadelphia: WB Saunders; 1997).
- [3]. Rowe NL. Ankylosis of the temporomandibular joint. J R Coll Surg Edinb 1982;26:67-79.
- [4]. Kazanjian VH. Temporomandibular joint ankylosis. Am J Surg 1955;90: 905.
- [5]. Roychoudhury A, Parkash H, Trikha A. Functional restoration by gap arthroplasty in temporomandibular joint ankylosis: A report of 50 cases. Oral Surg Oral Med Oral Pathol 1999;87:166-9.
- [6]. Miyamoto H, Kurita K, Ogi N, Ishimaru JI, Goss A. The role of the disk in sheep temporomandibular joint ankylosis. Oral Surg Oral Med Oral Pathol 1999;88:151-8.
- [7]. Raveh J, Vuillemin T, Ladrach K, Sutter F. Temporomandibular joint ankylosis: surgical treatment and long-term results. J Oral Maxillofac Surg 1989;47:900-6.
- [8]. Ellis III E, Zide MF, eds. Surgical Approaches to the facial skeleton (Philadelphia: WB Saunders; 1995).
- [9]. Kaban LB, Perrott DH, Fisher K. A protocol for management of temporomandibular joint ankylosis. J Oral Maxillofac Surg 1990;48:1145-51.
- [10]. Manganello-Souza LC, Mariani PB. Temporomandibular joint ankylosis: Report of 14 cases. Int J Oral Maxillofac Surg 2003;32:24-9.
- [11]. Chossegras C, Guyot L, Cheynet F, Blanc JL, Cannoni P. Full-thickness skin graft interposition after temporomandibular joint ankylosis surgery: A study of 31 cases. Int J Oral Maxillofac Surg 1999;28:330-4.
- [12]. Miranda HB et al. Temporomandibular joint ankylosis treated with arthroplasty in a patient with rheumatoid arthritis. Revista Odontológica Mexicana 2011; 15(3): 164-169.
- [13]. Agarwal A, Ruparelia B, Kubawat A, Patel S, Gupta S. Modified Gap Arthroplasty and Myrhaug's Incision as a treatment option in management of temporomandibular Joint Ankylosis: A Study of 10 Cases. J Contemp Dent Pract 2011;12(4):295-300.
- [14]. House JW, Brackmann DE. Facial nerve grading system. Otolaryngol Head Neck Surg. 1985 Apr;93(2):146-7.