

## **Study of Anatomical Variations of Mental Foramen in Dry Adult Human Mandibles and Its Clinical Importance**

Vimala V<sup>1</sup>, Rohinidevi M<sup>2</sup>, Mekala D<sup>3</sup>

Assistant Professor<sup>1,3</sup>, Associate Professor<sup>2</sup>

Department of Anatomy, Coimbatore medical College, Coimbatore, Tamilnadu, India

---

### **Abstract:**

**Background:** Morphometric measurement study of mandible is important for dentists in administering the regional anaesthesia while performing the periodontal, dental implant, apicocurettage and endodontic procedures in the mental region of the mandible.

**Materials and methods:** A total of 35 dry adult mandibles of unknown sex with complete dentition and intact alveolar sockets collected from the Department of Anatomy, Coimbatore Medical College, Coimbatore were used for this study. The shape, size, location, number of mental foramen, direction of opening of mental foramen was measured on both sides of the mandible by using digital vernier caliper.

**Results:** The most frequent position of mental foramen was in line with apex of 2<sup>nd</sup> premolar (61.4%). The second common position was between 2<sup>nd</sup> premolar and 1<sup>st</sup> molar (28.2%). Position of mental foramen was similar bilaterally in 71.23%. The shape of the mental foramen was oval in 61.2% and rounded in 38.5% respectively. The direction of opening of mental foramen in most of the mandible was posterosuperiorly. The mean distance from mental foramen to symphysis menti, lower border of the mandible and posterior ramus of the mandible were 26.67mm, 11.25mm and 62.35mm respectively. Accessory mental foramen was seen in 2 mandibles on right side (5.71%). Double mental foramen was present in 1 mandible (2%). The mean measurement of angle of the mandible was 128°.

**Conclusion:** Knowledge about the morphometric measurement of mental foramen is important during various surgical dental procedures.

**Keywords:** Accessory mental foramen, double mental foramen, mandible, mental foramen, morphometry.

---

### **I. Introduction**

Mental foramen is situated in anterolateral aspect of the body of the mandible. It lies below either the interval between the premolar teeth, or the second premolar tooth, midway between the upper and lower borders of the body of the mandible. It transmits mental nerve, artery and vein. Mental nerve is a branch of inferior alveolar nerve which supplies sensation to lower lip, labial mucosa, lower canines and premolars. The most useful injection for anaesthetizing the mandibular teeth is the inferior alveolar nerve block. To anaesthetize the anterior teeth including canines and premolars it is better to inject the anaesthetic solution adjacent to the mental foramen instead of giving inferior alveolar nerve block [1]. Any foramen in addition to mental foramen in the body of mandible is called accessory mental foramen. It transmits auxillary nerves to the teeth (from facial, mylohyoid, buccal and transverse cervical cutaneous and other nerves) [2]. The junction between the lower part of the body of the mandible and posterior border of the ramus of the mandible forms the angle of the mandible. It measures about 110° – 115° in adults [3].

Mental foramen is important landmark to facilitate diagnostic, surgical, local anaesthetic and other invasive procedures of the oral and maxillofacial region. Knowledge of mental foramen and accessory foramen position is helpful to dental surgeons to achieve complete anaesthesia and also helpful to avoid injury during periapical surgery. The gonial angle can be used as a tool in forensic odontology, but has received less attention.

### **II. Materials And Methods**

A total of 35 dry adult mandibles of unknown sex with complete dentition and intact alveolar sockets collected from the Department of Anatomy, Coimbatore Medical College, Coimbatore were used for this study. The shape, size, location, number of mental foramen, direction of opening of mental foramen was measured on both sides of the mandible by using digital vernier caliper. The shape of the mental foramen was either oval or rounded. The relation of the mental foramen was found out by measuring the distance between mental foramen and lower teeth, its position in relation to the symphysis menti, the lower border of the mandible and the posterior ramus of the mandible. The direction of opening of mental foramen was recorded as posterosuperior, superior or anterosuperior. Location of mental foramen was expressed in five relations:

I – Beneath 1<sup>st</sup> premolar

II – Beneath 1<sup>st</sup> and 2<sup>nd</sup> premolar

- III – Beneath 2<sup>nd</sup> premolar
- IV – Beneath 2<sup>nd</sup> premolar and 1<sup>st</sup> molar
- V – Beneath 1<sup>st</sup> molar

The angle of the mandible was measured with the help of protractor. Angle of mandible was taken as the angle between the base and a tangent drawn along the posterior border of the ramus, touching the posterior-most point on the condyle and the posterior-most point on the posterior border (Fig-1).

### III. Results

In 35 adult dry mandibles the shape, position and direction of opening on both sides of the mandible were studied and recorded. The most frequent position of mental foramen was in line with apex of 2<sup>nd</sup> premolar teeth (61.4%) (Fig-2). The second common position was between 2<sup>nd</sup> premolar and 1<sup>st</sup> molar teeth (28.2%) (Fig-3). Next the position of mental foramen was in line with 1<sup>st</sup> molar teeth in (5.6%) (Fig-4). Finally the position of mental foramen between 1<sup>st</sup> and 2<sup>nd</sup> premolar teeth was (4.2%) (Fig-5). Position of mental foramen was similar bilaterally in 71.23%. The direction of opening of mental foramen in most of the mandible was posterosuperiorly. The mean distance from mental foramen to symphysis menti, lower border of the mandible and posterior ramus of the mandible were 26.67mm, 11.25mm and 62.35mm respectively [Table-2]. The shape of the mental foramen was oval in 61.2% and rounded in 38.5% respectively [Table-3]. Accessory mental foramen was seen in 2 mandibles on right side (5.71%) (Fig-2). Double mental foramen was present in 1 mandible (2%) (Fig-6). The mean measurement of angle of the mandible was 128°.

*Table 1: Position of mental foramen in relation with the lower jaw teeth with side*

Position	Bilateral	Unilateral	Right	Left	Total
I	Nil	Nil	Nil	Nil	Nil
II	Nil	3	2	1	3
III	43	9	4	5	43
IV	20	9	6	3	20
V	Nil	4	1	3	4

*Table 2: Position of the mental foramen*

Mean distance from	Study results
Symphysis menti	26.67mm
Posterior border of ramus of the mandible	62.35mm
Inferior border of the body of the mandible	11.25mm

*Table 3: Shape of mental foramen*

Shape	Study results
Oval	61.2%
Round	38.5%

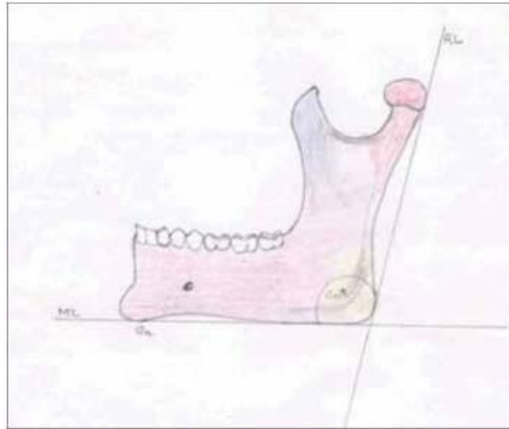
#### *Comparison of the study results with the other studies*

*Table 4: Shape of mental foramen*

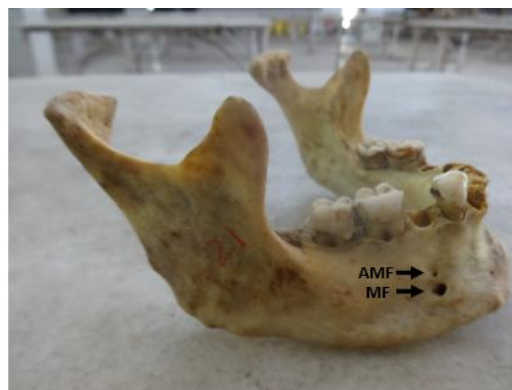
Shape	Prabodha et al (2006)[6]	Priya et al (2014) [7]	Study results
Oval	66.67%	53.3%	61.2%
Round	33.33%	34.67%	38.5%

*Table 5: Position of mental foramen*

Mean distance from	Prabodhe et al (2006) [6]	Sumit et al (2012) [1]	Present study results
Symphysis menti	26.52mm	29.12mm	26.67mm
Posterior border of the ramus of the mandible	65.38mm	74.16mm	62.35mm
Lower border of the body of the mandible	12.25mm	14.45mm	11.25mm



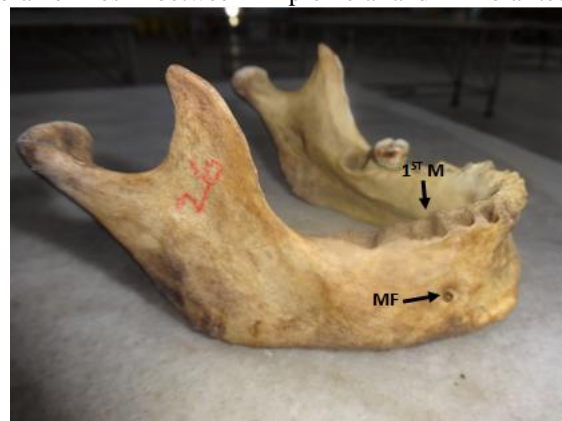**Fig- 1** shows diagrammatic representation of measurement of angle of mandible



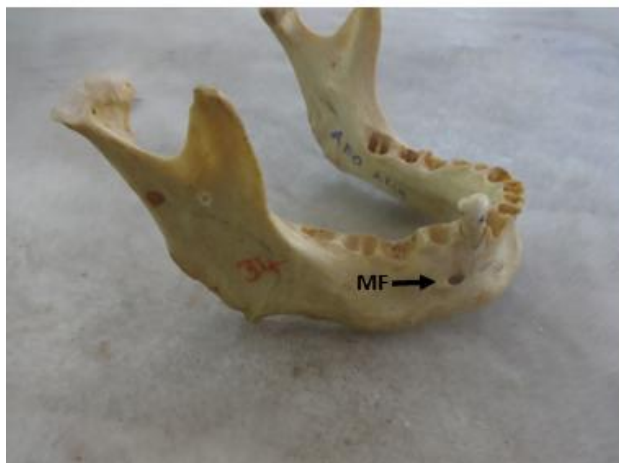**Fig- 2.** Showing the accessory mental foramen and mental foramen in the body of the mandible. Mental foramen is in line with apex of second premolar teeth. AMF- Accessory mental foramen, MF- Mental foramen.



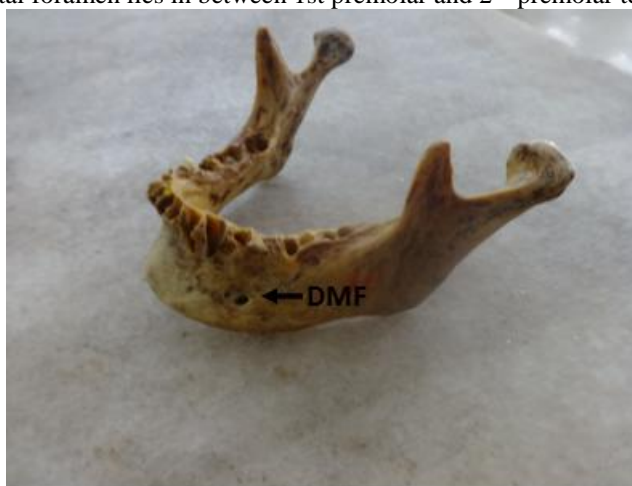**Fig- 3.** Showing the mental foramen lies in between 2<sup>nd</sup> premolar and 1<sup>st</sup> molar teeth. MF- Mental foramen



**Fig- 4.** Showing the mental foramen is in line with 1<sup>st</sup> molar teeth. MF- Mental foramen, M- Molar teeth.



**Fig- 5.** Showing the mental foramen lies in between 1st premolar and 2<sup>nd</sup> premolar teeth. MF- Mental foramen



**Fig- 6.** Showing double mental foramen. DMF- Double mental foramen.

#### **IV. Discussion**

According to Sumit et al in 120 adult dry mandibles the mean distance of mental foramens measurement from symphysis menti, lower border of the body of the mandible and posterior border of the ramus of the mandible was 29.12mm, 14.45mm and 76.16mm respectively. The most common position for the mental foramen was in line with longitudinal axis of the lower second premolar (75.8%) followed by a position between first and second premolar (12.2%) and followed by position in line with first molar was (3.33%). Accessory mental foramen was present in 8 mandibles (6.6%) [1].

Lobes et al studied in 80 dry mandibles and stated that the mean distance of mental foramens measurement from symphysis menti and lower border of the body of the mandible was 26.14mm and 13.83mm respectively. The most traditional location of the mental foramen is in position with second premolar followed by the position between the first mandibular premolar and second premolar teeth [3].

Ilayperuma et al stated that in 51 adult dry mandibles the mean distance of mental foramen from symphysis menti was 24.86mm. The most common position for the mental foramen was in line with longitudinal axis of the lower second premolar (52.94%) followed by a position between first and second premolar (26.47%). In most of the mandibles the shape of the mental foramen was oval (59%). Incidence of multiple mental foramens was 3.92% [4].

According to Deepa et al in 100 dry mandibles the mean distance of mental foramens measurement from symphysis menti and lower border of the body of the mandible was 25.28mm and 12.13mm respectively. The most common position for the mental foramen was in line with longitudinal axis of the lower second premolar (81.52%) followed by a position between first and second premolar (7.7%) and followed by position in line with first molar was (7.9%). Double mental foramen was present in 2.6% of cases. The shape of mental foramen was oval in 92% and rounded in 8% of mandibles. The opening of mental foramen was posterosuperiorly in 92% of mandibles [5].

Prabodha stated that in 24 adult dry mandibles the mean distance of mental foramens measurement from symphysis menti, lower border of the body of the mandible and posterior border of the ramus of the

mandible was 26.25mm, 12.25 and 65.38mm respectively. The shape of mental foramen was oval in 66.67% and rounded in 33.33% of mandibles. Accessory mental foramen was present in 2 mandibles (8.33%) [6].

According to Priya et al in 75 adult dry mandibles the mean distance of mental foramens measurement from symphysis menti was 26.50mm respectively. The most common position for the mental foramen was in line with longitudinal axis of the lower second premolar (52%) and second premolar (23.33%). The shape of mental foramen was oval in 53.3% and rounded in 34.67% of mandibles. The opening of mental foramen was posterosuperiorly in 90.67% of mandibles [7].

In the present study the mean distance of mental foramens measurement from symphysis menti, lower border of the body of the mandible and posterior border of the ramus of the mandible were 26.67mm, 11.25mm and 62.35mm respectively coincides with most of the studies. The most common position for the mental foramen was in line with apex of the lower second molar (61.4%) followed by a position between second premolar and first molar was (28.2%) coincides with Deepa et al study. The shape of mental foramen was oval in 61.2% and rounded in 38.5% of mandibles in most of the studies. Accessory mental foramen was seen in 2 mandibles on right side (5.71%). Double mental foramen was present in 1 mandible (2%). The mean measurement of angle of the mandible was 128°.

## V. Conclusion

Knowledge about the variation in the position of mental foramen, presence of accessory mental foramen and presence of double mental foramen is important for dental surgeon in avoiding injury to mental nerve while performing the periodontal, dental implant, apicocurettage and endodontic treatments and to achieve complete effect of anaesthesia after nerve block. The knowledge about the direction of opening is important for dentist while doing mental nerve block.

## References

- [1]. Sumit G, Jagdish SS. Study of anatomical variations and incidence of mental foramen and accessory mental foramen in dry human mandibles. National journal of medical research. 2012(mar);2(1):28-30.
- [2]. Standring S, Borley NR, Collins P et al. Gray's Anatomy: The Anatomical Basis of Clinical Practice-Pleura, lungs, trachea and bronchi. 40th ed. Spain: Churchill Livingstone; 2008: 530-32.
- [3]. Datta AK. Essentials of Human Anatomy (Head and Neck). 5<sup>th</sup> ed. Kolkata: Current Books International; 2009:42-43.
- [4]. Lopes PTC, Pereira GAM, Santos AMPV. Location of the mental foramen in dry mandibles of adult individuals in Southern Brazil. J. Morphol. Sci. 2010;27(1):23-25.
- [5]. Ilayaperuma I, Nanayakkara G, Palahepitiya N. Morphometric analysis of the mental foramen in adult Sri Lankan Mandibles. Int. J. Morpho. 2009;27(4):1019-24.
- [6]. Deepa RA, Sandeep BG. Morphometric analysis of mental foramen in human mandibles of South Gujarat. People's journal of scientific research. 2011(jan);4(1):15-18.
- [7]. Prabodha LBL, Nanayakkara BG. Galle Medical Journal. 2006;11(1):13-15.
- [8]. Priya PR, Ambali MP, Doshi MA, Jadhav SD. Variation in the position and shape and direction of mental foramen in dry mandible. Int J Anat Res. 2014;2(2):418-20.