

## Periodontally Accelerated Osteogenic Orthodontics- The Past and the Future

<sup>1</sup>Dr. Virangi Sagane, <sup>2</sup>Dr. Suresh Kangane, <sup>3</sup>Dr. Anand Ambekar, <sup>4</sup>Dr. Praveenkumar Marure,

<sup>5</sup>Dr. Yatish Joshi, <sup>6</sup>Dr. Chaitanya Khanapure,

<sup>1</sup>2nd Yr P G

<sup>2</sup>Professor & HOD Dept. Of Orthodontics & Dentofacial Orthopedics Midsr Dental College, Latur  
<sup>3, 4, 5, 6</sup> Dept. Of Orthodontics & Dentofacial Orthopedics Midsr Dental College, Latur

---

**Abstract:** Wickodontics- also known as PERIODONTALLY ACCELERATED OSTEOGENIC ORTHODONTICS is a relatively new treatment in the orthodontic realm. It was introduced by Wilckobrothers. Periodontally Accelerated Osteogenic Orthodontics is a clinical procedure combining selective alveolar decortications particular bone grafting and application of orthodontic forces. This procedure is therotically based on the bone healing pattern known as the REGIONAL ACCELERATORY PHENOMENON (RAP). PAOO is a technique which brings about easy tooth movement in a short period of time. The purpose of this article is to describe the history, biology, clinical surgical procedure, indication, contraindication and possible complications of the PAOO procedure.

**Keywords:** Wilcodontics, Alveolar corticotomies, PAOO, Orthodontic tooth movement. Accelerated orthodontics. Orthodontic treatment "Periodontally Accelerated Osteogenic Orthodontics- The Past and TheFuture"

---

### I. Introduction

The use of orthodontic treatment in adult patients is becoming more common. One of the major barriers with patient seeking orthodontic treatment is long duration of the treatment<sup>1</sup>. Growth is almost an insignificant factor in adults compared with children. In addition, there is an increased chance of hyalinization that can occur in adults when compared with adolescents<sup>2</sup>. All these factors make adult Orthodontic treatment a challenging therapeutic modality in dentistry, which necessitates the need for improvised concepts and procedures for the purpose of creating a functional dentition in a healthy periodontal environment. Moreover adults are more concerned about their aesthetics even with braces. To overcome this kind of psychological or psychosocial problem, new Orthodontic techniques have emerged to reduce treatment duration without compromising stability<sup>3</sup>. The new technique described here provides an increased net alveolar volume after orthodontic treatment. This is called Periodontally Accelerated Osteogenic Orthodontics (PAOO) technique. It is a combination of a selective decortication-facilitated orthodontic technique and alveolar augmentation. Dr. William Wilcko and Dr. Thomas Wilcko developed the phrase Accelerated Osteogenic Orthodontics(AOO) and more recently as Periodontally Accelerated Osteogenic Orthodontics (PAOO) based on Hearold's Frost (1983) bone healing pattern known as Regional Acceleratory Phenomenon(RAP)<sup>4</sup>. It results in an increase in alveolar bone width, shorter treatment time, increased post treatment stability and decreased amount of apical root resorption<sup>5</sup>.

### II. Historical Review:

Surgically assisted orthodontic tooth movement has been used since the 1800's. In 1893, Cunningham presented "Luxation, or the immediate method in the treatment of irregular teeth" at the International Dental Congress in Chicago. Corticotomy facilitated tooth movement was first described by LC Bryan in 1893 published in the textbook by SH Guiliford. It was Henrich Kole's publication in 1959; however that set the stage for evolution of corticotomy facilitated orthodontics<sup>6</sup>. Kole believed that it was the continuity and thickness of the denser layer of cortical bone that offered the most resistance to tooth movement. He theorized that by disrupting the continuity of this cortical layer of bone, he was actually creating and moving blocks of bone in which teeth were embedded. He postulated this theory as "bony block movement"<sup>7</sup>.

Bell and Levy published the first experimental study of alveolar corticotomy in 49 monkeys in 1972. They described a model of vertical interdental corticotomy that should have been considered an osteotomy, because they mobilized all dento- osseus segments<sup>8</sup>. Duker et al conducted an experiment on beagle dogs in 1975 and demonstrated that rapid tooth movement could be achieved by orthodontic appliances after weakening the bone by corticotomy. The rapid tooth movement does not affect the vitality of the teeth which have been

moved. The health of the periodontium is also maintained by avoiding corticotomy of the marginal bone<sup>9</sup>. In 2001, however, Wilcko, et al. challenged the concept of “bony block movement.” They reported that in an evaluation of corticotomized patients, utilizing hospital-based high resolution CT scan imaging, that the small outlined blocks of bone lost their structural integrity due to an apparent demineralization of the alveolar housing over the root prominences. This apparent demineralization occurred in close approximation to the circumscribing corticotomy cuts both on the pressure side of the teeth and on the tension side of the teeth. The initial alveolar demineralization and subsequent remineralization was consistent with the cascading physiologic events associated with RAP and not “bony block movement.”<sup>10</sup> Recently in 2008, Wilcko et al introduced a new technique known as Periodontally Accelerated Osteogenic Orthodontics (PAOO) which is the combination of selective decortication-facilitated Orthodontic technique and alveolar augmentation. This technique increases the net alveolar volume after orthodontic treatment by using bone grafts which consists of decalcified freeze dried bone allograft (DFDBA) which reduces the treatment time to 1/3rd the time of conventional Orthodontic treatment.<sup>5</sup> Limitation of a conventional Orthodontic management is that in most cases the patient requires extraction, may result in relapse without the use of retainers, may compromise the health of periodontium due to excessive force and require a longer period of time for the completion of the treatment especially in adults.

### **III. Principle**

Alveolar corticotomies(ACS) are defined as a surgical intervention limited to the cortical portion of the alveolar bone. Whereas in osteotomies both cortical and trabecular bone material is removed in considerable quantities, in ACS the incision must pierce the cortical layer and at the same time penetrate into bone marrow only minimally. Corticotomy-assisted or corticotomy-facilitated orthodontics is a therapeutic procedure that helps orthodontic tooth movement by accelerated bone metabolism due to controlled surgical damage. It is considered an intermediate therapy between Orthognathic surgery and conventional orthodontics. Corticotomy surgery initiates and potentiates normal healing process (Regional Acceleratory Phenomena). Regional Acceleratory Phenomenon (RAP) is local response to a noxious stimulus describes a process by which tissue forms faster than the normal regional regeneration process. By enhancing the various healing stages, this phenomenon makes healing occur 2–10 times faster than normal physiologic healing (Frost, 1983). The RAP begins within a few days of injury, typically peaks at 1–2 months, usually lasts 4 months in bone and may take 6 to more than 24 months to subside. A recent histological study showed that selective alveolar decortication induced increased turnover of alveolar spongiosa (Sebaoun et al., 2008). The surgery results in a substantial increase in alveolar demineralization, a transient and reversible condition. This will results in osteopenia (temporary decrease in bone mineral density). The osteopenia enables rapid tooth movement because teeth are supported by and moved through trabecular bone. As long as tooth movement continues, the RAP is prolonged. When RAP dissipates, the osteopenia disappears and the radiographic image of normal spongiosa reappears. When orthodontic tooth movement is completed, an environment is created that favors alveolar remineralization.<sup>11, 12,13,23,27</sup>

### **IV. Case Selection**

PAOO can be used to accelerate tooth movement in most of the cases requiring orthodontic treatment<sup>8</sup>.

30

### **V. Indication**

- Adult patients requiring shorter treatment time
- Severe bimaxillary protrusion
- Complex skeletal open bites
- To facilitate molar intrusion with removable appliances,
- Intrusion and molar uprighting combining ACS and mini-implants
- Optimization of treatment of patients with cleft lip and palate among others.
- For protraction of molars
- For early space closure in extraction cases
- For expansion of arches in buccal region
- To facilitate eruption of impacted tooth
- For reducing treatment time with sufficient stability
- For decrowding the dental arches
- Patients with alveolar bone volume deficiency

## **VI. Contraindications**

- Patients showing any sign of active periodontal disease,
- Individuals with inadequately treated endodontic problems,
- Patients on prolonged use of corticosteroids,
- Persons under medications that slows down bone metabolism, such as bisphosphonates and NSAIDS
- Patients with poor oral hygiene.
- 

## **VII. Novel Approaches for Pao**

### **1. Lasers**

Laser assisted flapless corticotomy is a useful non-invasive procedure for reducing treatment time and damage to periodontium. It enhances the orthodontic tooth movement by reducing the cortical bone layer (resistant to bone re-sorption relative to spongy bone) following Erbium, Chromium doped Yttrium Scandium Gallium Garnet (Er-Cr: YSGG) laser irradiation, without surgical flap reflection<sup>14,25</sup>.

### **2. Piezocision**

Piezocision assisted Orthodontics is a recently introduced, minimally invasive procedure, combining micro incisions with selective tunnelling that allows hard or soft tissue grafting and piezoelectric incisions. This novel approach leads to short orthodontic treatment time, minimal discomfort, and great patient acceptance, as well as stronger periodontium.<sup>15</sup>

### **3. Micro-Osteoperforations (Mop)**

To further reduce the invasive nature of surgical irritation of bone, a device called Propel, was introduced by Propel Orthodontics. They called this process as Alveocentesis, which literally translates to puncturing bone.<sup>16</sup>

### **4. Vibrations**

Recently, a product by the name AcceleDent has arrived at the market, which makes use of this technology. This device consists of an activator, which is the active part of the appliance that delivers the vibration impulses with a USB interface through which it can be connected to a computer to review the patient usage of the appliance, a mouthpiece that contacts the teeth. It is a portable device that can be charged similar to any other electronic device, and has to be worn for 20 minutes a day. Various case studies using this device have shown the treatment times to be reduced by up to 30-40%<sup>16,26</sup>.

## **Surgical Technique**

The surgical technique for PAOO consists of 5 steps viz<sup>17,24,28,29</sup>

- 1) Raising of flap,
- 2) Decortications,
- 3) Particulate grafting,
- 4) Closure and
- 5) Orthodontic force application.

## **Flap Design**

The objectives of flap design are to<sup>18</sup>

- 1) Provide access to the alveolar bone wherein corticotomies are to be performed
- 2) Provide for coverage of the particulate graft
- 3) Maintain height and volume of the interdental tissues and
- 4) Enhance esthetic appearance of gingival form where necessary.

A proper flap design is essential for the success of any surgical procedure. In PAOO also the flap should provide proper access to the alveolar bone wherein corticotomies are to be performed. A full thickness periodontal flap is raised on both sides. The flap should be extended beyond the corticotomy sites mesially and distally so that vertical releasing incisions are not required. For esthetic purposes the papilla between the maxillary central incisors should be preserved on the labial and palatal aspects. Access to the labial alveolar bone in this area is achieved by “tunnelling” from the distal aspect.

## **Decortication [Fig 1a]**

Orthodontic bracket and light arch wire are placed ideally one week prior to surgery. **Decortication** is performed on both labial and palatal (lingual) aspects of the alveolar bone to initiate the RAP, without creating movable segments of bone. Typically, vertical corticotomies in mid-interdental areas are connected with circular corticotomies<sup>5</sup>. A high-speed hand piece or a piezosurgical knife might be used in regard to general principles of

bone surgery and local anatomic structure., Decorticating the alveolus also stimulates local angiogenesis, which is important because mesenchymal stem cells are also present in artery walls, smaller vessels and may even enter the general circulation<sup>19</sup>.

### **Particulate Grafting [Fig 1b]**

The bone activation is followed by the placement of bone grafting material facially and lingually over the activated bone area. This bone grafting material is typically first wet with a clindamycin phosphate/bacteriostatic water solution of approximately 5 mg/mL. Wetting the grafting material facilitates the ease of placement. The particulate bone grafting material can also be wet with platelet-rich plasma, which does not appear to inhibit tooth movement (personal communication, Dr Chuck White, Bentonville, AR). The use of resorbable particulate grafting materials is preferred. The grafting material can be 100% demineralized freeze-dried bone allograft (DFDBA), a mixture of DFDBA and bovine bone, or a mixture of DFDBA and mineralized freeze-dried bone allograft. The amount of bone grafting material used depends on the severity of malocclusion, preexisting bone and severity of crowding that needs to be resolved, the severity of the anticipated dentoalveolar defect, the number and extent of the osteotomies required, and the amount of intended subtle facial reshaping. The amount of particulate bone grafting material that is used can vary from 0.25 to 1 cc or more per activated tooth. During the conversion of grafting material to bone, there will be reduction in original volume of bone by 50% or more<sup>5</sup>. Roth et al described that patients with thinner mandibular cortices are at increased risk for dental relapse<sup>20</sup>. The bone grafting procedure or alveolar augmentation that is performed in conjunction with the bone activation at the time of PAOO surgery will provide for additional alveolar volume over vital root surfaces<sup>21</sup>.

### **Closure Techniques**

Primary closure of the gingival flaps without excessive tension and graft containment are the therapeutic endpoints of suturing. The flap should be closed using non resorbable interrupted sutures without creating excessive tension. No packing is required. The sutures are usually left in place for 1 to 2 weeks. When more than 0.5 cc of bone grafting material is used per tooth, the sutures are retained in place for 3 weeks. Premature suture removal can result in flap displacement, opening of interproximal embrasures (dark triangles), and gingival recession<sup>5</sup>.

### **Computed Tomographic Scan<sup>5</sup>**

A composite shows the dentoalveolar defecting that has been filled with new bone. Wilcko et al (2009) explained a comparison of the pre-treatment and post-treatment surface computed tomographic scans of the lower arch.[Fig 2] They concluded that the bone grafting has eliminated the Dentoalveolar deficiency and increased thickness of cortex, which will provide an increased stability after orthodontic treatment

### **Advantages**

- Less time in brackets
- Accelerated treatment time
- Less risk of post orthodontic gingival recession and subsequent cervical abrasion
- Greater post orthodontic stability and retention
- Less risk of root resorption
- Less risk of an unfavorable crown to root ratio
- Less furcation invasion
- Less relapse.
- Facilitates eruption of impacted teeth.

### **Disadvantages**

- An expensive procedure
- It is a mildly invasive surgical procedure, and like all surgeries, it has its risks
- Mild to moderate pain and swelling, and the possibility of infection is seen
- Not recommended in Class -III malocclusion.

### **Management**

Short-term steroids, antibiotics and analgesics are prescribed to enhance clinical healing and patient comfort. On the other hand, long-term administration of NSAIDs postoperatively is discouraged due to the reason that NSAIDs are considered to be interfering with the RAP. Postoperative application of icepacks for suppressing swelling and oedema is suggested. Oedema, ecchymosis and moderate pain are the most commonly

reported postsurgical complications which are not challenging for the clinician in general.<sup>38</sup> Although no adverse effect on pulp vitality and periodontium due to PAOO™ procedure was reported, long-term researches are still needed<sup>22</sup>.

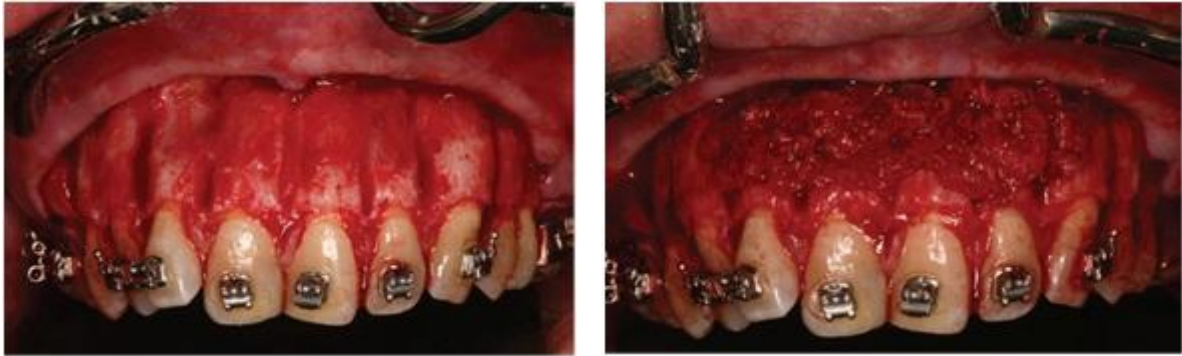
### VIII. Conclusion

The periodontally accelerated osteogenic orthodontics procedure is gaining in popularity with patients and doctors because of the much shorter treatment times and the increased range of treatment capabilities and possibilities. Many misunderstandings and misconceptions about this procedure are being dispelled as knowledge of the technique and results are becoming better known. Over time, it has been transformed into a successful treatment option for many orthodontic problems when used properly, including complicated cases that require a multidisciplinary in-office approach between dental specialties. Treatment planning can be challenging for difficult cases and will perhaps require a different set of parameters to realize the full potential of this technique. It can often make the treatment of severe dental malocclusions more practical while reducing the treatment time for patients from one third to one quarter of the time typically required to treat most dental malocclusions. Additionally, the alveolar volume can be increased to aid in supporting the teeth while correcting preexisting dehiscences and fenestrations when there is a vital root surface. This technique belongs in a specialty arena where both orthodontists and periodontists work together from diagnosis through treatment and retention.

### References

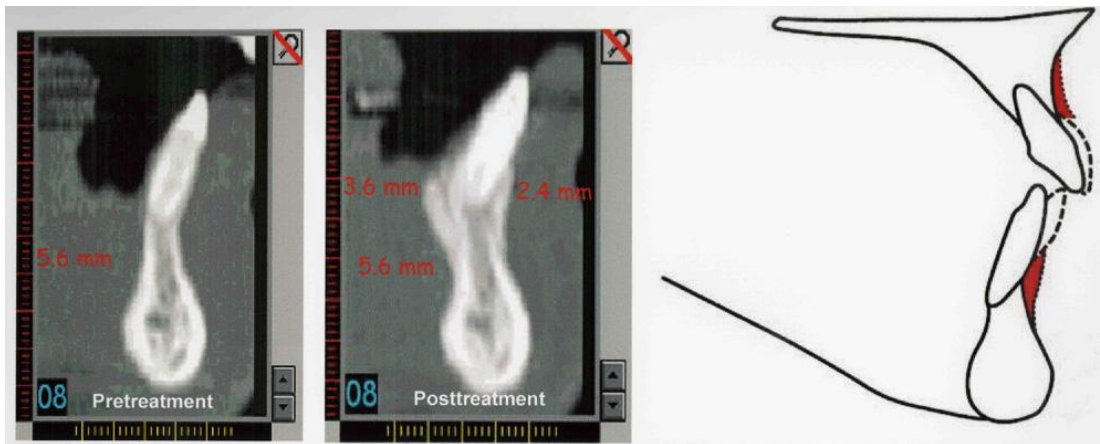
- [1]. T.G. Rappaport, M.H. Shalis and E. Gazit. Psychosocial reward of orthodontic treatment in adult patients. *European Journal of Orthodontics*,2010, 32(4), 441–446
- [2]. Ong MM, Wang HL. Periodontic and orthodontic treatment in adults. *Am J OrthodDentofacialOrthop* 2002;122:420-8.
- [3]. Mathews DP, Kokich VG. Managing treatment for the orthodontic patient with periodontal problems. *SeminOrthod* 1997;3:21-38
- [4]. G. Amit, J.P.S. Kalra, B. Pankaj, S. Suchinder and B. Parul. Periodontally accelerated osteogenic orthodontics (PAOO)- a review. *J Clin Exp Dent*, 4(5), 2012, 292-296.
- [5]. Wilcko MT, Wilcko WM, Pulver JP, Bissada NF, Bouquot JE: Accelerated osteogenic orthodontics technique: a 1-stage surgically facilitated rapid orthodontic technique with alveolar augmentation. *J OralMaxillofac Surg* 2009;67:2149-2159.
- [6]. Cano J, Campo J, Bonilla E, Colmenero C. Corticotomy-assisted orthodontics. *J Clin Exp Dent*. 2012;4(1):e54-59.
- [7]. Kôle H. Surgical operations on the alveolar ridge to correct occlusal abnormalities. *Oral Surg Oral Med Oral Pathol*. 1959;12:515–29.
- [8]. Shrishka K et al. Wilckodontics - A Novel Synergy in Time to Save Time. *J Clin Diagn Res*. Jan 2014; 8(1): 322–325.
- [9]. Duker J. Experimental animal research into segmental alveolar movement after corticotomy. *J Maxillofac Surg*. 1975; 3: 81–4.
- [10]. Wilcko WM, Wilcko MT, Bouquot JE, et al: Rapid orthodontics with alveolar reshaping: Two case reports of decrowding. *Int J Periodontics Restorative Dent* 2001;21:9.
- [11]. Wilcko, M.T., Wilko, W.M., Bissada, N.F.. An evidence-based analysis of periodontally accelerated orthodontic and osteogenic techniques: a synthesis of scientific perspective. *Seminars Orthod*. 2008,14, 305–316.
- [12]. Wilcko, M.W., Ferguson, D.J., Bouquot, J.E., Wilcko, M.T. Rapid orthodontic decrowding with alveolar augmentation: case report. *World J. Orthod*.2003, 4, 197–205.
- [13]. Wilcko, W.M., Wilcko, M.T., Bouquot, J.E., Ferguson, D.J. Accelerated orthodontics with alveolar reshaping. *J. Ortho. Practice* 2000,10, 63–70.
- [14]. Massoud Seifi, Farnaz Younessian, Nazila Ameli. The innovated laser assisted flapless corticotomy to enhance orthodontic tooth movement. *J Lasers in Med Sci*. 2012;3:1–12.
- [15]. Sunanda Roychodhury . Rapid tooth movement – A review. *J Adv Med Dent Scie Res* 2015;3(2):158-161.
- [16]. Shailesh Shenava et al. Accelerated Orthodontics – A Review. *International Journal of Scientific Study*,February 2014 |,Vol 1 ,Issue 5.
- [17]. Bhagyalakshmi A, Avinash BS, Nitin V Muralidhar. Rapid orthodontics – review article. *International journal of health and allied sciences*.2012;1:2-4
- [18]. Kevin G Murphy, M. Thomas Wilcko, William M. Wilcko and Donald J. Ferguson. Periodontal accelerated osteogenic orthodontics: a description of the surgical technique. *J oral Maxillofac. Surg*. 2009;67: 2160-66.
- [19]. Demer L: Molecular regeneration of vascular tissues. Immediate Challenges of craniofacial tissue regeneration, International Conference on Maxillofacial Reconstructive Biotechnology. La Bretesch, France,2005, June 19-22.
- [20]. Rothe LE, Bollen RM, Herring SW, et al: Trabecular and cortical bone as risk factors for orthodontic relapse. *Am J Orthod Dentofacial Orthop*,2006, 130:476-484.
- [21]. Wilcko MT, Wilcko WM. The wilckodontics accelerated osteogenic orthodontics (AOO) technique: An overview. *Orthotown* 2011;4, issue 6:36-48.
- [22]. Hassan AH, Al-Fraidi AA, Al-Saeed SH. Corticotomy-assisted orthodontic treatment: review. *Open Dent J*. 2010;4:159-64.
- [23]. Frost HM. The regional acceleratory phenomenon: a review. *Henry Ford Hosp Med J*. 1983;31(1):3-9.
- [24]. Wilcko MT, Wilcko WM, Marquez MG, et al: Chapter 4: The contributions of periodontics to orthodontic therapy, in Dibart S (ed): *Practical Advanced Periodontal Surgery*. Ames, IA, Wiley Blackwell, 2007:23-50
- [25]. Doshi-Mehta, G., Bhad-Patil, W. A. Efficiency of low-intensity laser therapy in reducing treatment time and orthodontic pain: a clinical investigation. *American Journal of Orthodontics and Dentofacial Orthopedics*. 2012;141(3):289-297.
- [26]. Nishimura, M., Chiba, M., Ohashi, T., Sato, M., Shimizu, Y., Igarashi, K., Mitani, H. Periodontal tissue activation by vibration: intermittent stimulation by resonance vibration accelerates experimental tooth movement in rats. *American Journal of Orthodontics and Dentofacial Orthopedics*. 2008;133(4):572-583.
- [27]. Dorfman HS, Turvey TA. Alterations in osseous crestal height following interdental osteotomies. *Oral Surg Oral Med Oral Pathol* 1979;48:120-5.
- [28]. Kwon HJ, Pihlstrom B, Waite DE. Effects on the periodontium of vertical bone cutting for segmental osteotomy. *J Oral Maxillofac Surg* 1985;43:952-5.

- [29]. Richard D. Roblee, Scotty L. Balding, Jason M. Landers. Surgically Facilitated Orthodontic Therapy:A New Tool for Optimal Interdisciplinary Results. *Compendium*.2009;30:264-76.
- [30]. Moon CH, Wee JU, Lee HS. Intrusion of overerupted molars by corticotomy and orthodontic skeletal anchorage. *Angle Orthod*. 2007;77:1119-25
- [31]. Haseem Nowzari, Frank Kauzo Yorita, Housen Chen Chang. Periodontally accelerated Osteogenic orthodontics combined with autogenous bone grafting. *Compendium*, May 2008, vol 29 ,number 4



**ig 1.** A, After bone activation using circumscribing corticotomy cuts and intramarrow penetrations, left lateral view. B, Bone grafting mixture placed over the activated bone, left lateral View<sup>31</sup>

COMPUTED TOMOGRAPHIC SCAN<sup>5</sup>



**Fig 2.**The original alveolus was 5.6 mm in width. The grafting created 2.4 mm of additional labial bone at B-point and 3.6 mm of new bone lingually.