

Unusual Developmental Foot Mass

Dr.Kannadhasan Ramadhas¹, Dr.Subhashree Chandrasekaran²

¹(Department of Radiodiagnosis, Coimbatore Medical College, Tamilnadu, India)

²(Department of Radiodiagnosis, Coimbatore Medical College, Tamilnadu, India)

Abstract: Focal foot muscle hypertrophy is a relatively rare clinical entity which can be a cause for cosmetic disfigurement and nerve entrapment. Here authors report a case of congenital hypertrophy of muscles of superficial compartment of sole region, which presented as painless foot mass and undergone magnetic resonance imaging of foot in department of Radiology. No other hypertrophic muscles noticed on this foot and none on the right foot. Various foot masses were included as differential diagnosis and discussed. Magnetic resonance imaging helps us to diagnose these conditions and plan appropriate treatment.

Conclusion: Congenital intrinsic foot muscle hypertrophy, though a rare clinical entity, should be included in the differential diagnosis of foot masses. Magnetic resonance imaging provides optimal information to exclude other pathological masses and diagnose such developmental anomalies and associated neurovascular complications and for planning further treatment.

Keywords: Foot muscle hypertrophy, Unusual foot mass in adolescence

I. Introduction

Congenital hypertrophy of intrinsic muscles of foot is rare and literature revealed only a few select cases on the subject.^[1]Single and multiple congenital foot muscle hypertrophy have been reported in literature. Congenital hypertrophy of intrinsic muscles may often present as localized soft tissue mass in the foot in childhood and adolescence.^[2]In such scenario magnetic resonance is considered as preferred imaging tool to differentiate pathological and congenital foot masses.^[3]

II. Case report

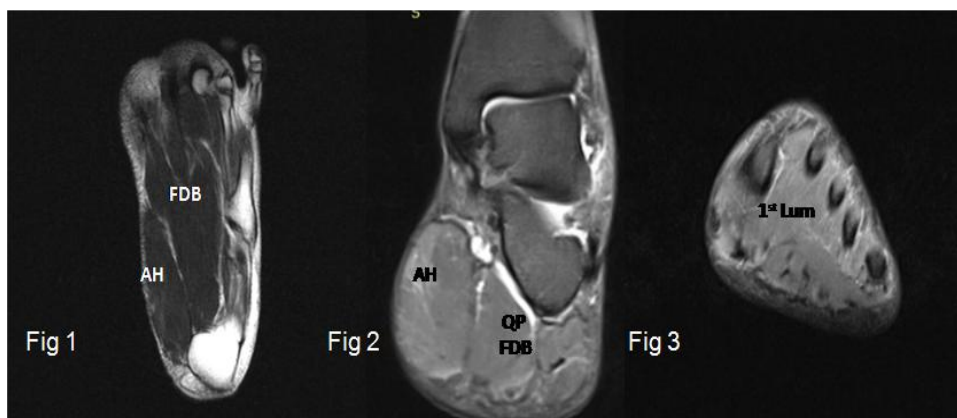
2.1 History

A sixteen year old girl presented to our MRI department from orthopedics outpatient department with complaints of painless swelling of left foot for duration of about five years. There was difficulty wearing foot wear because of discrepancy of size of feet. No such swelling seen in right foot. There was no history of any trauma.

2.2 Examination

On physical examination medial foot was diffusely swollen. Medial arch of the foot was flattened compared to the right side. There was widening of the first web space. Movements of small joints of foot were normal.

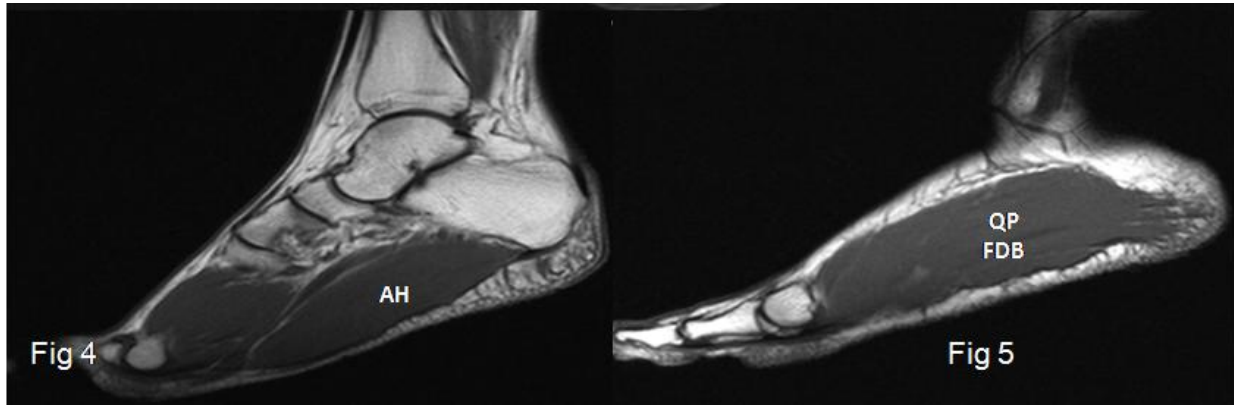MRI of foot performed with following pulse sequences: fat suppressed proton density (PD) and T2 turbo spin echo in axial plane, short tau inversion recovery in coronal and sagittal planes, PD in coronal plane, T1 spin echo and T2* gradient in sagittal plane.



Left foot: Fig1 - Axial T2 WI, Fig2 - CoronalPDFS WI, Fig3- Coronal T2 WI

On MRI sole of left foot showed diffuse enlargement of abductor hallucis and flexor digitorum brevis muscles of first layer, quadratus plantae and first lumbrical muscles of second layer of sole(Fig3). Enlarged muscles showed normal signal intensity pattern on all pulse sequences. Obliteration of the fat pad was seen around the medial plantar neurovascular bundle. Tendons of the foot and sole muscles are intact.

The joints of the foot did not reveal any abnormality. Medial and lateral plantar vessels were normal.



Left foot: Fig 4 - Sagittal T2 WI, Fig 5 - Sagittal T2 WI

No demonstrable thickening of the nerves or altered signal intensities with the nerves. Hence post gadolinium contrast study was not performed. There were no features to suggest any vascular stenosis, vascular malformation or venous thrombosis. Comparison was made with the MRI of right foot, which did not reveal similar features on right side.[Fig 6]

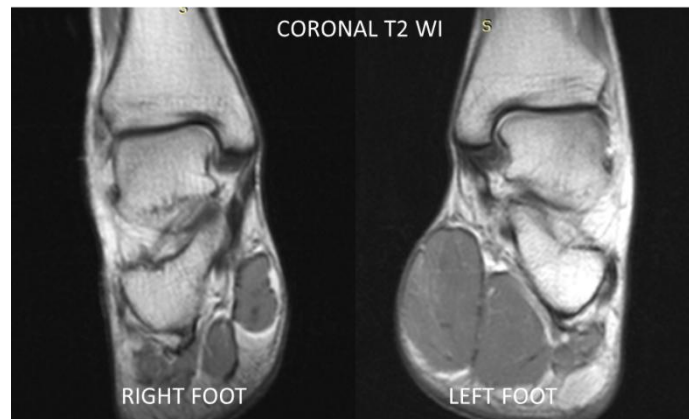


Fig 6 – Right and Left feet for comparison

III. Discussion

The present study documents valuable new data on the anatomical variations of the muscle flexor digitorum brevis, abductor hallucis, quadratus plantae and first lumbrical muscles. Theories about the functions of the foot muscles have centered on their role in arch support. Arches of the foot are normally maintained by bones and ligaments. The foot muscles play an important role in positioning of the forces on the foot in both posture and locomotion.

3.1 Sole muscle anatomy

Plantar aponeurosis is a very dense organized layer of deep fascia that runs down the middle of the sole directly under the skin of the sole region. The plantar aponeurosis is thought to help maintain the medial longitudinal arch of the foot.

3.2 Origin and insertion muscles of the sole of foot in layers

Under the plantar aponeurosis are the muscles that make up the first layer of foot and neurovascular bundles entering the foot.[Fig 7a]The anatomical features of muscles of first and second layer of sole are discussed here.

3.2.1 Muscles of the first layer

Abductor hallucis [AH]-Originates from the medial process of calcaneal tuberosity and inserts into medial side of proximal phalanx of great toe. This muscle abducts and flexes the great toe at the metatarsophalangeal joint. [4] [Fig 7B]

Flexor digitorum brevis[FDB]- Originates from medial process of calcaneal tuberosity and plantar aponeurosis and inserts at the sides of plantar surface of middle phalanx of second to fifth toe. FDB flexes the toes at the interphalangeal joint. [4] [Fig 7B]

Abductor digiti minimi- Originates at medial and lateral process of posterior calcaneal tuberosity and inserts at lateral side of base of proximal phalanx of 5th toe and 5th metatarsal. It flexes and abducts 5th toe and supports lateral longitudinal arch. [4][Fig 7B]

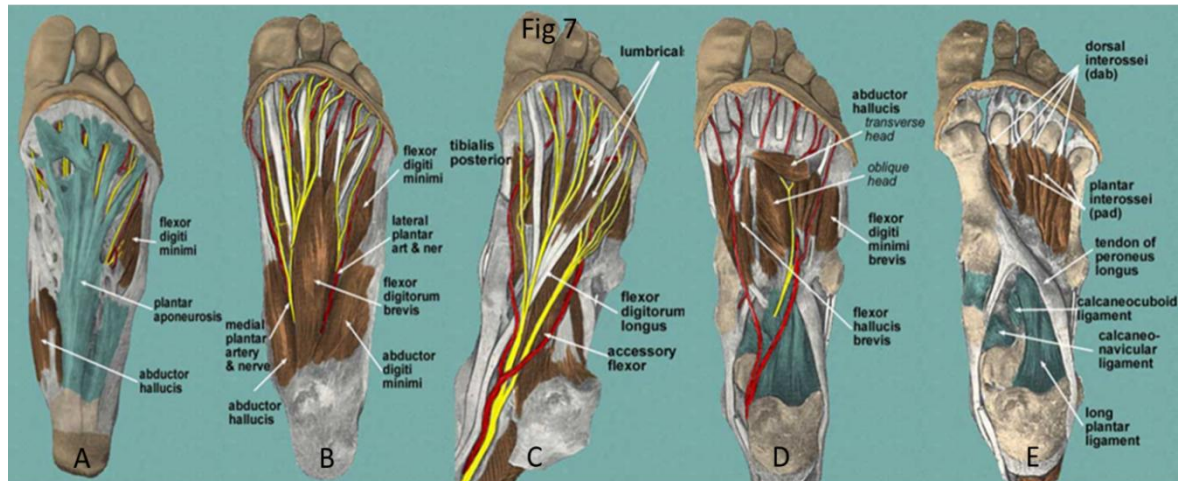


Fig 7A-Plantar aponeurosis
 Fig 7B -First layers and muscles of the sole of the foot
 Fig 7C-Second layers and muscles of the sole of the foot
 Fig 7D-Third layer and muscles of the sole of the foot
 Fig 7E-Fourth layer and muscles of the sole of the foot

3.2.2 Muscles of the second layer (*Flexor digitorum brevis is removed*)

Accessory flexor (quadratus plantae[QP])-Originates at the medial surface of calcaneum and lateral processes of calcaneal tuberosity, inserts onto the lateral surface of tendon of flexor digitorum longus in proximal sole of foot. This muscle assists flexor digitorum longus in flexing the 2nd, 3rd, 4th and 5th toes. [Fig 7C][4]

Lumbricals[Lum] - First lumbrical originates at the medial side of flexor digitorum longus associated with 2nd toe. In second to fifth toes they originate from the adjacent surfaces of tendons of flexor digitorum longus and inserts at the medial margins of extensor hoods of second to fifth toes. It performs flexion of metatarso-phalangeal joints and extension of interphalangeal joints [Fig 7C][4]

3.2.3 Muscles of the third layer

Flexor hallucis brevis, Adductor hallucis, Flexor digiti minimi brevis [Fig 7D]

3.2.4 Muscles of fourth layer

Dorsal interossei and Plantar interossei [Fig 7E]

3.3 Differential diagnosis

Hypertrophy of muscles of sole region is a rare clinical entity. Few cases of single intrinsic muscle hypertrophy of the foot have been reported. Very few have been reported regarding more than one muscle hypertrophy. (4)Such hypertrophic muscles usually present as painless swelling in the foot.

Occasionally they may present with neuropathy due to nerve entrapment syndromes. [5]Frequently the hypertrophied muscle can cause cosmetic disfigurement and poor fitting footwear leading to physical stress.

On MR imaging congenital hypertrophy of intrinsic muscles of foot usually present as enlarged muscle bellies which exhibited isointense signal intensity compared to other normal muscles. Absence of associated pathological features like edema, hemorrhage, necrosis or calcification in an enlarged muscle lead us to think of this diagnostic possibility. However other differential diagnosis to be considered before arriving at the diagnosis

of developmental mass. Common differential diagnosis for the painless foot masses are hemangioma, lipoma, hamartoma, lymphangioma, neurogenic tumours and accessory intrinsic muscles.^[6]

Klippel –Trenaunay –Weber syndrome has been excluded due to the absence of varicosities, cutaneous angiomas and lower extremity hypertrophy.^[7]

3.4 Treatment

Treatment methods consists of observation alone, partial or total excision, according to the operative findings.^[8] Excision of hypertrophic muscles may be necessary alleviating cosmetic disfigurement and to prevent or to correct future complications. In our case patient was prescribed special footwear and long-term periodical follow up.^[9] Understanding muscle architecture of the foot may assist in planning surgical procedures such as tendon transfer, biomechanical modeling of the foot, prosthesis design, and analysis of foot function.^[10]

IV. Conclusion

Magnetic resonance imaging of foot provides optimal information to exclude other pathological masses and diagnose such developmental anomalies and associated neurovascular complications and for planning appropriate treatment. Benign non tumoral lesions can be easily differentiated from benign or malignant neoplastic lesions with use of clinical data and MRI. Diagnosis of congenital muscle hypertrophy can be made easily with MRI among various foot masses.^[11] Congenital intrinsic foot muscle hypertrophy, though a rare clinical entity, should be included in the differential diagnosis of foot masses, viz hemangioma, lipoma, hamartoma, lymphangioma, neurogenic tumours and accessory intrinsic muscles.

References

- [1] Congenital hypertrophy of multiple intrinsic muscles of the foot. Shiraishi T¹, Park S, Niu A, Hasegawa H. (rare and 6cases in literature). <http://www.ncbi.nlm.nih.gov/pubmed/23822188> Department of Plastic Surgery, Shizuoka Children's Hospital, Shizuoka.
- [2] Hypertrophy of the abductor digiti minimi muscle simulating a localised soft tissue mass - Raab P¹, Ettl V, Kozuch A, Nöth U. 15 yr old male case. <http://www.ncbi.nlm.nih.gov/pubmed/19083612>
- [3] University of Wuerzburg, Department of Orthopedic Surgery, König-Ludwig-Haus, Würzburg, Germany. p-raab.klh@mail.uni-wuerzburg.de
- [4] Value of MR findings in predicting the nature of the soft tissue lesions: benign, malignant or undetermined lesion? Soler R¹, Castro JM, Rodríguez E. <http://www.ncbi.nlm.nih.gov/pubmed/8930469> Department of Radiology, Hospital Juan Canalejo, La Coruña, Spain. https://archive.org/details/GraysAnatomy40thEd_201403
- [5] https://archive.org/details/GraysAnatomy40thEd_201403
- [6] Hypertrophic abductor hallucis muscle with nerve compression syndrome. (Page no:38) <http://issuu.com/bsroffice/docs/jbr-2010-6?e=13927557/10607384> Department of radiology Imelda Hospital, imedalaan 9, 2820 bonheiden Belgium
- [7] Imaging of Foot and Ankle Nerve Entrapment Syndromes: From Well-demonstrated to Unfamiliar Sites <http://pubs.rsna.org/doi/pdf/10.1148/rg.233025053>
- [8] Progressive congenital hypertrophy of the feet. J Am Podiatr Med Assoc 1990 Jul;80(7):374-7, N Saunders, C Scheuller Klippel-Trenaunay-Weber syndrome. <http://www.pubfacts.com/detail/2374099/Progressive-congenital-hypertrophy-of-the-feet> J Am Podiatr Med Assoc Doxey-Hatch Medical Center, Salt Lake City, UT.
- [9] Saint Michael's Medical Center involving a congenitally hypertrophic abductor digiti minimi muscle of the right foot – Surgical exploration and excision of entire hypertrophic muscle. J Foot Surg. 1987 Nov-Dec;26(6):501-3.2. <http://www.ncbi.nlm.nih.gov/pubmed/3446705>
- [10] <http://www.scielo.cl/pdf/ijmorphol/v30n1/art59.pdf>
- [11] Reconstructive surgery (Anatomy, technique and clinical applications) - Regional flaps, Anatomy and basic techniques _ Pg no: 924, Michael Zenn, Glyn Jones , Iconomou, T., Tsoutsos, D., Spyropoulou, G., Gravvanis, A., and Ioannovich, J. Congenital hypertrophy of the abductor digiti minimi muscle of the foot. Plast Reconstr Surg. 2005; 115: 1223–1225.
- [12] Hypertrophy of the abductor hallicus muscle: an unusual congenital foot mass. Ringelman PR¹, Goldberg NH. <http://www.ncbi.nlm.nih.gov/pubmed/8406254>. Division of Plastic and Reconstructive Surgery, University of Maryland Hospital, Baltimore 21201.