

Management Of Acquired Laryngotracheal Stenosis –Our Experience.

N Venkatram Reddy MS, Vyshanavi B DNB, Anjani Kumari MS, Sushma MS,
Amreeta Kaur [MS]

Associate Professor Government Ent Hospital/Osmania Medical college Hyderabad
Telangana India

Abstract:

Aim: To assess the outcomes of silastic T Tube and Keel in laryngotracheal surgeries .

Study Methods: This is a retrospective study performed at Government ENT Hospital /Osmania Medical College Koti,Hyderabad,Telangana State,INDIA

A total of 40 cases of laryngotracheal stenosis were included in the study and operated with Shiaan Yaan Lee technique and outcome with respect to successful decannulation was assessed .

Results: Among the 40 cases included in our study tracheal stenosis was seen in 26 cases ,laryngeal in 6 cases and combined laryngotracheal in 8 cases . Males were 28 patients and females were 12 patients . Successful decannulation was possible in 32 of 40 cases . Hence a success rate of 75% was seen .

Conclusion: Management of laryngotracheal stenosis is a challenging problem that demands a multidisciplinary approach.The appropriate treatment option should be individualized according to site of stenosis ,length of the stenotic segment and general condition of the patient. The use of silastic stents has both advantages and disadvantages. Stenting remains a relatively conservative treatment and is successful in a proportion of cases . It does not preclude the possibility of future reconstructive surgery if it fails.

Key Words: Laryngotracheal stenosis(LTS), silicon T tube stenting (STTS), Laryngeal keel(LK).

I. Introduction

Laryngeal stenosis is a congenital or acquired narrowing of the airway that may affect the supraglottis, glottis, and/or subglottis. It can be defined as a partial or circumferential narrowing of the endolaryngeal airway. It can be isolated laryngeal stenosis or combined with tracheal stenosis . The subglottis is the most common site of involvement in the larynx. There are various causes attributed to acquired laryngotracheal stenosis but the most common causes is iatrogenic¹ which include prolonged intubation, post tracheostomy, following road traffic accidents. Rare causes include caustic ingestion ,following croup or even gastroesophageal reflux disease. There are various modalities of treatment which depend upon the site of the stenosis and extent of the stenotic segment and general condition of the patient . Each of the treatment modality has its own advantages and disadvantages .

Management of these cases is challenging and requires a tertiary care set up with skilled surgeon anaesthetist and nursing care for good outcomes in these patients . Results are not predictable and sometimes not rewarding.

In our series we have mainly used keel for the management of glottic and subglottic stenosis and silicon T tube for the tracheal stenosis . we chose this silicon tube stenting as it is a relatively simple technique with least morbidity and restores normal speech and respiration and has a reasonably higher success rate for tracheal stenosis . we report the outcomes with the procedure performed .

II. Materials and Methods:

This study was done in a tertiary referral centre from January 2003 to December 2013,at Govt ENT hospital,Koti,Hyderabad ,Telangana state, INDIA. Institutional ethical committee clearance was taken to conduct this study .

A detailed history and clinical examination was performed in all patients. Patients with history of prolonged intubation or history of tracheostomy or history of trauma to anterior part of neck and presenting with breathlessness or stridor were evaluated for the possibility of stenosis in the larynx or trachea .

All the patients underwent Xray neck lateral view , Computerised tomography with or without 3Dimensional reconstruction of neck and chest to identify the site and extent of stenotic segment. [Picture 1] Suspected cases underwent direct laryngoscopic examination and bronchoscopy to confirm the diagnosis . Once the diagnosis was confirmed all the patients underwent routine surgical profile . In a few cases where the diagnosis was indefinite underwent MRI neck to confirm the diagnosis.

Inclusion Criteria:

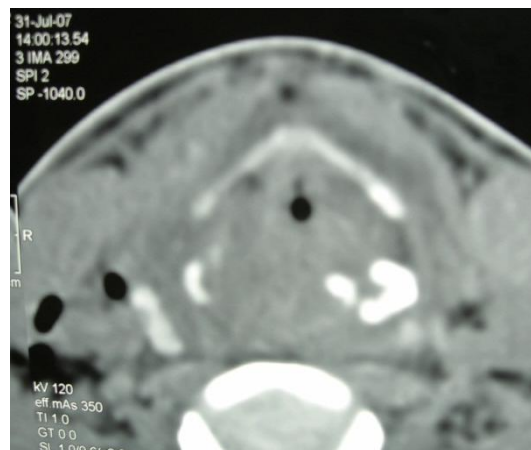
All the adult diagnosed cases of laryngotracheal stenosis following intubation or trauma or tracheostomy were included in the study.

Exclusion Criteria:

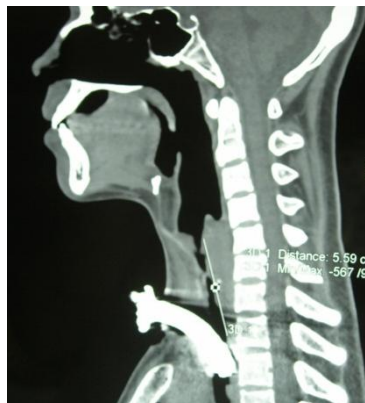- Malignancies of neck
- Pediatric cases
- Burns of the neck

Tracheostomy was performed in a few patients before presenting to us while the others underwent tracheostomy in our hospital as an emergency procedure.

Surgical procedure performed was Shiaan Yann Lee technique² in a few patients and modified technique in few patients in which a horizontal incision was given instead of the midline vertical incision which is classically described. This was followed by placing silicon T tube in situ after excising the fibrous bands in the stenotic segment. This tube was kept for 8 to 12 months and then the patient was reassessed clinically and endoscopically then the tube was removed. Successful decannulation meant the procedure was successful.



Picture 1-Subglottic Stenosis



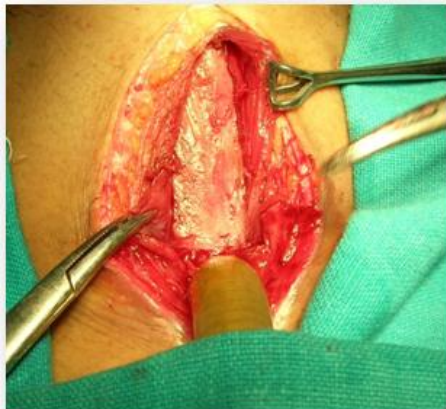Picture 2-Tracheal Stenosis

Surgical Technique: All the patients underwent the procedure under general anaesthesia.

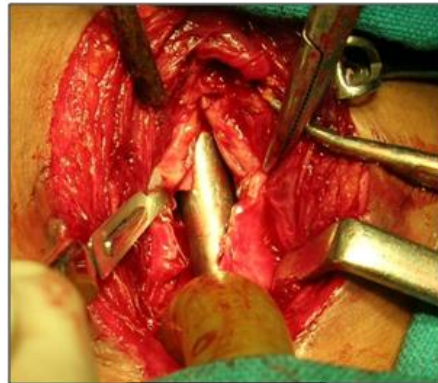Pre Op tracheostomy was performed in all patients prior to the surgery. After intubating the patient Direct laryngoscopy and Rigid Bronchoscopy was performed to identify the stenotic segment. The Bronchoscope was left in situ at the level of the stenotic segment. [Picture 4]

Midline vertical incision was taken extending from superior border of stoma to lower border of thyroid cartilage. [Picture 3] Subcutaneous tissue and strap muscles were separated. Thyroid isthmus separated from trachea was clamped, cut and ligated. Anterior wall of trachea was exposed and incision was taken from upper border of tracheal stoma to cricoid cartilage. [Picture 4] Stenotic segment was exposed. Accurate measurement of stenotic area was taken. Fibrous tissue in tracheal lumen was released and lateralized with 3-0 Vicryl. The T tube was cut to exact length [Picture 5] Tracheostomy tube was removed. Silastic T tube was inserted in stenotic segment with distal limb at least 1 cm above the carina and proximal limb just below the glottis not to

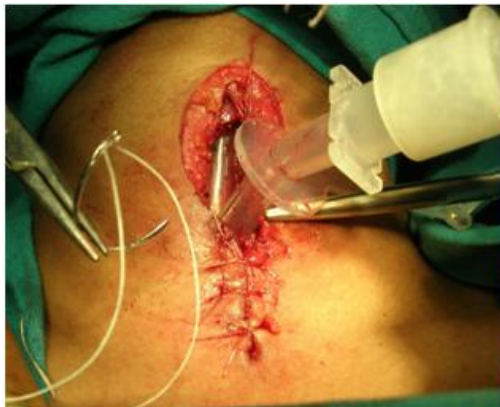rub the undersurface of the glottis. Anaesthesia continued through the T tube. Skin and subcutaneous tissue were sutured over the T tube with 3-0 vicryl. . [Picture 6]Average time of removal of T tube was about 9 months. Patients were reassessed endoscopically before removal of the stent.



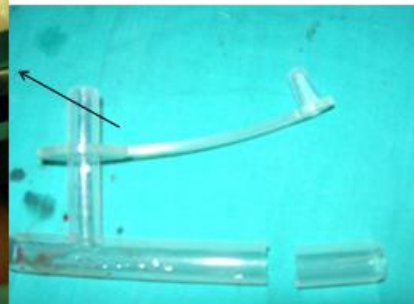Picture 3



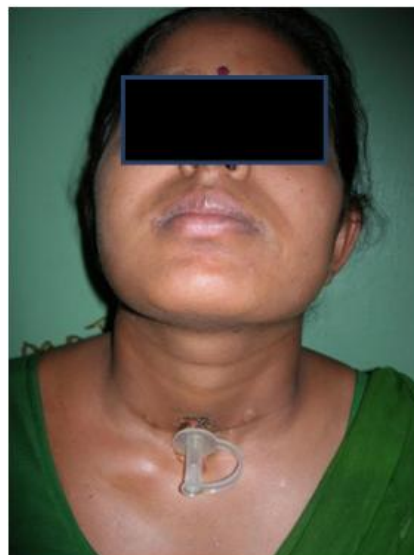Picture 4



Picture 6



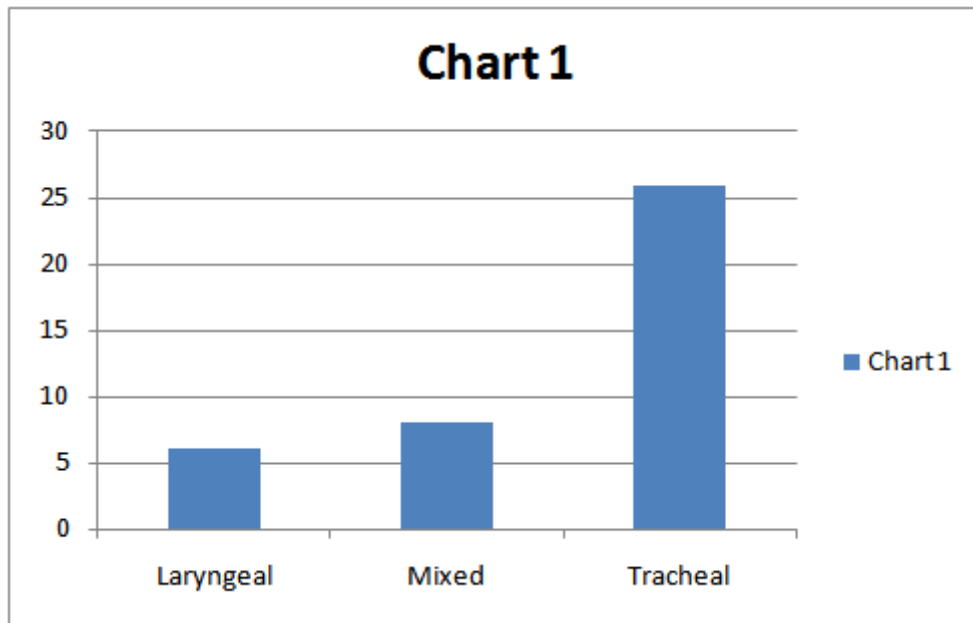
Picture 5



Picture 7-Patient with sialastic tube In Situ Post Operatively

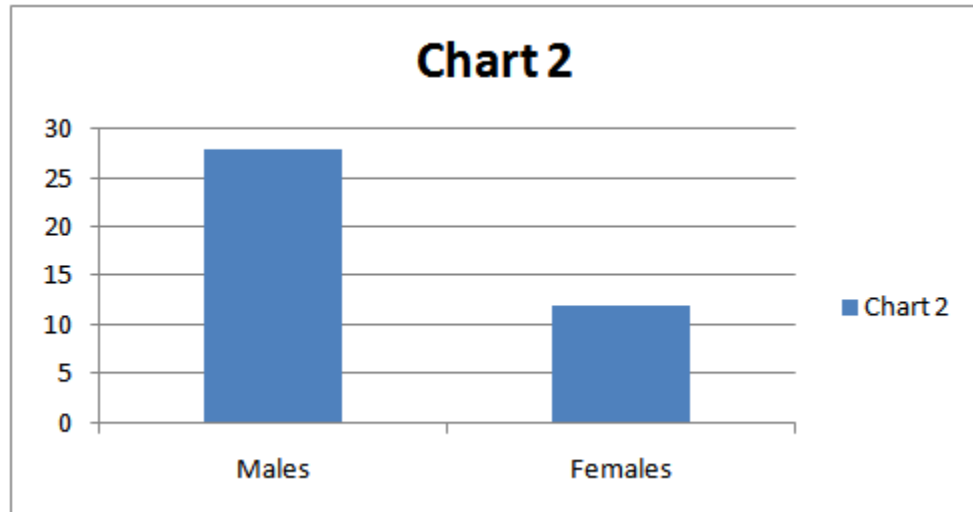
III. Results:

Total number of cases included in our study was 40 of which tracheal stenosis were seen in 26 patients and laryngeal stenosis were 6 patients and combined laryngotracheal stenosis were 8 cases[chart 1]



Among the laryngeal stenosis none of the cases had supraglottic stenosis. One patient had glottis stenosis while five patients had subglottic stenosis.

Males were 28 while the females were 12 –hence the sex ratio was 2.3:1. [Chart 2]



The youngest patient in our study was 19 years while the oldest patient aged 58 years .The mean age was 41.2 yrs .

In all the patients with tracheal stenosis Silicon T tube was used while in patients with subglottic stenosis and glottic stenosis Keel was used .

32 cases recovered well post surgery and had no complications while 8 patients failed . two of these patients had granulations and six patients had restenosis. Overall procedure success rate was 75%.

A few complications reported in our series included Excoriation of skin ,Tube block due to crusts ,Granuloma due to foreign body reaction and restenosis. No Death due to procedure was reported .

IV. Discussion:

Incidence of laryngotracheal stenosis is on rise due to patients being admitted in ICU and requiring prolonged intubation ,excessive cartilage removal while performing tracheostomy ,high tracheostomies³. Thorough evaluation and appropriate management reduces the morbidity and mortality.

In study we treated 40cases of laryngotracheal stenosis. Incidence of tracheal stenosis was higher compared to laryngeal and mixed stenosis . This is similar to study performed by Prasad Kelkar².

The surgery is also challenging for the anaesthesiologist as there is risk of loss airway,inadequate administration of inhalational anaesthetic and inadequate control of mechanical ventilation⁴

In our study the sex ratio was 2.3:1 while a study by Amorós JM reported the incidence to be 1:1⁵ . The mean age in our study was 41.2 while in study Amorós JW reported the mean age of 44.9.⁵ Tracheal T tube provides a good airway⁶ . In addition to providing good airway it restores phonation⁷

The procedure was deemed successful after decannulating the patient , Success rate in our series was 80%[32/40] while another study by Couroud report the success rate to be 93% in their series indicating this a good technique.⁸

In our series there were no major complications but a few reported complications include stent fixation ,obstruction of stent with mucus secretion, displacement of tube and overgrowth of inflammatory granulation tissue.⁹

V. Conclusion:

Management of laryngotracheal stenosis is a challenging problem that demands a multidisciplinary approach.The appropriate treatment option should be individualized according to site of stenosis ,length of the stenotic segment and general condition of the patient. The use of silastic stents has both advantages and disadvantages. Stenting remains a relatively conservative treatment and is successful in a proportion of cases . It does not preclude the possibility of future reconstructive surgery if it fails

References:

- [1]. Gelbard A, Francis DO, Sandulache VC, Simmons JC, Donovan DT, Ongkasuwan J. Causes and consequences of adult laryngotracheal stenosis. *Laryngoscope*. 2015;125(5):1137-1143. doi:10.1002/lary.24956.
- [2]. Kelkar P, Shah R, Mahandru JP, Kasbekar V. Management of laryngo-tracheal stenosis by shiann - yann lee technique. *Indian J Otolaryngol Head Neck Surg*. 2004;56(1):1-4. doi:10.1007/BF02968761.
- [3]. Mandour M, Remacle M, Van de Heyning P, Elwany S, Tantawy A, Gaafar A. Chronic subglottic and tracheal stenosis: endoscopic management vs. surgical reconstruction. *Eur Arch Otorhinolaryngol*. 2003;260(7):374-380. doi:10.1007/s00405-002-0578-3.
- [4]. Park JS, Kwon Y-S, Lee S, Yon JH, Kim DW. Airway management using laryngeal mask airway in insertion of the Montgomery tracheal tube for subglottic stenosis -A case report-. *Korean J Anesthesiol*. 2010;59 Suppl:S33-S36. doi:10.4097/kjae.2010.59.S.S33.
- [5]. Amorós JM, Ramos R, Villalonga R, Morera R, Ferrer G, Díaz P. Tracheal and cricotracheal resection for laryngotracheal stenosis: experience in 54 consecutive cases. *Eur J Cardio-Thoracic Surg*. 2006;29(1):35-39. doi:10.1016/j.ejcts.2005.10.023.
- [6]. MONTGOMERY WW. T-TUBE TRACHEAL STENT. *Arch Otolaryngol*. 1965;82:320-321. <http://www.ncbi.nlm.nih.gov/pubmed/14327039>. Accessed January 12, 2016.
- [7]. Whitehead E, Salam MA. Use of the carbon dioxide laser with the Montgomery T-tube in the management of extensive subglottic stenosis. *J Laryngol Otol*. 1992;106(9):829-831. <http://www.ncbi.nlm.nih.gov/pubmed/1431526>. Accessed January 12, 2016.
- [8]. Couraud L, Jougon J, Velly JF, Klein C. [Iatrogenic stenoses of the respiratory tract. Evolution of therapeutic indications. Based on 217 surgical cases]. *Ann Chir*. 1994;48(3):277-283. <http://www.ncbi.nlm.nih.gov/pubmed/8074414>. Accessed January 12, 2016.
- [9]. Kurrus JA, Gray SD, Elstad MR. Use of silicone stents in the management of subglottic stenosis. *Laryngoscope*. 1997;107(11 Pt 1):1553-1558. <http://www.ncbi.nlm.nih.gov/pubmed/9369407>. Accessed January 12, 2016.