

Treatment of Denuded Root Surface With Freegingival Graft - A Case Report

Irudaya Nirmala J,¹ Ramakrishnan T,² Manisundar N,³ Chandramohan K,⁴
Shobana P,¹ Indumathi P.⁵

¹II Year PG Student, Dept Of Periodontics, ², HOD, Dept Of Periodontics, ³Reader, Dept Of Periodontics,

⁴II Year PG Student, Dept Of Oral Pathology, ⁵I Year PG Student, Dept Of Periodontics.

Adhi Parasakthi Dental College And Hospital, Melmaruvathur.

ABSTRACT: Gingival recession is a common condition due to change in position of the gingiva that affects the supporting structures of the teeth results denuded root which affects the esthetics and stimulate hypersensitivity response due to the exposure of the cementum. Coverage of denuded roots is one of the challenging procedures in periodontal mucogingival surgery. Autogenous free gingival graft is a reliable muco gingival surgical procedure for increasing the zone of attached gingiva and for covering areas of gingival recession. This article reports a case of 42yr old male having Miller's class II Gingival recession treated with free gingival graft. The results showed complete root coverage and increased width of attached gingiva in the recipient site and uneventful healing of donor site.

Key words: Autogenous free gingival graft, Root coverage, Gingival recession, Mucogingival surgery.

I. Introduction

Muco gingival surgery is periodontal surgical procedures designed to correct defects in the morphology, position, and or amount of gingiva.¹ Gingival recession is one of the muco gingival deformity due to displacement of the soft tissue margin apical to the cemento enamel junction. Major causes for this condition includes plaque induced periodontal disease, mechanical force such as faulty tooth brushing, Iatrogenic factors like orthodontic movements, faulty restorations and anatomic factors such as malposition, frenum pull etc.²

Adequate zone of attached gingiva maintains gingival health and for the prevention of progressive loss of connective tissue attachment. According to Lang and Loe ,2 mm of keratinized gingiva is adequate to maintain gingival health.³

Free gingival graft, first described by Bjorn have been widely used in the treatment of mucogingival deformities like lack of attached gingiva and gingival recession.⁴ By using this technique, attached gingiva can be increased and can also be stable as this method has few clinical complications like excessive hemorrhage of the donor site, delay in healing, and disparity in the color of the palatal gingival with respects to the grafted area.⁵ This case report describes about the treatment of class II gingival recession in relation to 31, 41 with free gingival graft.

II. Case Report

A 42 years old male patient came to the Department of Periodontics, Adhi parasakthi Dental college and Hospital, Melmaruvathur, with a chief complaint of Gum recession in relation to 31, 41 and also sensitivity in the teeth. Patient's medical and dental history was not significant. Intra oral examination revealed mild rotation and Gingival recession is 6mm in relation to 31,41 and no probing depth of more than 3mm, minimal bleeding on probing. Radiographic examination showed no bone loss.

Pre-surgical therapy includes scaling, root planing were performed. plaque control instructions were given to the patient. Re-evaluation of the patient after 1 month revealed Millers class II recession in relation to 31,41.[Fig.1] There was inadequate width of attached gingiva in relation to 31,41. so mucogingival surgery was planned. After the patient's consent, the site was treated by Autogenous Free gingival graft. Routine blood investigations were done before doing the surgical procedure.

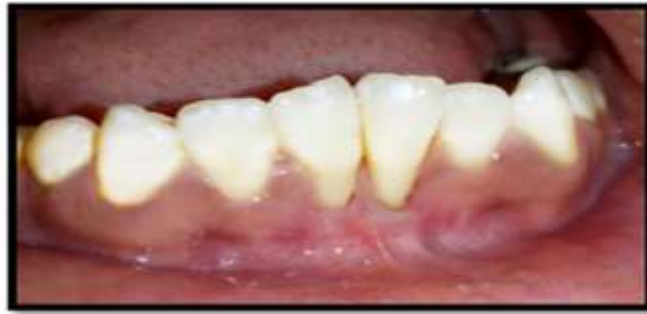

Fig.1: Miller's Class 2 recession 31,41

Surgical procedure:

Preparation of Recipient site:

After adequate local anesthetic application, the exposed root was planed with a Gracey currettes. Initially Frenotomy was done between 31,41. Then de-epithelialization was done at recipient site.[Fig.2] Tin foil was placed on denuded root surface to know the amount of tissue needed.[Fig.3]

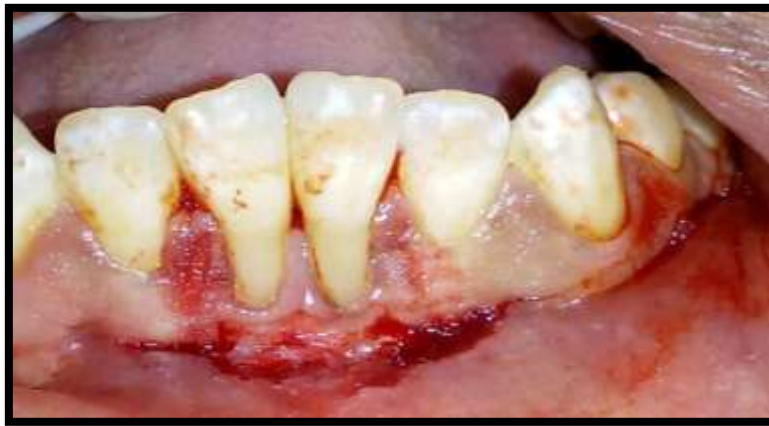

Fig.2: De epithelialization done

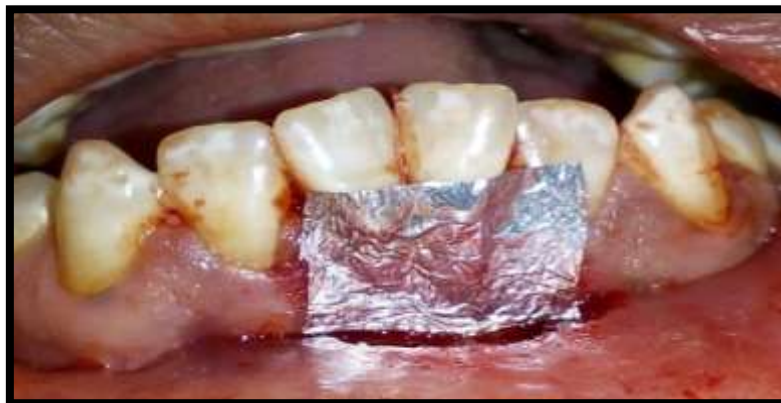

Fig.3: Tin foil placed in recipient bed

Preparation of Donor Tissue:

Then same Tinfoil was placed on the palatal mucosa in relation to 14,15,16 and outline was marked . Then incision was placed and free gingival graft was procured on donor site.[Fig 4,5] Fat or glandular were removed by using of a sharp scalpel blade and thickness of the graft was also checked to ensure smooth uniformity. The graft was placed on the recipient bed [Fig.6] and sutured by means of interrupted sutures at the coronal and apical borders.[Fig.7] The graft was firmly held in place using digital pressure for 5 min. Tin foil placed over the graft to avoid the coe-pak sticking over the graft. [Fig.8] Surgical site was protected by periodontal dressing [Fig.9] *Acrylic stent placed on donor site which add relief area in wound site.*[Fig.10]

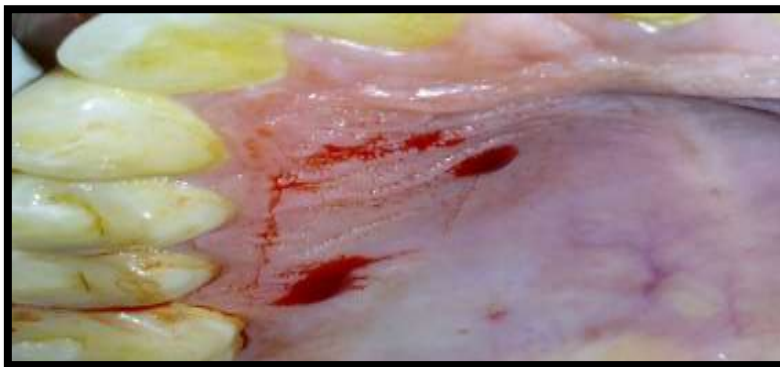

Fig. 4: Donor tissue marked

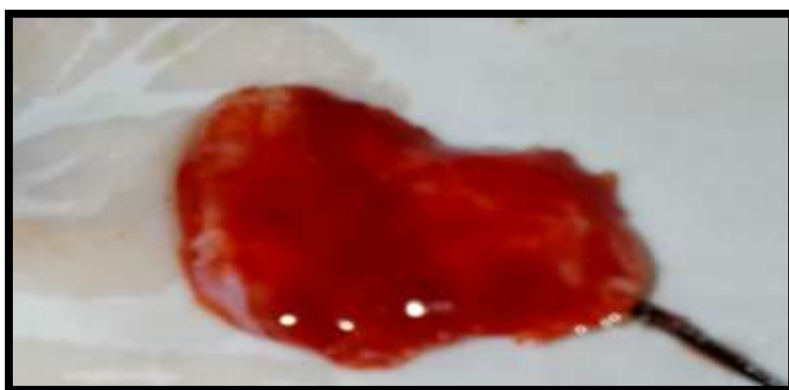

Fig.5: Graft taken from Donor site

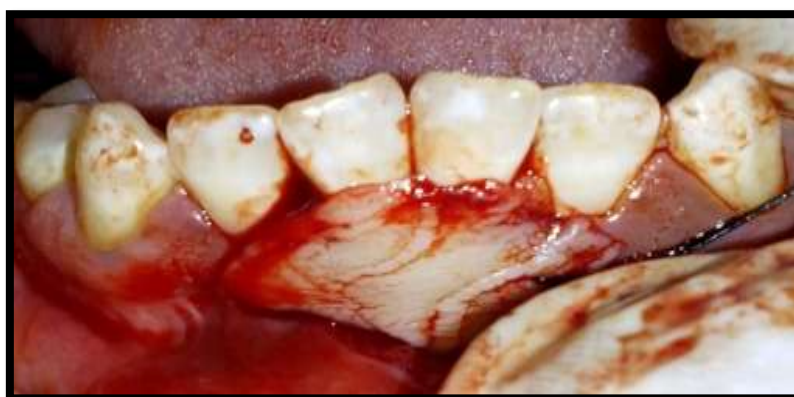

Fig.6: Graft in Recipient site.

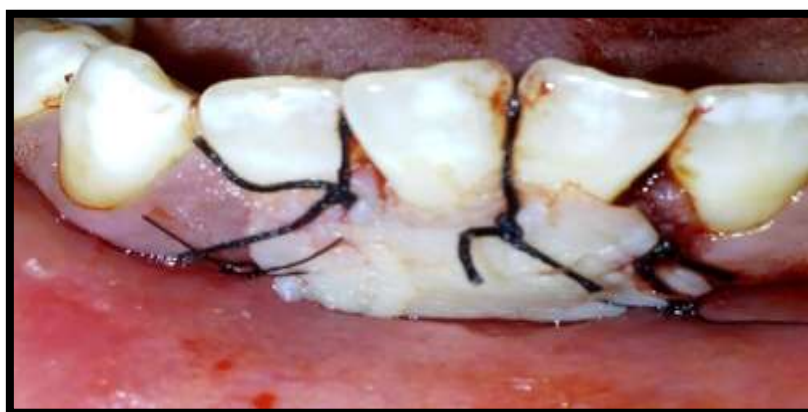

Fig.7: Graft stabilized by sutures.

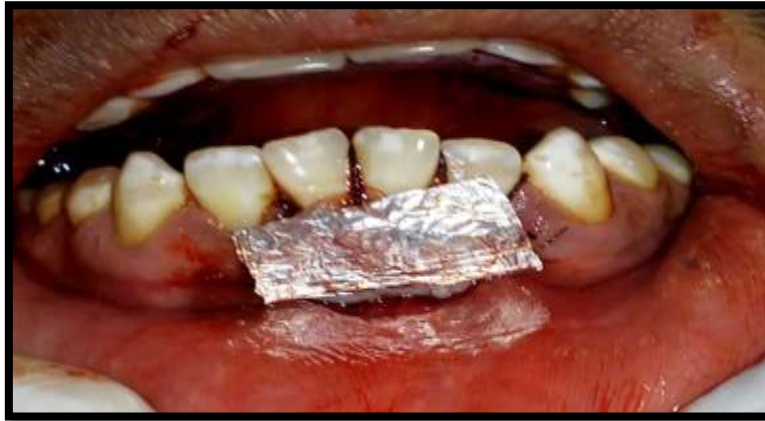

Fig.8: Tin foil placed over the graft

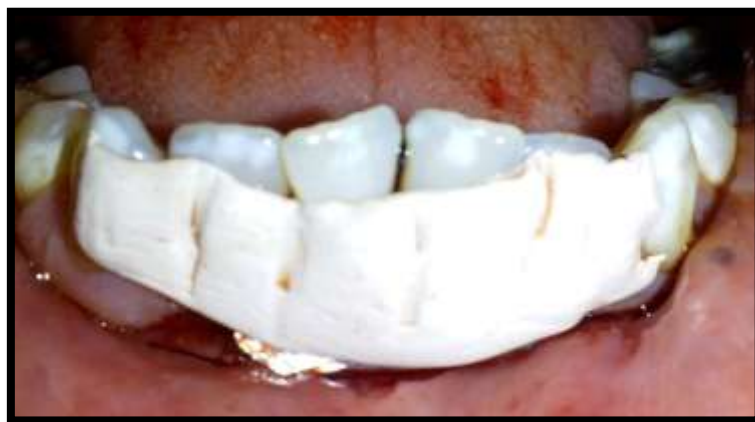

Fig.9: periodontal coe-pack given

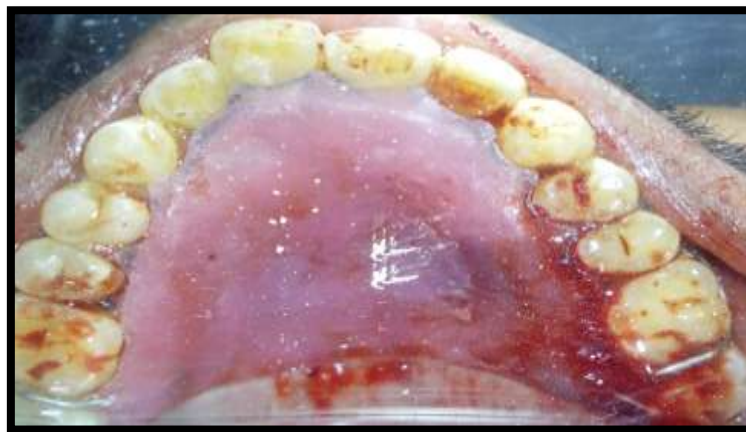


Fig.10: Acrylic stent placed on Donor site

Post operative Instructions:

The patient was advised not to brush at the surgical site for two weeks and asked to use 0.12% chlorhexidine mouth wash twice daily for 3 weeks. Patient was asked to take a course of antibiotics including Amoxicillin 500mg and Ibuprofen thrice daily for 5 days. Acrylic stent was removed after 3 days.[Fig.11] to review the wound healing in donor site and analgesics gel (Mucopain) prescribed. After 2 weeks post operative period, the pack was removed..[Fig.12] The graft was accepted by the recipient bed. Surgical site was irrigated with normal saline and suture was removed. Wound healing was satisfactory with no discomfort. After 1 month post operative period, the results of the therapy was assessed, which revealed complete coverage of the recession and increased width of attached gingiva. [Fig.13] and also gingival recession reduced to 1mm.

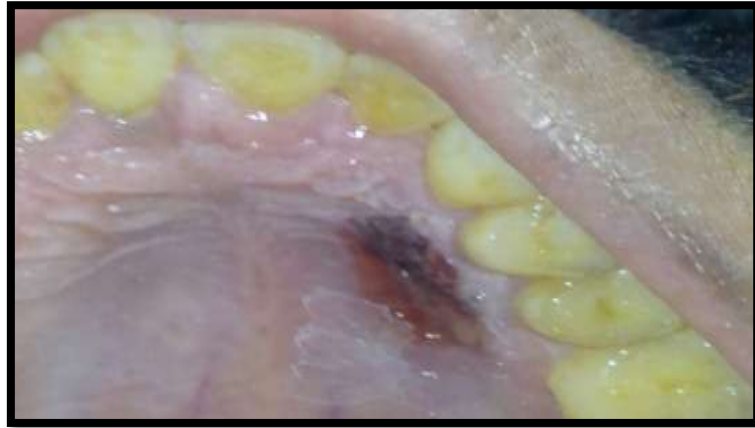

Fig.11: Post-op (After 3 days)

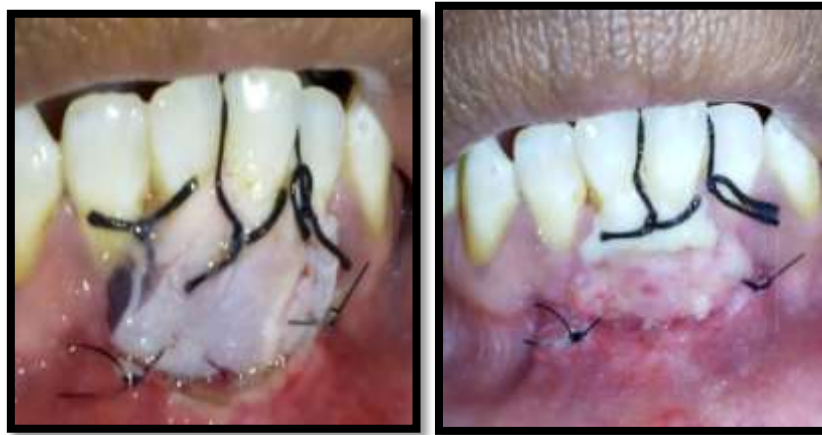

Fig.12: Post -op (After 1, 2 weeks)

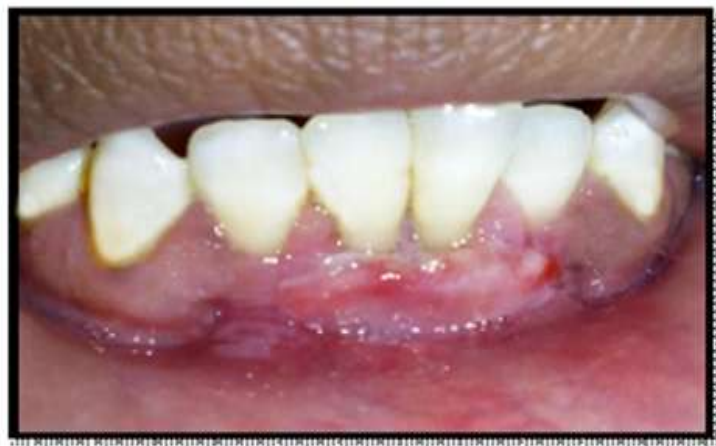

Fig.13: Post-op (After 1 Month)

III. Discussion

Success and predictability of root coverage procedures is mainly based on several factors such as anatomical factors, surgical skill of the operator, and postoperative maintenance of the patient. Among root coverage procedures, Free gingival graft is a most predictable method to increase the apico-coronal dimension of the keratinized mucosa.

The survival of the grafted tissue over the avascular root surface is dependent on adequate blood supply from adjacent tissues, the level of the interproximal gingival tissues, wide interdental papillae and incision type.⁵

Apical de-epithelialized part of the graft was loosely placed for early nourishment of the graft.⁶ Horizontal and vertical incision at the recipient site should be made at a 90° angle in a butt joint fashion. Beveled incisions causes the graft to slide over the incision lines moreover creates dead space between the graft and recipient site which compromise the blood supply.⁴ Dimension and border of the graft will also impact root coverage that is determined by the size of recipient site. Smaller graft will have no direct contact with the periphery of the recipient site that causes impaired blood supply.⁴ Adequate suturing should be essential for graft immobilization moreover it prevents the dislodgement of the graft in the healing process and also prevent necrosis of the graft.⁴ Trauma, smoking induce root coverage failure in free gingival graft. Avoidance of rugae areas in palatal donor site improve the esthetics of the graft in recipient site.⁴ Free gingival graft increases apico coronal width of keratinized mucosa. If gingival recession is narrow, partial coverage may be expected which may prolong the longevity of the tooth.⁵ It is also used in cases of shallow palatal vault, over an extraction socket or osseous graft.⁴ Factors such as narrowness of recession, inter proximal bone level, absence of malpositioning, adequate plaque control influences creeping attachment in free gingival graft⁷ This case report shows that creeping attachment of gingiva takes place after 2 week postoperative period and 1 month follow up in denuded root surface.

IV. Conclusion

The free gingival graft for root coverage is easy and effective management in mucogingival surgery. Even though various root coverage techniques are available, free gingival graft is the best treatment option for gingival recession, shallow vestibular depth, and cases with inadequate gingival tissues receiving a restoration with sub gingival margins.

References

- [1]. Newman MG, Takei HH, Klokkevold PR, Carranza FA. Carranza's clinical periodontology. 10th ed. St. Louis: Elsevier (Saunders); 2006. p.1134.
- [2]. Kennedy Babu S.P.K, Agila S. Root coverage with a free gingival autograft using a diode laser. Journal of Dental lasers, 2012; 2(6): 72-5.
- [3]. Anand V, Gulati M, Rastogi P, Dixit J. Free gingival autograft for augmentation of keratinized tissue in apical to gingival recession – A case report. Journal of oral Biology and Cranio facial Research, 2012; 2(2): 135-7.
- [4]. Saglam M, Koseoglu S. Treatment of localized gingival recessions with free gingival graft. European Journal of General Dentistry, 2012; 1(1): 10-3.
- [5]. Remya V, Kishore Kumar K, Sabitha Sudharsan, Arun KV. Free gingival graft in the treatment of class III gingival recession. Indian Journal of Dental Research, 2008; 19(3): 247-52.
- [6]. Cortellini P, Tanetti M, Prato G.P. The partly epithelialized free gingival graft at lower incisors. A Pilot study with implications for alignment of the muco gingival junction. Journal of clinical Periodontology, 2012; 39: 674-80.
- [7]. Gaurav Solanki. Free Gingival Autograft – A Case report. International Journal of Biomedical and Advance Research, 2010;