

Ovarian Tumours - A Six Year Study From A Teaching Hospital In North-East India.

L. Sushila Devi¹, Anjelica L.², Nisa Kaiho³, L. Ranjit Singh⁴

¹(Associate Professor, Dept. Of Pathology, Jawaharlal Nehru Institute Of Medical Sciences, Imphal, Manipur, India)

²(P.G. Trainee, Dept. Of Surgery, Regional Institute Of Medical Sciences, Imphal, Manipur, India)

³(Tutor, Dept. Of Pathology, Jawaharlal Nehru Institute Of Medical Sciences, Imphal, Manipur, India) ⁴(Professor, Dept. Of Obstetrics And Gynaecology, Regional Institute Of Medical Sciences, Imphal, Manipur, India)

Abstract: Ovarian tumours are responsible for significant morbidity and mortality in women. Relative frequency of these tumours show geographical variations and many of them are symptomless till they are clinically advanced. The present cross-sectional study focuses on various histological patterns of ovarian tumours, their distribution in different age groups and to compare it with other studies in patients admitted at a teaching hospital in Imphal. The benign, borderline and malignant tumours were 81.5%, 6.5% and 12.0% respectively. Surface epithelial tumours account for majority of the cases (65.3%), followed by germ cell tumours (33.1%). Serous cystadenoma was the most common tumour (43.6%) and mature cystic teratoma (37.6%) was the second most common type. Among the malignant neoplasms, mucinous cystadenocarcinoma emerges as the most common type (33.3%). Bilaterality was seen in 4.8%. Of all ovarian tumours, benign tumours outnumbered malignant ones in our study and were seen more commonly in younger patients except for immature teratomas which were seen in patients ≤ 20 years. Early diagnosis and treatment is of vital importance especially in the malignant types to lower the case fatality.

Keywords: Histologic types, Mature teratoma, Ovarian tumours, Serous cystadenoma.

I. Introduction

There is an increase in the incidence of cancers as the human longevity increases. Ovarian cancer is the 3rd most common cancer amongst female genital tract cancers and ranks only below carcinoma of the cervix and the endometrium. It ranks 4th in cancer death among women.[1] Ovarian cancer is the 7th most common cancer in women worldwide with 2,39,000 new cases diagnosed in 2012.[2] In Manipur, according to the population based cancer registry (2014), it is the 6th most common cancer among females. Many of these neoplasms are undetectable in the early stage because of its intra-abdominal location and frequently asymptomatic till they are in a clinically advanced stage. Unlike cervical cancer, precursor lesions are largely unknown and screening methods like bimanual pelvic examination, estimation of CA-125, ultrasonography etc. lack sensitivity and specificity. Geographical variations exist in the relative frequency of various ovarian tumours. Indian cancer registry data project ovary as an important site of cancer in women comprising upto 8.7% of cancers.[3] Determination of the specific histopathological pattern is important for diagnosis, management and prognosis.

II. Materials And Methods

This is a cross-sectional study done in the department of Pathology, Jawaharlal Nehru Institute Of Medical Sciences (JNIMS), Imphal, from January 2009 to December 2014. All the specimens of ovarian tumours received for histopathological examination (HPE) were included in this study. All non-neoplastic lesions of the ovary were excluded. Data including age, clinical presentation, laterality and related history were obtained from the histopathological forms and medical record section. Histopathological findings of each case were studied. Hematoxylin and eosin (H&E) stain was used for each case and special stains (PAS, mucicarmine and reticulin) were also used where appropriate.

III. Aims And Objectives

To study the various morphological and histological types of ovarian tumours and also to analyse the distribution of these tumours in different age groups, laterality and their incidence at JNIMS.

IV. Results

A total of 124 specimens of ovarian tumours were obtained during the study period. Out of these, surface epithelial tumours contributed the bulk of the cases (65.3%), followed by germ cell tumours (33.1%), sex-cord stromal tumours (0.8%) and metastatic tumours (0.8%). Six patients (4.8%) had bilateral tumours consisting of benign (66.7%)

and malignant (33.3%) cases. Mixed epithelial and mixed epithelial and germ cell tumours comprised 16.7% each of the bilateral tumours.

Total number of benign, borderline and malignant ovarian tumours were 81.5%, 6.5% and 12% respectively. Among the benign tumours, serous cystadenoma was the commonest type (43.6%) [Table-1]. Borderline and malignant tumours were more common in mucinous tumours [Table-2&3]. Benign tumours were more common in patients <40 years of age whereas majority of the malignant tumours occurred in patients >40 years, except immature teratoma cases which occurred ≤20 years of age. Maximum number of borderline tumours occurred in 31-40 years age group. Benign tumours were mostly cystic, (96.04%) and only 3.96% consisting of benign Brenner tumour and fibroma were solid. Reticulin stain highlighted the investment of individual tumour cells by fibrils. The borderline and malignant tumours show a heterogenous proportion of both solid and cystic components. Benign cystic teratoma (mature teratoma) contain sebaceous-like material and hair on cut section and showed mostly ectodermal elements like squamous epithelium and subepithelial adnexae like hair follicles.

V. Discussion

Ovarian tumours constitute an important group of neoplasia in women. Wide geographic variation in the incidence rate of ovarian tumours exists with higher rate in the industrialized countries. In the present study, benign, borderline and malignant tumours comprise 81.5%, 6.5% and 12% respectively. Pillai G et al [4] and Gupta et al [5] reported similar findings but Ahmed et al [6] reported a lower incidence of benign and borderline but a much higher incidence of malignant tumours. Surface epithelial tumours account for 65.3% of all tumours similar to the findings of other workers [5][7][8].

5.1. Benign tumours: In the present study, 60.4% of the benign tumours belongs to the surface epithelial tumours. Of the 101 benign tumours, 6 cases occurred in ≤ 20 years of age and 8 cases were seen in >60 years of age. Tumour bilaterality was seen in 6 cases.

5.1.1. Serous cystadenoma: It emerges as the commonest benign ovarian tumour in our study and maximum number of cases are seen in the 4th and 5th decades. Our findings correlate with other authors [7][9], but Ahmed et al [6] reported mucinous cystadenoma as the most common benign tumour. A case of serous cystadenofibroma was included in the present study which multiloculated cyst as well as focal grey-white solid areas..

5.1.2. Brenner tumour: 2 cases of benign Brenner tumour are observed in the present study. Grossly, it shows focal yellow areas and small cystic areas. Microscopically, it consists of a fibrous stroma, resembling that of normal ovary, is marked by sharply demarcated nests of epithelial cells that resemble the epithelium of urinary tract. (Figure-1) A case of bilateral benign Brenner tumour and bilateral serous cystadenoma was observed in our study. It comprises 1.6% of the cases in our study which were seen in post-menopausal women and it correlates with the findings of Tulon Borah et al.[10]

5.1.3. Fibroma: These tumours are rare in women < 20 years of age and occur usually in women > 30 years of age. They can be bilateral in about 5% of the cases. Only 1% of fibromas can present with Meigs' syndrome (triad of ovarian fibroma, ascites and pleural effusion). Our findings of an incidence of 1.98% of fibroma is also comparable to the studies done by Pillai G et al [4] and Puri Agarwal et al.[11]

5.1.4. Germ cell tumours: These comprise 33.1% of all ovarian tumours in our study, out of which 92.7% are mature teratoma. Our findings are higher than that of other workers. [4][12] Mature cystic teratoma emerges as the 2nd most common benign tumour in our study. (Figure-2)

5.2. Borderline tumours: Mucinous borderline and serous borderline tumours (Figure-3) comprise 50% and 37.5% of all borderline tumours in our study which is similar to that of Li et al [13]. However, Priya et al [14] observed serous borderline tumours more common than the mucinous borderline tumours. A case of serous cystadenofibroma of borderline type was also seen in our study. Serous cystadenofibroma and serous cystadenofibroma of borderline type comprise 0.81% of all ovarian tumours in the present study which is comparable to other studies [10][15].

5.3. Malignant tumours: Fifteen malignant tumours are seen in our study and all are unilateral tumours. Malignant tumours of surface epithelial origin comprise 73.3% of all malignant tumours.

5.3.1. Mucinous cystadenocarcinoma. Out of the 5 mucinous cystadenocarcinomas seen in the present study, bilaterality is seen in one case. Mucinous tumours tend to be larger with areas of cystic as well as solid areas. Pseudomyxoma peritonei which was historically thought to be associated with many cases of primary ovarian mucinous tumours is now thought to be of extraovarian primary mucinous tumour.

Higher incidence of borderline and malignant mucinous tumours in the present study are comparable to that of Atif Ali Hashmi et al [16] whereas Jha et al [17] and Mankar D.V. et al [12] reported serous cystadenocarcinoma as the commonest malignant neoplasm in their studies. Swamy et al [18] and Yasmin et al [19] found granulosa cell tumour and endometrial carcinoma as the commonest malignant tumour in their respective studies.

5.3.2. Serous cystadenocarcinoma. A significant proportion of both serous borderline and malignant serous tumours involve the surface of the ovary. Ovarian serous tumours have the propensity to spread to the peritoneal surfaces and omentum. Such findings are found in 3 cases in our study psammoma bodies are also noted in 2 cases.

5.3.3. Malignant germ cell tumour. In the present study, immature teratoma comprised 1.61% of all ovarian tumours and 13.33% of all ovarian cancers, whereas that of choriocarcinoma is 0.81% and 6.7% respectively. Topuz S et al [20] reported lower incidence of both tumour types. Choriocarcinomas are rare ovarian tumours and its incidence in our study is comparable to the findings of other workers [19][21].

5.3.4. Clear cell carcinoma is another rare type of ovarian malignant tumour (Fig.4) and has the same incidence rate as that of immature teratoma in the present study. Bilaterality can be seen in < 10% of the cases. Tumour cells growing in short papillae with hyalinised cores lined by clear cells with focal cytoplasmic PAS positive with diastase resistant hyalinised globules (Figure-) Our findings correlate with other studies [21][22] but Purti Agarwal et al [11] reported lower incidence in their studies.

5.3.5. Our findings of metastatic tumours (Krukenberg tumour) constituting 0.81% of all ovarian tumours and 6.67% of all ovarian cancers are comparable with that of other authors [11][12][23] but higher incidence was reported by Mukwana et al [22] and Mankar D.V. et al [12].

5.4. Tumour bilaterality: Tumour bilaterality was observed in 4.8% of the cases which is lower to the finding of other workers [4][18][21][24]. Two cases are malignant tumours. A case of bilateral benign Brenner tumour associated with bilateral serous cystadenoma was included in our study. Such tumours were also highlighted by Pschera H et al [25].

5.5. Age Incidence: Ovarian neoplasms occur in the age range of 11-76 years with the maximum incidence in 31-50 year age group. Pillai G et al [4] reported the peak incidence of ovarian tumours in the 3rd and 4th decades. Benign tumours are more common in patients <40 years of age except immature teratoma, whereas maximum malignant tumours occur after 40 years of age. Maximum number of borderline tumours occur in the 4th decade of life. The mean age at diagnosis for benign, borderline and malignant tumours in our study are 36.65±13.81, 44.63±11.12 and 40.93±15.03 respectively. Our findings for borderline and malignant tumours are comparable to that of a Brazilian study [26] however the mean age for benign tumours are higher in their studies. The mean age of borderline tumours in a study by Wang et al [27] in Singapore is 38 years.

VI. Conclusion

Ovarian tumours are one of the common ailments affecting women with wide geographic variation in the incidence. Ovarian cancers account for a disproportionate number of deaths from cancer of the female genital tract which are largely related to lack of proper screening method and late diagnosis. Health education, passive surveillance, development of a better screening method etc. will be of prime importance in detecting ovarian malignancies at an early stage. For clear understanding of the disease pattern in this north-eastern part of India, a study with a larger sample size over a longer duration of study would be needed.

References

- [1]. Jemal A, Siegel R, Xu J, Ward E. Cancer statistics, 2010. *CA Cancer J Clin.* 2010;60:277-300.
- [2]. World Cancer Research Fund. Available from: <http://www.werf.org/int/cancer-facts-figures/data-specific-cancers/ovarian-cancer-statistics>.
- [3]. Murthy NS, Shalini S, Suman G, Pruthivish S, Mathew A. Changing trends in incidence of ovarian cancer - the Indian Scenario. *Asian Pac J Cancer Prev* 2009;10:1025-30.
- [4]. Pilli G, Suneeta KP, Dhaded AV, Yenni VV. Ovarian tumours: a study of 282 cases. *Journal of Indian Medical Association* 2002;100:420-4.
- [5]. Gupta N, Bisht D, Agarwal AK, Sharma VK. Retrospective and prospective study of ovarian tumours and tumour-like lesions. *Indian J Pathol Microbiol* 2007;50:525-7.
- [6]. Ahmed Z, Kayani N, Hasan SH, Muzaffar S, Gill MS. Histological pattern of ovarian neoplasm. *J Pak Med Assoc* 2000;50:416-9.
- [7]. Shah S, Hishikar VA. Incidence and management of ovarian tumours. *Bombay Hospital J* 2008;50:30-3.
- [8]. Zaman S, Majid D, Hussain M, Chughtai O, Mahboob J, Chughtai S. A retrospective study of ovarian tumours and tumour-like lesions. *J Ayub Med Coll Abbottabad* 2010;22:104-8.
- [9]. Lubna Khan, Anita Arora, Asha Agarwal, Chayanika Pantola, Sanjay Kala, Rahul K. Rathi. Role of immunohistochemistry in ovarian tumours. *Journal of evolution of medical and dental sciences* 2014;3(11):2814-8.
- [10]. Cho SM, Byun JY, Rha SE et al. CT and MRI findings of cystadenofibroma of the ovary. *Eur Radiol.* 2004;14(5):798-804.
- [11]. Purti Agrawal, Deepak Gangadhar Kulkarni, Preeti Rihal Chakraborti, Sapna Chourasia, Mona Dixit, Kapil Gupta. Clinicopathological spectrum of ovarian tumours: A 5 year experience in a tertiary health care centre. *Journal of basic and clinical reproductive sciences.* July-Dec 2015;4(2):90-6.
- [12]. Mankar DV, Jain GK. Histological profile of ovarian tumours: A twelve year institutional experience. *Muller J MediSci Res* 2013;6(2):107-111.
- [13]. Li Y, Cui H, Shen DH, Zhao Y, Wei LH, Quian HN. Clinical and pathological features of borderline ovarian tumours. *Zhonghua Fu Chan Ke Za Zhi* 2003;38:81-4.
- [14]. Priya C, Kumar S, Kumar L. Borderline ovarian tumour: An update. *Indian J Med Paediatr Oncol* 2008;29:19-27.
- [15]. Byun JY. MR imaging findings of ovarian cystadenoma: clues for making the differential diagnosis from ovarian malignancy. *Korean J Radiol.* 2006;7(3):153-60.
- [16]. Mankar DV, Jain GK. Histological profile of ovarian tumours: A twelve year institutional experience. *Muller J MediSci Res* 2013;6(2):107-111.
- [17]. Atif Ali Hashmi, Zubaida Fida Hussain, Aneel Roy Bhagwani, Muhammad Muzzammil Edhi, Naveen Faridi, Syed Danish Hussain. Clinicopathologic features of ovarian neoplasms with emphasis on borderline ovarian tumours: an institutional perspective. *BMC Research Notes* 2016;9:205.

- [18]. Jha R, Karki S. Histological pattern of ovarian tumours and their age distribution. Nepal Med Coll J 2008;10:81-5.
- [19]. Swamy GG, Satyanarayan N. Clinicopathological analysis of ovarian tumours - a study on five year sample. Nepal Med Coll J 2010;12:221-3.
- [20]. Yasmin S, Yasmin A, Asif M. Clinicopathological pattern of ovarian tumours in Peshawar region. J Ayub Med Coll Abbottabad Tupuz S, Iylbz Kurt AC, Akhan SE, Keskin N, Yavuz E, Salihoglu Y et al. Malignant germ cell tumours of the ovary: A review of 41 cases and risk factor for recurrence. Eur J Gynaecol Oncol 2008;29:635-7.
- [21]. Ranjana Banyopadhyay, Santosh Kumar Mondal, Palash Kumar Mondal, Dipanwita Ray Nag, Suprio Roychowdhury, Swapan Kumar Sinha. Histologic pattern, bilaterality and clinical evaluation of 957 ovarian neoplasms: A ten year study in a tertiary hospital of eastern India. Journal of Cancer Research and therapeutics 2011;7(4):433-7.
- [22]. Mokwana HH, Maru AM, Lakum NR, Agnihotri AS, Trivedi NJ, Joshi JR. The relative frequency and histopathological pattern of ovarian masses - 11 year study at tertiary care centre. Int J Med Sci Public Health 2014;3:81-4.
- [23]. Zaloudek C: tumours of the ovary. Diagnostic Histopathology of tumour. Christopher DM, Fletcher DM, Fletcher Churchill Livingstone. (Philadelphia USA, 3rd edition, 2007) Vol 1, 567-627.
- [24]. Annapurna Parvatata, Ragidi Ramesh Babu, Natta Bharat Rao, K Narasimhulu. Study of ovarian neoplastic lesions. IOSR Journal of Dental and Medical Sciences July 2016;15(7):32-8.
- [25]. Pschera H, Wikstrom B. Extra ovarian Brenner tumour co-existing with serous cystadenoma: a case report. Gynecol Obstet Invest 1991;31:185-7.
- [26]. Marcela F Paes, Renata D Daltoe, Klesia P Madeira, Lucas CD Rezende, Gabriela M Sirtoli, Alice L Herlinger et al. A retrospective analysis of clinicopathological and prognostic characteristics of ovarian tumours in the state of Espirito Santo, Brazil. Paes et al Journal of ovarian research 2011;4:14.
- [27]. Wang HF, Low JJ, Chua Y, Busmanis I, Tay EH, Ho TH. Ovarian tumours of borderline malignancy: a review of 247 patients from 1991 to 2004. Int J Gynecol Cancer 2007;17:342-9.

Table – 1 Distribution Of Benign Tumours In Different Age Groups

Sl. No.	Type Of Benign Tumours	Age Groups						Total No. Of Each Tumour Type
		□ 20 Yrs	21-30 Yrs	31-40 Yrs	41-50 Yrs	51-60 Yrs	>60 Yrs	
1.	Serous Cystadenoma	0	8	12	12	6	6	44
2.	Mature Teratoma	4	18	8	8	0	0	38
3.	Mucinous Cystadenoma	2	8	1	1	1	1	14
4.	Benign Brenner	0	0	0	0	1	1	2
5.	Serous Cystadenofibroma	0	0	1	0	0	0	1
6.	Fibroma	0	0	0	1	1	0	2

Table – 2 Distribution Of Borderline Tumours In Different Age Groups

Sl. No.	Type Of Borderline Tumours	Age Groups					Total No. Of Each Tumour Type
		□ 30 Yrs	31-40 Yrs	41-50 Yrs	51-60 Yrs	>60 Yrs	
1.	Mucinous Tumours	0	1	0	1	1	4
2.	Serous Tumours	0	3	0	1	0	3
3.	Serous Cystadenofibroma	0	1	0	0	0	1

Table – 3 Distribution Of Malignant Tumours In Different Age Groups

Sl. No.	Type of malignant tumours	Age groups						Total no. of each tumour type
		□ 20 yrs	21-30 yrs	31-40 yrs	41-50 yrs	51-60 yrs	>60 yrs	
1.	Mucinous cystadenocarcinoma	0	0	1	2	1	1	5
2.	Serous cystadenocarcinoma	0	0	1	3	0	0	4
3.	Clear cell carcinoma	0	0	1	1	0	0	2
4.	Immature teratoma	2	0	0	0	0	0	2
5.	Choriocarcinoma	0	1	0	0	0	0	1
6.	Metastatic adenocarcinoma	0	1	0	0	0	0	1

Table – 4 Distribution Of Bilateral Tumours In Different Age Groups

Sl. No.	Type of tumours	Age groups						Total no. of bilateral tumours
		≤ 20 yrs	21-30 yrs	31-40 yrs	41-50 yrs	51-60 yrs	>60 yrs	
1.	Bilateral Serous cystadenoma	0	0	0	0	0	1	6
2.	Bilateral Mature teratoma	0	0	1	0	0	0	
3.	Bilateral Mucinous cystadenocarcinoma	0	0	0	0	1	0	
4.	Serous cystadenoma (left ovary) and Mature teratoma (rt ovary)	0	1	0	0	0	0	
5.	Bilateral Brenner tumour and Serous cystadenoma	0	0	0	0	0	1	
6.	Metastatic adenocarcinoma	0	1	0	0	0	0	

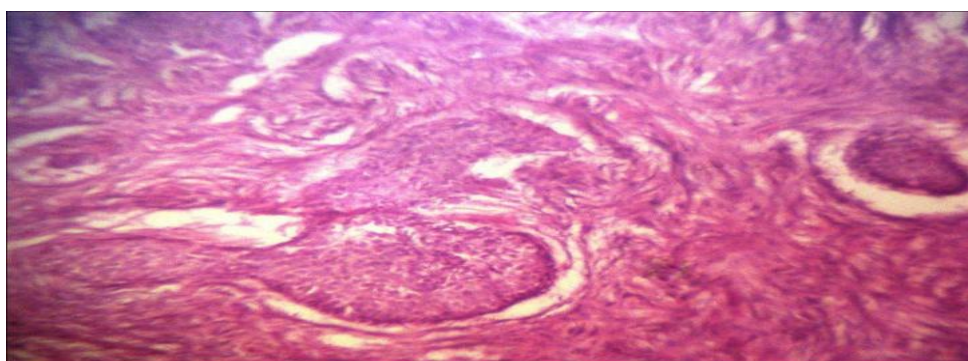


FIG 1.: BENIGN BRENNER TUMOUR - H & E X 10

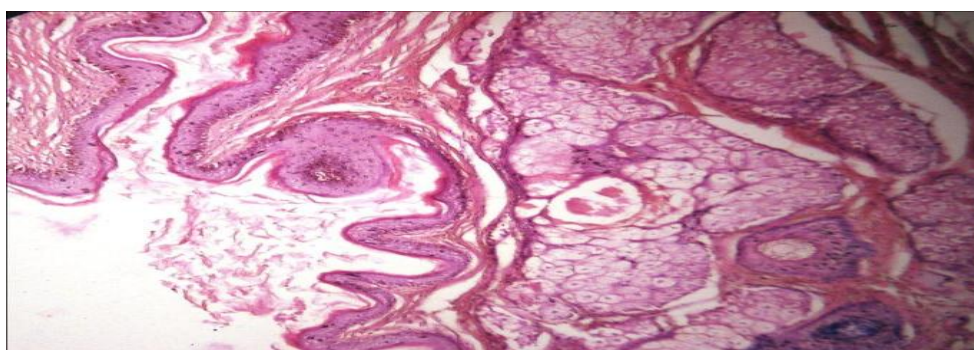


FIG 2.: MATURE CYSTIC TERATOMA - H & E X 10

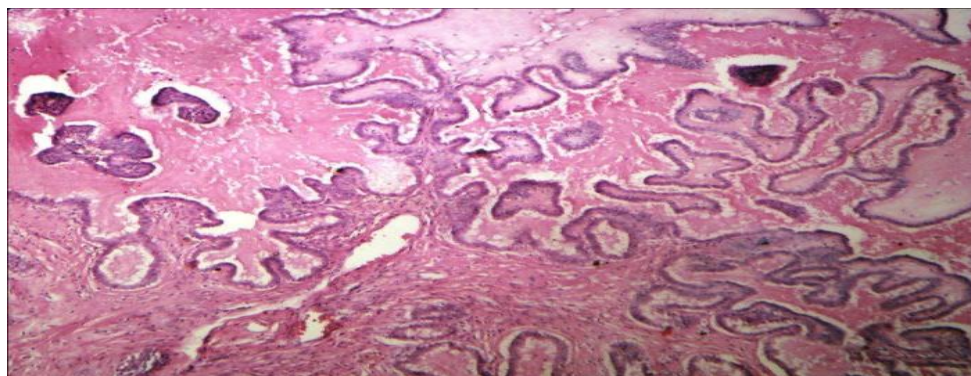


FIG 3.: BORDERLINE SEROUS TUMOUR - H & E X 10

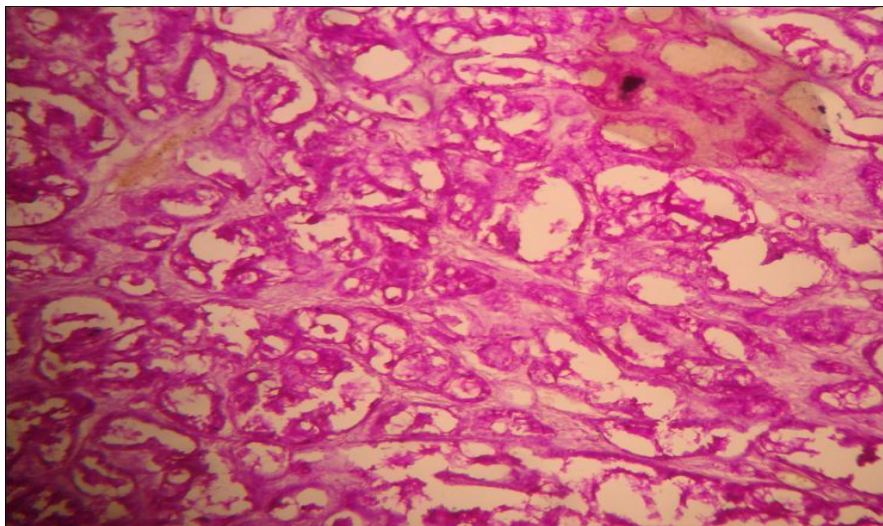


FIG 4.: CLEAR CELL CARCINOMA - PAS X 10