

F'lip'ped By Isolated orbicularis oris Muscle Cysticercosis Diagnosed on Fine Needle Aspiration Cytology- A Case Report

Dr Prachi Kukreja¹, Dr Shubhra Agarwal²

¹(Senior Resident, Department Of Pathology, Babu Jagjivan Ram Memorial Hospital, India)

²(Specialist Gr 1, Department Of Pathology, Babu Jagjivan Ram Memorial Hospital, India)

Abstract: Cysticercosis is a systemic helminthic infection endemic in India, caused by larva of cestode *Taenia solium*. It has variety of clinical features depending upon the site involved, most common sites being brain, subcutaneous tissue and skeletal muscles. It can be diagnosed by variety of diagnostic modalities like radiology, cytology and histopathology. Fine needle aspiration cytology is the preferred diagnostic tool for diagnosis of Cysticercosis in a secondary level care centre like ours due to its low cost.

Keywords: Fine needle aspiration cytology, Cysticercosis, *Cysticercus cellulosae*, Intramuscular

I. Introduction

Cysticercosis is a common infestation of human being caused by larval stage of helminth *Taenia solium* (tape pork worm).¹ The mode of infection is ingestion of tapeworm eggs from uncooked food or contaminated water.² The common sites in human body are brain, spinal cord, orbit, subcutaneous tissue and striated muscle.³ Clinical features of the patients are determined by the site and stage of development of the parasite.⁴ It is endemic in India, China, Southeast Asia, Latin America and Sub-Saharan Africa.^{5,6,7} We report a case of cysticercosis diagnosed on fine needle aspiration cytology, emphasizing its importance as a primary diagnostic tool for this disease.

II. Case Report

A 17 year old female patient presented to our department with a superficial swelling on the left side of upper lip, near the angle of mouth, since last one month. The patient had no other complaint. The clinical diagnosis offered was soft tissue tumour and the patient was sent to the pathology department for fine needle aspiration cytology. On examination the swelling was 2x2 cms, non-tender and cystic in consistency. Fine needle aspiration cytology was performed by a 24 gauge needle (without aspiration technique). It yielded purulent aspirate. The smears were air dried and stained with Giemsa stain. Ziehl Nielson stain was performed on one of the smears due to purulent nature of the aspirate to rule out Tuberculosis. On microscopy, smears showed abundant neutrophils, few lymphocytes, macrophages and eosinophils in a background of degenerated material and RBCs. Parts of bladder wall of *Cysticercus cellulosae* composed of fibrillar material with interspersed small pyknotic nuclei were present (Figure 1). The cytological diagnosis of Intramuscular Cysticercosis with superadded acute inflammation was made. The patient was given antibiotic with anthelmintic drugs by the clinicians and she responded well.

III. Discussion

Human Cysticercosis is a common infestation caused by larval stage of helminth *Taenia solium* (tape pork worm).¹ It is common in subcutaneous tissue and striated muscles, presenting as a nodule, difficult to differentiate clinically from lymphadenitis or a benign mesenchymal tumour.⁸ Infected cases present as painful lumps. Cytological examination confirms the diagnosis of cysticercosis when parts of larva scolex, parenchyma or cuticle are seen.⁹ The presence of dirty background with prominence of eosinophils and neutrophils should be taken as signs to search for a parasite in the smears. Kung et al in the year 1989 first described the diagnostic role of Fine needle aspiration cytology for cysticercosis.⁸ In the year 1995 Kamal et al reported ten cases of *Cysticercus cellulosae* diagnosed on cytology, by the presence of hooklets and fragments of wall with inflammatory background.¹⁰ Pooja et al in the year 2014 reported 137 cases of cysticercosis diagnosed on cytology by presence of parasite hooklets, parenchymatous portions, calcareous corpuscles and tegument in a background of mixed inflammatory cells, epithelioid cells and giant cells.¹¹ In the year 2016 Jashnani KD et al reported a series of five cases of subcutaneous cysticercosis diagnosed on cytology.¹² Nowadays other diagnostic tools like serology and radiological imaging may also be used. Immunodetection of cysticercosis can be attained, but the patients living in endemic countries might have antibodies secondary to exposure rather than an established infection.¹³ Due to this limitation serology may not offer a definitive diagnosis. Hence visualisation of parasite by cytology or histopathology remains the diagnostic modality of choice.

IV. Conclusion

Fine needle aspiration cytology has now established itself widely as an acceptable method for diagnosis of cysticercosis. The present case emphasises its importance as a primary diagnostic tool for diagnosis of cysticercosis, due its limited invasiveness and low cost.

References

- [1]. Vija yaraghavan SB. Sonographic appearances in cysticercosis. *J Ultrasound Med* 2004;23:423-7.
- [2]. Carpio A, Escobar A, Hauser WA. Cysticercosis and epilepsy: A critical review. *Epilepsia* 1998;39:1025-40.
- [3]. Mittal A, Das D, Iyer N, Nagaraj J, Gupta M. Masseter cysticercosis: A rare case diagnosed on ultrasound. *Dentomaxillofac Radiol* 2008; 37:113-6.
- [4]. Sahoo RK, Subudhi SK, Panda A, Pathak H, Panda S. Isolated masseter cysticercosis in a healthy woman. *J Oral Maxillofac Radiol* 2015;3:11-4.
- [5]. Elias FM, Martins MT, Foronda R, Jorge WA, Arajio NS. Oral cysticercosis : case report and review of the literature. *Rev Inst Med Trop Sao Paulo* 2005;47(2):95-8.
- [6]. Delgado-Azañero WA, Mosqueda-Taylor A, Carlos-Bregni R, Del Muro-Delgado R, Díaz-Franco MA, Contreras-Vidaurre E. Oral cysticercosis: a collaborative study of 16 cases. *Oral Surg Oral Med Oral Pathol Oral Radiol Endod* 2007; 103: 528-33.
- [7]. Ribeiroet A, Luvizotto M, Soubhia A, de Castro A. Oral cysticercosis: case report. *Oral Surg Oral Med Oral Pathol Oral Radiol Endod* 2007; 104: e56-e58.
- [8]. Kung IT, Lee D, Yu HC. Soft tissue cysticercosis diagnosed by fine needle aspiration. *Am J Clin Pathol.* 1989;92:834-5.
- [9]. Rajwanshi A, Radhika S, Das A, Jayaram N, Banerjee CK. Fine needle aspiration cytology in the diagnosis of cysticercosis presenting as palpable nodules. *Diagn Cytopathol.* 1991;7:517-9.
- [10]. Kamal MM, Grover SV;Cytomorphology of subcutaneous cysticercosis,A report of 10 cases;Acta cytol 1995;39: 40.
- [11]. Kala P, Khare P.Fine-needle aspiration cytology as a diagnostic modality for cysticercosis: A clinicocytological study of 137 cases. *J Cytol.* 2014 Apr-Jun; 31(2): 68-72.
- [12]. Jashnani KD, Desai HM, Shetty JB, Pandey I. Fine-needle aspiration cytology of subcutaneous cysticercosis: A series of five cases. *Ann Trop Med Public Health* 2016;9:73-5.
- [13]. Patel K, Shah M, Patel B, Doshi N. Subcutaneous oral cysticercosis. *National J Community Med* 2011;2(2):311-3.

Figures

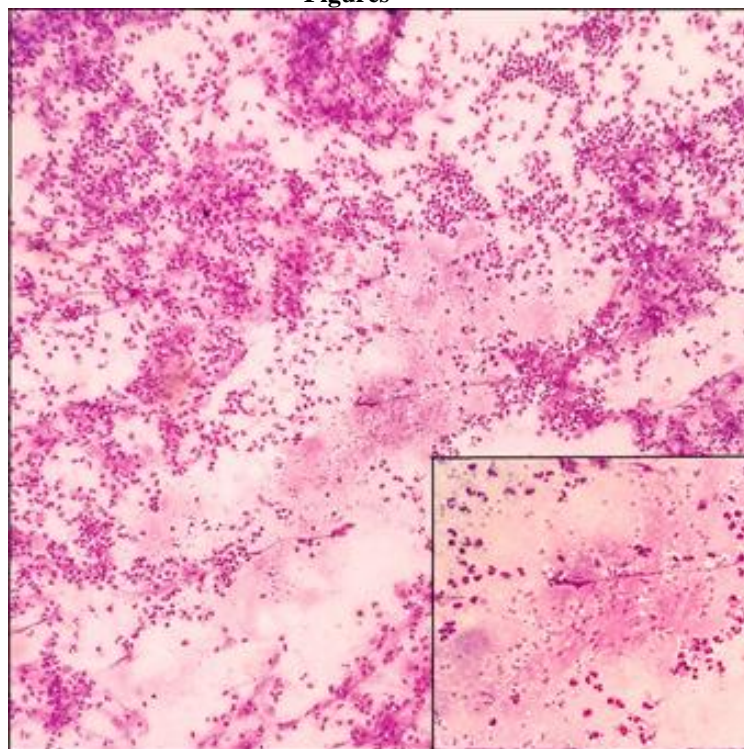


Figure 1: Parts of bladder wall of *Cysticercus cellulosae* composed of fibrillar material with interspersed small pyknotic nuclei (Giemsa 100x), inset (Giemsa 400x)