

Aneurysmal Bone Cyst in Dorsal Spine

^{1*}Dr Rohan Gaur,²Dr Hemant Mishra

Department Of Radiodiagnosis. Mahatma Gandhi Medical College And Hospital, Jaipur, Rajasthan

Corresponding Author: *Dr Rohan Gaur

Abstract: Aneurysmal bone cyst is a benign cystic lesion of bone known since 1942 mainly involving the long bones. We present a rare case report of 32 year old female with complaint of upper back ache. It was diagnosed on basis of MRI findings and then surgically excised and confirmed on histopathological examination.

Keywords: Aneurysmal bone cyst, benign, osteolytic lesion

Date of Submission: 29-07-2017

Date of acceptance: 30-09-2017

I. Background

Aneurysmal bone cyst (ABC) is a rare benign expansile osteolytic lesion of unknown etiology [1]. It affects in second and third decades of life [2, 3]. It commonly affects metaphysis of long bone of lower extremity. Primary ABCs represent 1.4 % of primary bone tumors and the vertebral column, especially lumbar area and posterior elements are involved in 3–30 % of cases [4, 5]. Patient usually present with pain, swelling, mass or pathological fracture or combination of symptoms of the affected site. Diagnosis can be made by radiographs, computed tomography (CT), magnetic resonance imaging (MRI). Direct radiographs show an expansile lytic lesions. Fluid–fluid levels may be seen on both CT and MRI [6]. Management of ABCs of spine are surgical resection, radiation therapy, cryotherapy, and embolization [7].

Case Presentation

A 32 years old female patient presented with complaints of upper backache since 3 months. Pain was insidious in onset, aggravates on working and relieved on taking rest. Patient had no history of trauma. Patient was further investigated. MRI scan of thoraco-lumbar spine was done. It showed an expansile mass lesion measuring 15 X 22 X 34 mm (AP X TD X CC) involving posterior elements (pedicle, lamina and transverse process on left side) of D4 vertebral body. The lesion appeared hyperintense on T2W with hemorrhagic/fluid levels and hypointense on T1W sequences. The lesion caused severe compression over thecal sac and displaced cord antero-superiorly at this level. The lesion showed contrast enhancement with flow voids within. It also showed extension to left D4-D5 neural foramina. Lateral recesses were free. These findings were suggestive of Aneurysmal bone cyst. It was surgically excised and sent for histopathological examination. Histopathologically, the lesion appeared to have a biphasic pattern with cystic and solid areas. Multi cystic architecture was separated by thick septa. These cyst varied in size and contained red blood cells. Solid areas consisted of stroma cells, blood vessels, giant cell and mononuclear cells. Thus, diagnosis of aneurysmal bone cyst was confirmed.

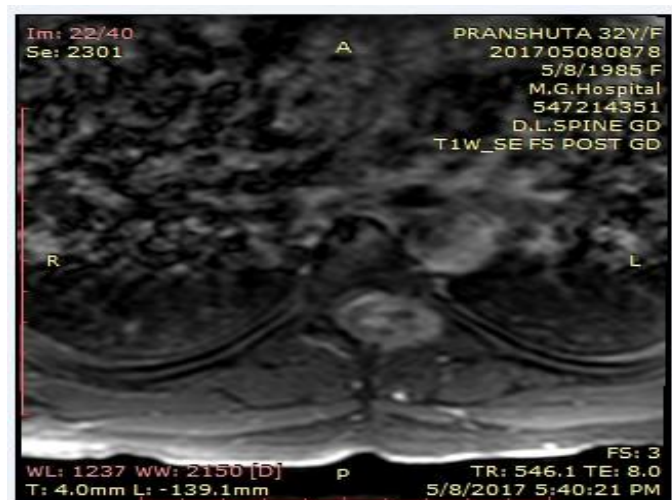
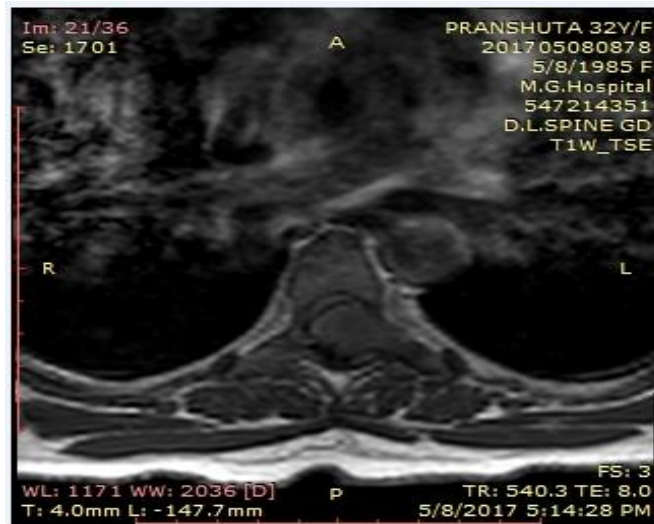
II. Discussion

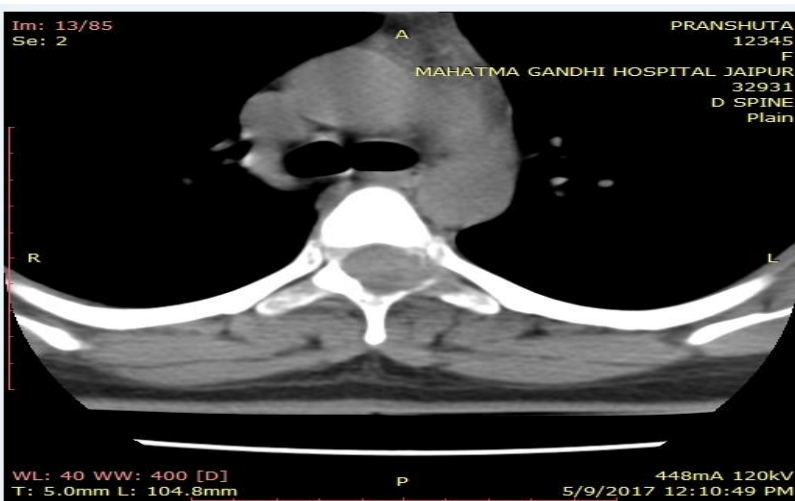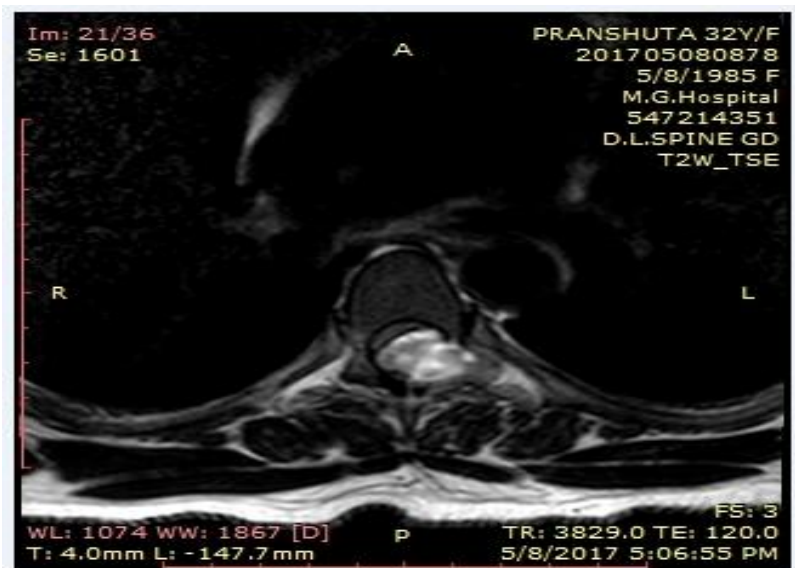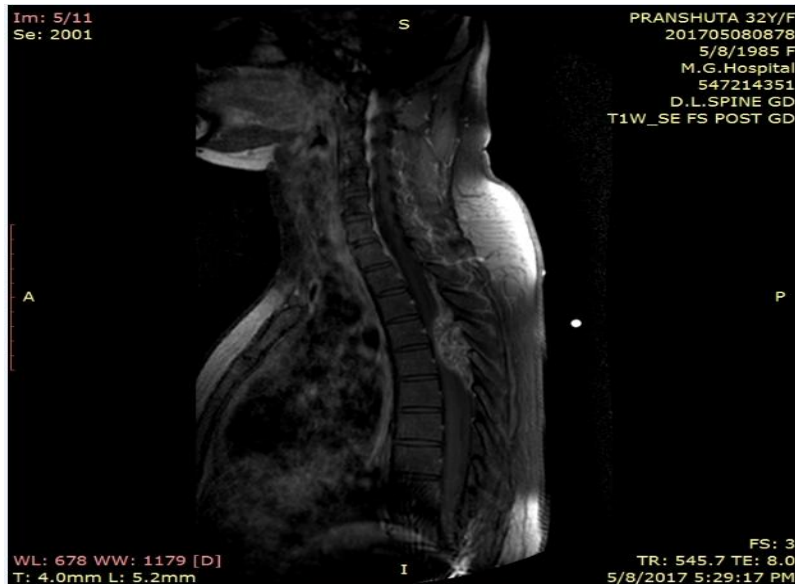Aneurysmal bone cyst is a non-neoplastic tumour consisting of blood filled cyst of variable size. The term aneurysm is derived from macroscopic appearance “sponge like tumour “containing giant cells. It was first described as an intraosseous osteolytic lesion chiefly affecting metaphysis of long bones by Jaffe and Lichtenstein in 1942 [1]. It involves sacral and thoracic region less frequently. Bone cyst in our case is present in thoracic region and very few cases are reported till now in literature [8]. The prevalence of ABCs is 1.4 cases per 100,000 individuals, and they constitute approximately 1 % of all bone tumors [4, 5]. The lesions primarily occur in the first two decades of life, with slight female predominance (1.5:1) [2, 3]. The exact etiology is not known. It is believed that they occur due to vascular malformation within the bone. They may present as swelling, mass, pain, pathological fractures or with neurological manifestations. The clinical history in our case correlated with these findings. Diagnosis is established on the basis of chest x-ray, CT, MRI findings. CT scan imaging reveals lytic lesion. On MRI imaging, aneurysmal bone cyst usually demonstrate a thin, well defined rim of low signal intensity in the periphery and they are seen as multiseptate lesions. Usually each lobule represents different signal characteristics giving the tumor a heterogeneous appearance. Fluid levels may be seen. MRI is modality of choice. Our case report also showed fluid levels and hypointense and hyperintense areas.

Treatment of ABCs are curettage with or without bone grafting, complete excision, arterial embolization, intralesional drug injections (steroid and calcitonin), and radiation (9, 10). Success rate is high if diagnosis and management is done on right time (11). Total excision with or without instrumentation is the optimal approach for local control of tumor and it prevents recurrence.

Bibliography

- [1]. 1.Jaffe HL, Lichtenstein L. Solitary unicameral bone cyst with emphasis on the roentgen picture, the pathologic appearance and the pathogenesis. Arch Surg. 1942;44:1004–25.
- [2]. 2. Pennekamp W, Peters S, Schinkel C, Kuhnen C, Nicolas V, Muhr G, Frangen TM. Aneurysmal bone cyst of the cervical spine. EurRadiol. 2008;18:2356–2360. doi: 10.1007/s00330-008-0944-7
- [3]. 3.Ameli NO, Abbassioun K, Saleh H, Eslamdoost A. Aneurysmal bone cyst of the spine. Report of 17 cases. J Neurosurg. 1985;63:685–90.
- [4]. 4. Leithner A, Windhager R, Lang S, Haas O, Kainberger F, Kotz R. Aneurysmal bone cyst. A population based epidemiologic study and literature review. ClinOrthopRelat Res. 1999;363:176–179. doi: 10.1097/00003086-199906000-00023
- [5]. 5.Boriani S, De Iure F, Campanacci L, et al. Aneurysmal bone cyst of the mobile spine: report on 41 cases. Spine. 2001;26:27–35. doi: 10.1097/00007632-200101010-00007.
- [6]. 6.Tsai JC, Dalinka MK, Fallon MD, Zlatkin MB, Kressel HY. Fluid–fluid level: a nonspecific finding in tumors of bone and soft tissue. Radiology. 1990;175(3):779–782
- [7]. 7.Papagelopoulos PJ, Currier BL, Shaughnessy WJ, et al. Aneurysmal bone cyst of the spine. Management and outcome. Spine. 1998;23:621–628. doi: 10.1097/00007632-199803010-00018
- [8]. 8. Rajadhyaksha C, Connolly LP, Connolly SA, Treves ST. Aneurysmal bone cyst of the sacrum: value of three-phase imaging. ClinNucl Med. 2003;28(11):933–935.
- [9]. 9. Tsai JC, Dalinka MK, Fallon MD, Zlatkin MB, Kressel HY. Fluid–fluid level: a nonspecific finding in tumors of bone and soft tissue. Radiology. 1990;175(3):779–782
- [10]. 10.Weinstein JN. Differential diagnosis and surgical treatment of primary benign and malignant neoplasm. In: Frymoyer JW, editor. The adult spine: principles and practice. New York: Raven Press; 1991. pp. 830–850.
- [11]. 11. Garg S, Mehta S, Dormans JP. Modern surgical treatment of primary aneurysmal bone cyst of the spine in children and adolescents. J PediatrOrthop. 2005;25(3):387–392. doi10.1097/01.bpo.0000152910.16045.ee





*Dr Rohan Gaur. "Aneurysmal Bone Cyst in Dorsal Spine." IOSR Journal of Dental and Medical Sciences (IOSR-JDMS) 16.10 (2017): 08-10