

Endodontic Retreatment of Mandibular First And Second Premolars With two Roots: A Case Report

*Nadira.K.Rahman¹, Dr. Jayasree S.² Muhammed Abdul Rahman T.V³,
Gokulraj R⁴, Nimmy.S.Mukundan⁵, Jamshina.K⁶

¹(Department, of conservative Dentistry Govt Dental College/ kozhikkode)

Corresponding Author: *Nadira.K.Rahman

Abstract The success of endodontic therapy is based on correct diagnosis and treatment planning, proper knowledge of anatomy and morphology of root canal system and thorough debridement and obturation. Variations in the root canal anatomy are a commonly occurring phenomenon. Mandibular first and second premolars are commonly single rooted teeth with a complicated endodontic anatomy, variations have to be considered every time endodontic therapy is performed. This case report describes the non-surgical endodontic retreatment performed on a mandibular first and second premolar with two roots.

Keywords: Retreatment, Root canal anatomy.

Date of Submission: 09 -10-2017

Date of acceptance: 27-10-2017

I. Introduction

Most of the difficulties that occur during root canal treatments are due to variations in root canal anatomy. Anatomical variations, especially extra canals and roots, should always be kept in mind while doing treatment for a successful endodontic outcome. A poorly cleaned and obturated canal will lead to failure of the endodontic therapy in a very short time. A clinician can suspect unusual morphology by a radiograph which offers a clue of additional roots and canals or clinically when he encounters unusual morphology of the pulp chamber of the tooth. Extra roots are an additional challenge, which begins at case assessment and involves all operative stages, including access cavity design, canal access, localization, biomechanical preparation and obturation of the root canal system¹.

Hoehn and Pink in their analysis on teeth requiring retreatment, found that 42% incidence of missed roots or canals in mandibular first premolars, which is often called as "Endodontist's enigma,"². It may present the greatest difficulty of all teeth to perform root canal treatment. Numerous reports of root canal variations in these teeth have been reported in the literature. Vertucci in his series of study conducted on extracted teeth, reported 25.5% of mandibular first premolar had two canals and 2.5% of mandibular second premolar had two canals. According to Ingle, mandibular second premolars have only 12% chance of second canal, 0.4% of a third canal and Hartly has reported 11% possibility of second canal³. This case report describes the orthograde endodontic retreatment performed on a mandibular first and second premolars with two roots and canals, diagnosed with periapical lesion.

II. Case Report

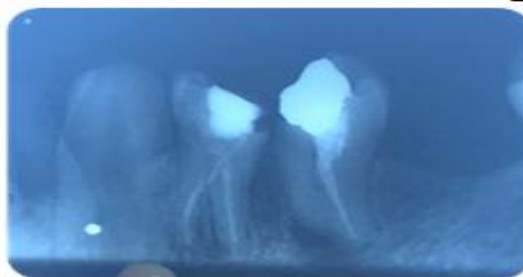

Fig 1: preoperative radiograph

A 21-year-old male patient was reported to the department of Conservative Dentistry and Endodontics at Govt Dental College kozhikkode, with a chief complaint of pain in the posterior right mandibular tooth for the past 2 weeks. Patient's medical history was non-contributory. Patient had a history of root canal treatment for that particular tooth 3 years back. Clinical examination revealed a class II amalgam filled right

mandibular first and second premolar. The tooth was tender on percussion. Preoperative Intraoral periapical radiograph confirmed that the patient had a deficient previous root canal treatment on the mandibular left first and second premolar with incomplete root canal fillings on both mesial and distal roots, with chronic apical periodontitis [Figure 1]

Endodontic retreatment was decided after clinical and radiographic examination. After giving local anaesthesia with 2% lignocaine with epinephrine (1:100000), the tooth 44 and 45 was isolated with rubber dam and clamp (Hygenic, Coltene Whaledent, USA). The access cavity was refined with a round diamond bur in a high speed airotor handpiece. The former coronal restorations was removed pulp chamber was inspected. When exposing the pulp chamber floor, a lot of debris, sealer and gutta-percha were observed. The pulp chamber was thoroughly rinsed with 3% sodium hypochlorite solution and the pulpal floor was carefully observed with the help of a magnifying loupe (Seiler loupes). The canal fillings were former performed with gutta-percha and sealer. The retreatment was done after removing the gutta purcha with ProTaper Universal System (Dentsply Maillefer, Ballaigues, Switzerland) After obtaining the canal patency, a #10 K file (Dentsply, Maillefer) was inserted to confirm the root canal configuration. A working length was confirmed using an apex locator. Cleaning and shaping of the canals was performed using crown-down technique under copious irrigation with 5.25% sodium hypochlorite solution. The canals were dried and calcium hydroxide was given as intra canal medicament and the tooth was temporized.

In the second appointment, the calcium hydroxide dressing was removed, the canals were rinsed and filed. The canals were irrigated again, dried with sterile -paper points and the gutta-percha master cones (F2, size 25), were cut to fit at 0.5 mm of the working length for each root canal [Figure 2]. Each selected master cone was then cemented into the corresponding root canal with AH Plus sealer (Dentsply Maillefer, Ballaigues, Switzerland). Post endodontic restoration was given with amalgam. and a post obturation radiograph was taken [Figure 3].

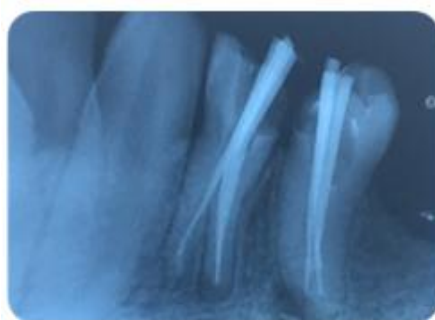


Fig 2: mastercone radiograph

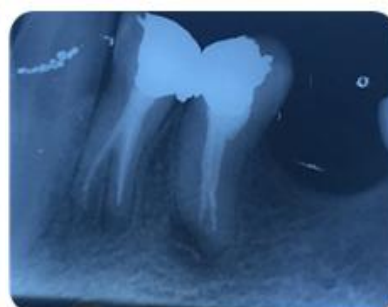


Fig 3: post operative radiograph

III. Discussion

Endodontic treatment failures can be due to inadequacies in cleaning, shaping, and obturation, or can be due to some iatrogenic errors, or due to re-infection of the root canal system when the coronal seals has been lost after completion of root canal treatment. Regardless of the etiology, the sum of all causes is leakage and bacterial contamination. The goals of nonsurgical retreatment are to remove materials the obturating material from the root canal space and if present, address deficiencies or repair defects that are pathologic or iatrogenic in origin⁴. A successful root canal treatment is achieved through a thorough mechanical and chemical debridement of the root canal followed by sealing the entire root canal system completely by a three-dimensional obturation with an inert filling material and a final coronal restoration, thereby preventing from ingress of microorganisms to the root canal system⁵. Careful assessment of the pre-operative radiograph is an important step for root canal preparation and obturation. High quality pre-operative radiographs and their careful evaluation are essential for the detection of any abnormal morphology and help in endodontic treatment planning. Radiographs in different angulations will provide proper information about the presence of any additional roots⁶. Therefore, clinicians should be familiar with the common root and root canal morphology and its possible variations in the different teeth groups before commencing endodontic treatment.

Mandibular premolars are often stated to be the most challenging teeth to treat endodontically with aberrant anatomy, especially when they present with multiple roots or canals. The textbook description of the mandibular first premolar is typically of a single-rooted tooth⁷. Two-rooted, three-rooted and four-rooted varieties have also been reported, but are rare. Zillich and Dowson reported 23.1% of mandibular first

premolars had two or three root canals radiographically.⁸ Wilcox reported two roots in 25% of mandibular first premolars and 12% in mandibular second premolars.⁹ There is a mesio distal division of the main canal in the middle third of the root in each of these teeth. Using paralleling technique periapical radiographs, Serman & Hasselgren (1992) reported a high incidence (18.1%) of multiple roots and canals in mandibular premolar teeth in a series of radiographic surveys with mandibular first premolars involved in 15.7% of patients and mandibular second premolars in 7% of patients¹⁰

Teeth with extra roots and/or canals pose a particular challenge. Inability to identify and treat these additional root canals may cause treatment failures. Careful examination of preoperative radiographs can aid in locating additional canal or roots. Thus, root canal therapy of these teeth should be carried out by using x-rays from different angulations, efficient explorers, wider access openings, adequate illumination and, whenever possible, image magnification.¹¹

IV. Conclusion

The clinician should have a thorough knowledge about the root canal anatomy and its variations should be able to identify the presence of unusual numbers of roots and their morphology. There for necessary precautions have to be taken during root canal therapy of teeth and hence instrumentation of these canals was carried out using nickel titanium files, due to their flexibility, lesser risks of ledge formation and perforations By careful interpretation of the radiograph, and close clinical inspection of the floor of the chamber and proper modification of access opening are essential for a successful treatment outcome.

Reference

- [1]. Mohamed Idris, Nasil Sakkir, Nandakishore kj, Annapurna kini Endodontic Retreatment of a Mandibular Second Molar with four Separate Roots: A Case Report Journal of Clinical and Diagnostic Research. 2014 Mar, Vol-8(3): 280-282
- [2]. Pratima Shenoi, Wannala Mute, Archana Kandhari, Rahul Atara Endodontic Treatment of Mandibular Second Premolars with occult canals Using CBVT International Journal Of Dental Clinics, 2011: 3 (4); 68-69.
- [3]. S Nandini, Suma Ballal, Sowmya N Kumar, D Kandaswamy Two-rooted mandibular second premolars: Case report and survey Case. *Indian J Dent Res* 2008;19:70-73
- [4]. Sadia Tabassm and Farhan Raza Khan ,failure of endodontic treatment the usual suspects, *European Journal of Dentistry* 2016,10(1);144-147.
- [5]. Vertucci FJ. Root canal morphology and its relationship to endodontic procedures. *Endodontic Topics*. 2005;10:3–29
- [6]. Slowely RR. Radiographic aids in the detection of extra canals. *Oral Surg, Oral Med Oral Pathol* 1974;37:762-72
- [7]. Cleghorn BM, Christie WH, Dong CCS. The Root and Root Canal Morphology of the Human Mandibular Second Premolar: A Literature Review. *J Endod*. 2007;33(9):1031–7.
- [8]. Lu T, Yang S, Pai S. Complicated Root Canal Morphology of Mandibular First Premolar in a Chinese Population Using the Cross Section Method. 2006;32(10):932–6.
- [9]. Serman NJ, Hasselgren G. The radiographic incidence of multiple roots and canals in human mandibular premolars. *Int Endod J*. 1992;25(5):234–7.
- [10]. B. M. Cleghorn¹, W. H. Christie² & C. C. S. Dong³ Anomalous mandibular premolars: a mandibular first premolar with three roots and a mandibular second premolar with a C-shaped canal system. *International Endodontic Journal*, 41, 1005–1014, 2008.
- [11]. Nidhi Shrivastava¹, Marisha Bhandari Endodontic management of mandibular second premolar with three roots and three root canals: A case report *India journal of orofacial sciences* 2014, 6 (1) : 73-75

*Nadira.K.Rahman. “Endodontic Retreatment of Mandibular First And Second Premolars With two Roots: A Case Report.” *IOSR Journal of Dental and Medical Sciences (IOSR-JDMS)* , vol. 16, no. 10, 2017, pp. 82–84.