

## Spinal Tuberculosis with Chronic Discharging Sinus in right Paravertebral Lower Back Region: A Case Report

Das S<sup>1</sup>, Islam MM<sup>2</sup>, Subhan KI<sup>3</sup>, Howlader MRA<sup>4</sup>, Dey S<sup>5</sup>, Mahbub H<sup>6</sup>

<sup>1</sup>Dr. Sukriti Das, MBBS, FCPS (Surgery), FRCSEd, MS (Neurosurgery), Associate professor, Department of Neurosurgery, Dhaka Medical College.

<sup>2</sup>Dr. Md. Manirul Islam, MBBS, MS (Neurosurgery), IMO, Department of Neurosurgery, DMCH.

<sup>3</sup>Dr. Kazi Irfan Subhan, MBBS, MS resident, Department of Neurosurgery, DMC.

<sup>4</sup>Dr. Md. Reaz Ahmed Howlader, MBBS, MS Neurosurgery (Final part student), DMC.

<sup>5</sup>Dr. Sarbori Dey, MBBS, FCPS, Consultant, BSSMU.

<sup>6</sup>Dr. Hasan Mahbub, MBBS, Resident Phase-B, Neurosurgery, DMC.

Correspondence: Dr. Sukriti Das,

**Abstract:** Spinal tuberculosis (Tubercular Spodylitis) is a common extrapulmonary manifestation accounting 50% of skeletal tuberculosis. We reported a case of spinal tuberculosis in a 27 years old man with neurological manifestation with unusual right paravertebral chronic discharging sinus in the lower back region. He was presented with pain on the upper dorsal and swelling in the lower back with spastic paraparesis with muscle grade 3/5, exaggerated jerk with no sensory involvement in lower limbs for 2 months. He was inadvertently drained in surgical outpatient department and subsequently developed chronic discharging sinus. MRI dorsal region revealed an eroding lesion C7/D1 level with paravertebral abscess. A surgical decompression without fixation of dorsal pedicle. Biopsy and Gene Xpert was done and confirmed as mycobacterium. Immediately after surgical intervention in the upper dorsal level, discharging sinus gradually obliterated and neurological grade improved. Finally in our country: any patient with dorsolumbar paravertebral swelling neurological evaluation of whole spine have to be done before incision will reduce morbidity and mortality.

**Keyword :** Tuberculous spondylodiscitis, Dorsal spine, Paravertebral swelling.

Date of Submission: 09 -10-2017

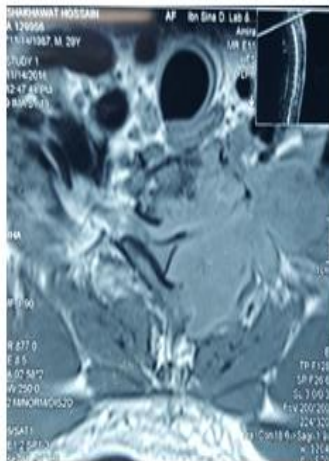
Date of acceptance: 28-10-2017

### I. Introduction

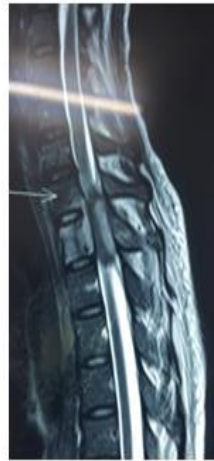Spinal tuberculosis (Tuberculous spondylitis also called Pott's spine or Pott's disease) is a common extra pulmonary manifestation of tuberculosis (TB), accounting for 50% of skeletal TB [1]. Although spinal TB has become relatively uncommon in the advance western world, the incidence has been increasing in the third world. Since the symptoms and the features of individual TB vary greatly, spinal TB is often misdiagnosed. Usually two or more contiguous vertebrae are involved in spinal tuberculosis due to haematogenous spread through one vertebral artery feeding two adjacent vertebrae [3,4]. Noncontiguous, multiple, remote involvement of tuberculosis is relatively rare. Current research indicates the incidence of multiple-level noncontiguous vertebral tuberculosis is 1.1% [7]. We present a case of spinal tuberculosis in 27-year-old man with neurological manifestation with unusual paravertebral chronic discharging sinus in the lower back region.

### II. Case report

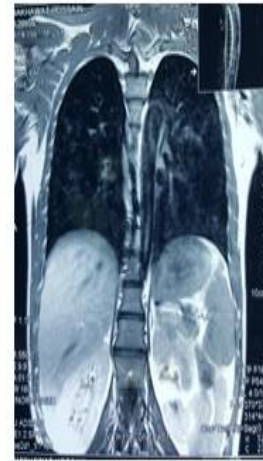
A 27 year old man got admitted into DMCH in our neurosurgery department with complaints of progressive weaknesses of both lower limbs for three weeks and a discharging sinus in the right lower back. He also complained of pain in the upper dorsal region for 15 days. He had lost some weight and also had lost his appetite for the past two months. He did not give any history of fever, night sweats, cough or haemoptysis. None of his relatives ever suffered from TB but he once had a coworker who was a diagnosed case of tuberculosis. On examination he was found to be a young man of average body built. General examination revealed that all the parameters were within normal limits. His lower limbs were spastic paraparesis with muscle power grade of 3/5. All the jerks were exaggerated in the lower limbs but there was no clonus. Sensory evaluation revealed no abnormalities. He had tenderness over the upper dorsal spine but no gibbus. There was an unhealthy wound over the right lower dorsal region which had slough all over it and serous discharge coming out of it. He states that 2 (two) months back he had a right paravertebral swelling over the lower dorsal region and which was unduly drained in the surgical outpatient department without any prior investigations. Since then he has been undergoing regular dressing but to no improvement. His ESR was 116 but chest X ray was negative for tuberculosis.



Pre operative MRI ( Axial)

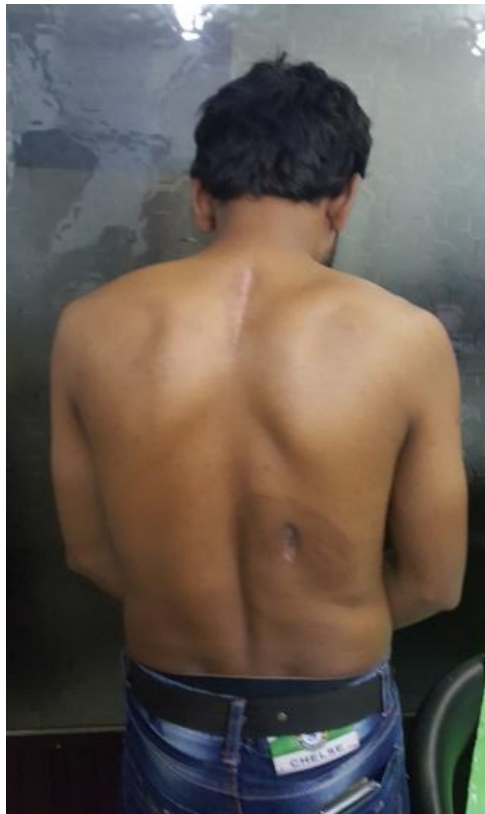

Pre operative MRI ( Sagittal)



Pre operative MRI ( Coronal)

MRI of the spine revealed a lesion eroding the D1 left hemilaminae at the C7-D1 level which was hypo intense in T1 weighted image and hyper intense in T2 suggesting an abscess. We explored the lesion by standard technique and as soon as we reached the D1 lamina semisolid pus like cheesy material came out. Laminectomy wasn't necessary as the lesion had already destroyed most of it. Liquid pus and debris from abscess cavity were collected and sent for both histopathology and geneXpert. After evacuating the cavity we tried to remove all of the capsule in piecemeal fashion. Vigorous saline irrigation was given and the wound was closed maintaining all haemostatic protocol. Biopsy from the cavity wall revealed granulomatous lesion consistent with tubercular spondylitis. GeneXpert also detected mycobacterium tuberculosis which was not resistant to rifampicin thus confirming our diagnosis of spinal tuberculosis. Patient was advised to start anti-koch treatment. Post operatively his Paraparesis improved and he started walking with support. Now after one month post operatively the discharging sinus in the lower dorsal level has almost healed and he is improving gradually with physiotherapy.



Postoperative photograph of the patient

### **III. Discussion**

Spinal tuberculosis has been both a historical and a current problem. It was found in archaeological materials dating back to the Stone Age period and the historical culture of Peruvian Indians [3]. In the modern era, Sir Percival Pott (1779) described tuberculous spondylitis with a triad of signs, i.e., gibbus, abscess and paralysis (3,6). The results of Koch's discoveries and the use of conservative therapy improved the chances of survival for patients with tuberculosis [3]. Para-vertebral abscess formation is commonly seen, usually presenting far away from the vertebral column along the facial planes or along the course of neurovascular bundles [2]. It may present in the para spinal regions at the back, in the posterior or anterior cervical triangles or along the intercostal spaces on the chest wall. Abscesses from dorsolumbar and lumbar spine track down the psoas sheath [2].

Spinal tuberculosis is the result of hematogenous dissemination from a primary focus. The detection of primary focus or visceral tuberculosis is reported in between 40% to 50% of cases [5], whereas an Indian series reports the detection of primary focus in only up to 12% of cases [2]. In our patient, no primary focus could be detected. The diagnosis of spinal TB has been based upon a combination of clinical and radiological findings. MRI is considered to be the most accurate as it allows for identification of not only bone destruction but also granulomatous tissue and tuberculomas, which may not be apparent on plain radiographs or CT. There are several imaging findings suggestive of spinal TB. Decreased signal intensity of affected bone and soft tissues on T2-weighted images with an associated thin rim enhancement of increased intensity is a pathognomonic sign for caseating necrosis or a cold abscess in TB [6]. Regardless of imaging, confirmation of the disease requires biopsy demonstrating acid-fast bacilli on microscopy or isolated culture of the organism. In contrast with pulmonary TB, extra pulmonary TB lesions have a lower amount of bacilli, resulting in less accurate results from microscopy [7]. GeneXpert PCR has been an effective diagnostic tool for pulmonary TB and is now thought to have high sensitivity and specificity for extra pulmonary TB as well. Compared to culture, gene Xpert allows for a more rapid diagnosis and greater sensitivity even when small amounts of bacilli are present, as it was in our case.

As with most other forms of extra pulmonary TB, antitubercular chemotherapy is the mainstay of treatment for spinal TB. However, there is no standardized regimen or known optimal duration of treatment. Therapy should initially include isoniazid, rifampicin, pyrazinamide, and either ethambutol or streptomycin and can be modified based on results of susceptibility testing. Varying treatment durations ranging from 6 to 18 months have been reported [7]. We advised our patient to complete the 18 month regime.

The conservative approach with medical therapy is preferred for early disease, but surgical intervention may be needed to prevent neurological consequences. Neurosurgical interventions can allow for correction of deformities, abscess debridement, spinal cord decompression, or permanent spinal stabilization [7]. Spinal TB has a rather insidious course which often leads to greater diagnostic delay. The absence of fever, inflammatory changes, and constitutional symptoms further leads clinicians to prematurely exclude TB from their differential. Later diagnosis of the disease has been associated with a worse prognosis and a greater need for surgical intervention. Although advances in MRI should expectedly improve diagnosis time, the diagnostic delay for spinal TB has remained stable. The course of treatment in our patient described in this report shows several mistakes which resulted in that the diagnosis of tuberculous spondylitis was made very late. This can apparently happen in other developed countries too [4]. Because an occurrence of tuberculosis is generally not taken into account, the chest x-ray was underestimated, no modern laboratory tests were used before draining the paravertebral abscess, not even a single blood count. Another serious omission was that the dynamics and manifestation of his disease which were typical of TB passed unnoticed. All these failures caused unnecessary psychological stress to the patient and delayed the causal treatment. The case reported here showed the complexity of diagnostic procedures necessary to reveal tuberculous spondylitis and the importance of clinical vigilance against the increasing incidence of spinal tuberculosis in our country. In patients with a dorsolumbar paravertebral abscess, tuberculous spondylitis should be suspected and thorough epidemiological, clinical and laboratory examinations be carried out and appropriate treatment introduced as soon as possible.

### **IV. Conclusion**

In our country, surgeons tend to drain abscesses without prior investigations. Paravertebral abscess should be drained after proper whole spinal evaluation. This can subsequently prevent the significant neurological complications and good surgical outcome can be achieved. Considering the diagnosis of TB and carefully assessing risk factors can avoid delays in its diagnosis and management.

### **References**

- [1]. CDC—TB—Data and Statistics, Cdc.gov, 2016, <http://www.cdc.gov/tb/statistics/default.htm>.
- [2]. C. Scott, H. L. Kirking, C. Jeffries, S. F. Price, and R. Pratt, "Tuberculosis trends—United States, 2014," *Morbidity and Mortality Weekly Report*, vol. 64, no. 10, pp. 265–269, 2015.

- [3]. J. Bennett, R. Dolin, and B. M. Mandell, Douglas, and Bennett's Principles and Practice of Infectious Diseases, Elsevier Health Sciences, London, UK, 2014.
- [4]. R. K. Garg and D. S. Somvanshi, "Spinal tuberculosis: a review," *The Journal of Spinal Cord Medicine*, vol. 34, no. 5, pp. 440–454, 2011.
- [5]. M. F. Ferrer, L. G. Torres, O. A. Ramirez, M. R. Zarzuelo, and N. Del Prado González, "Tuberculosis of the spine. A systematic review of case series," *International Orthopaedics*, vol. 36, no. 2, pp. 221–231, 2012.
- [6]. M. R. Rasouli, M. Mirkoohi, A. R. Vaccaro, K. K. Yarandi, and V. Rahimi-Movaghar, "Spinal tuberculosis: diagnosis and management," *Asian Spine Journal*, vol. 6, no. 4, pp. 294–308, 2012J.
- [7]. D. Colmenero, J. D. Ruiz-Mesa, R. Sanjuan-Jimenez, B. Sobrino, and P. Morata, "Establishing the diagnosis of tuberculous vertebral osteomyelitis," *European Spine Journal*, vol. 22, no. S4, pp. S579–S586, 2013.
- [8]. P. Merino, F. J. Candel, I. Gestoso, E. Baos, and J. Picazo, "Microbiological diagnosis of spinal tuberculosis," *International Orthopaedics*, vol. 36, no. 2, pp. 233–238, 2012.

\*Dr. Sukriti Das. "Spinal Tuberculosis with Chronic Discharging Sinus in right Paravertebral Lower Back Region: A Case Report." *IOSR Journal of Dental and Medical Sciences (IOSR-JDMS)* 16.10 (2017): 66-69