

Comparison between Light microscopy and LED microscopy in a tertiary care teaching institute in Kolkata – a pilot study

Dr. Sudipta Pandit¹, *Dr. Debabrata Saha¹, Dr. Subhajit Ghosh¹,

Dr. Avradip Santra¹, Dr. Amitabha Sen¹

(Department of Respiratory Medicine, Medical College, Kolkata, India)

Corresponding Author: *Dr. Debabrata Saha

Abstract:

Background: Tuberculosis (TB) continues to be a grave public health problem in India and across the world. Sputum microscopy is the most reliable, easy and practical method to diagnose TB. With advent of new technology Light Emitting Diode (LED) microscopes have replaced light microscopy as the main tool for diagnosis.

Aims: In this study, we evaluated efficiency of LED microscopy over light microscopy in diagnosis of TB through sputum smear.

Methods and Materials: The study was conducted in the designated microscopy centre (DMC) of Calcutta Medical College under department of Pulmonology. LED microscopy was introduced in August, 2012. Data from TB registrar was retrospectively collected from January, 2009 to December, 2016. Data analysed for overall efficiency of LED microscopy over light microscopy in respect to average new TB suspects examined, total slide examined and slide positivity rate.

Statistical Analysis Used: To compare the efficiency of both the methods, comparison of two means are statistically calculated by two sample t-test along with calculation of p value and Confidence Interval (CI).

Results: LED microscopy has shown better efficacy in increasing average number of new TB cases examined as well as total slides examined per month. Light microscopy and LED microscopy are similar in achieving slide positivity but given the load of TB patients in India, LED microscopy proved to be time saving and a better alternative to light microscopy.

Conclusion: Sputum smear microscopy is faster with LED microscope resulting into more number of new cases and more number of sputum slides to be examined within a given period of time.

Key Words: Auramine staining, Light Emitting Diode (LED) microscopes, Light Microscope, Tuberculosis, TB suspect, Sputum smear microscopy, Z-N staining.

Running Title: Comparison between Light microscopy and LED microscopy

Date of Submission: 25-09-2017

Date of acceptance: 07-10-2017

I. Introduction:

TB is a major public health concern in India. India accounts for one fourth of the global TB burden.

In 2015, an estimated 28 lakh cases occurred and 4.8 lakh people died due to TB [1]. In addition it has also the highest number of MDR-TB (Multi Drug Resistance TB) according to Global TB Report 2016. The most critical aspect of control of tuberculosis is case detection and sputum microscopy being the most reliable, cost effective method.

Fluorescence microscopy (FM) using auramine staining has been shown to have 10% higher sensitivity compared to routine light microscopy using Ziehl-Neelsen (Z-N) staining, without compromising specificity in detecting acid fast bacillus (AFB) in sputum smear microscopy [2]. FM is also more time efficient, with one large study reporting FM to take only 25% of the time required for Z-N examinations [3]. Fluorescence staining utilizes basically the same approach as Z-N staining, but carbol fuchsin is replaced by a fluorescent dye (auramine-O, rhodamine, auramine-rhodamine, acridine orange etc), the acid for decolourisation is milder and the counter stain, though not essential, is useful to quench background fluorescence. Both sensitivity and specificity of fluorescence microscopy are comparable to the characteristics of the Z-N technique. The most important advantage of the fluorescence technique is that slides can be examined at a lower magnification, thus allowing the examination of a much larger area per unit of time. In fluorescence microscopy, the same area that needs examination for 2 minutes with a light microscope (LM) can be examined in 10 minutes [4].

Although FM can reduce laboratory workloads [5], it has been difficult to implement it widely in Low and middle income countries across the world due to the high cost and complexity of the microscope and

mercury vapour lamp lighting system, the need for a dark room, and perceived health risks associated with ultraviolet light exposure [6]. Light emitting diode (LED) microscopy is a novel diagnostic tool developed primarily to allow resource-poor parts of the world access to the benefits of FM [7, 8, 9]. Compared to conventional mercury vapour fluorescence microscopes, LED microscopes are less expensive and have lower maintenance requirements. The diodes are very durable, do not require warm-up time, and do not contain toxic products. Importantly, they are reported to perform equally well without a darkroom. These features make them suited to use in low- and middle-income countries, and they have performed well in clinical trials in these countries [10, 11, 12, 13, 14, 15, 16, 17].

The objective of this study was to assess the diagnostic efficiency of LED microscopy compared to light microscopy in a real world setting.

II. Methods and Materials:

Calcutta Medical College is a tertiary care hospital cum teaching institute which runs a DMC under Revised National Tuberculosis Control Programme (RNTCP) to provide Directly Observed Treatment Short course (DOTS) for a large catchment area.

To compare between LED & light microscopy, we conducted a cross-sectional retrospective study. Sputum smear examination was done by light microscopy (Labomed light microscope) to diagnose Acid Fast Bacilli (AFB) in sputum samples till July, 2012. LED microscopy (Zeiss Primo Star iLED) was introduced from August, 2012. (FIG.1)

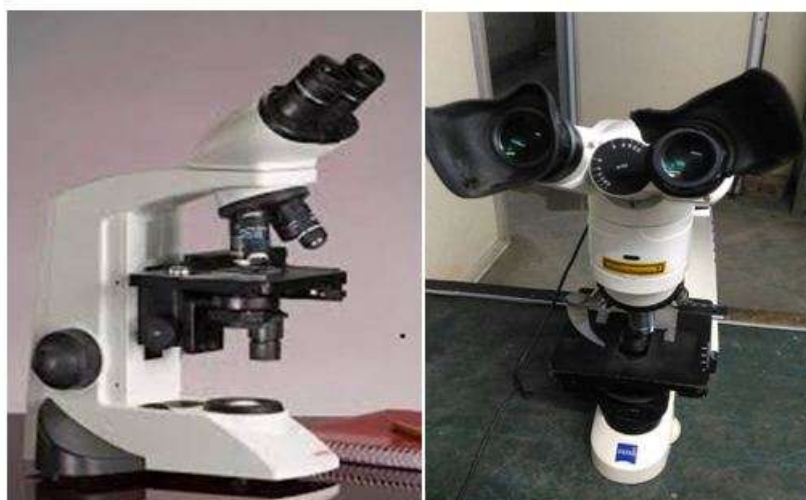

FIG 1. Labomed Light Microscope & Zeiss Primostar Fluorescent Microscope

To test the perceived efficiency of LED compared to light microscopy in a real world scenario, we collected month-wise data retrospectively from TB register from January, 2009 to December, 2016. A total of 10252 new TB suspect cases were examined by Light microscopy from January 2009 to July 2012 and 15035 new TB suspect cases were examined by LED microscopy from August 2012 to December 2016. (FIG.2)

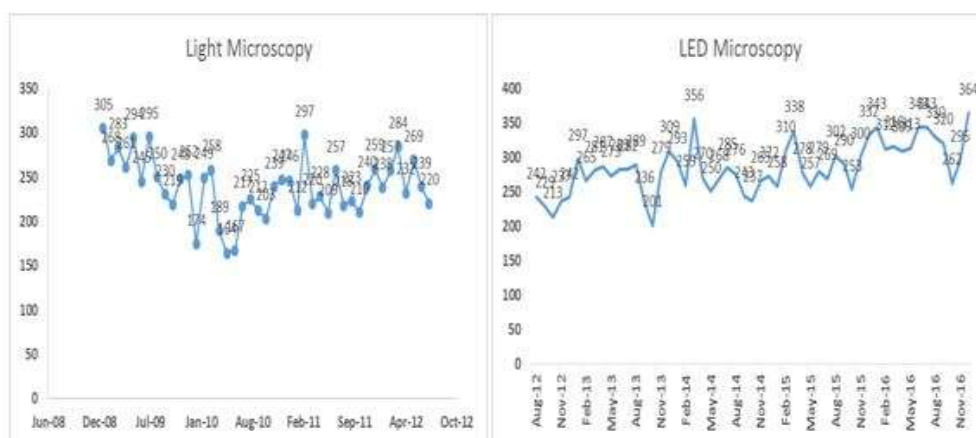


FIG 2. Month wise distributions of sputum smear microscopy of new TB suspect cases

Total 1201 sputum positive cases were found among 10252 new TB suspect cases through light microscopy during the data collection period of 43 months till July 2012. Within that timeframe 201 new TB suspect cases underwent repeat sputum examination with 26 of them found to be positive and 588 follow up TB patients examined of which 106 turned out to be sputum positive. Total 24420 sputum smear slides were examined and 2878 slides were found to be positive. A total of 1504 sputum positive cases were confirmed by LED microscopy among 15035 new TB suspect cases during 53 months of data collection period. 909 repeat sputum examination was conducted of which 58 found to be positive. Total 698 follow up patients with 221 positive reports were detected by LED microscopy. 32906 slides with 3380 positive slides were examined during these 53 months period (FIG.3).

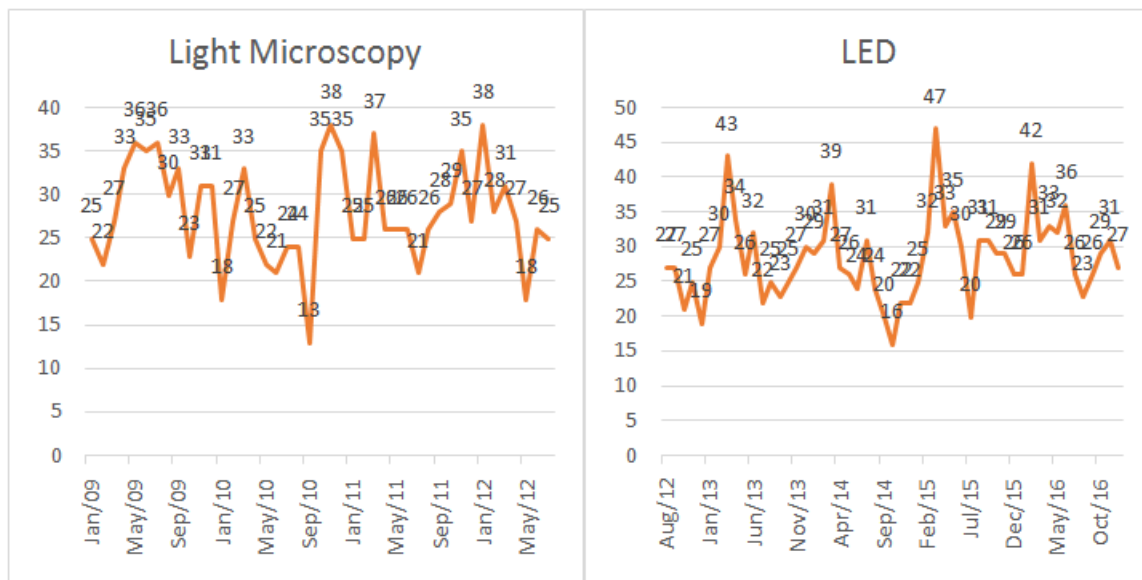


FIG 3. Month wise distribution of sputum positive cases among new TB suspect patients

Month wise distribution of total slides examined by Light and LED microscopy were 24420 and 32906 respectively (FIG 4).

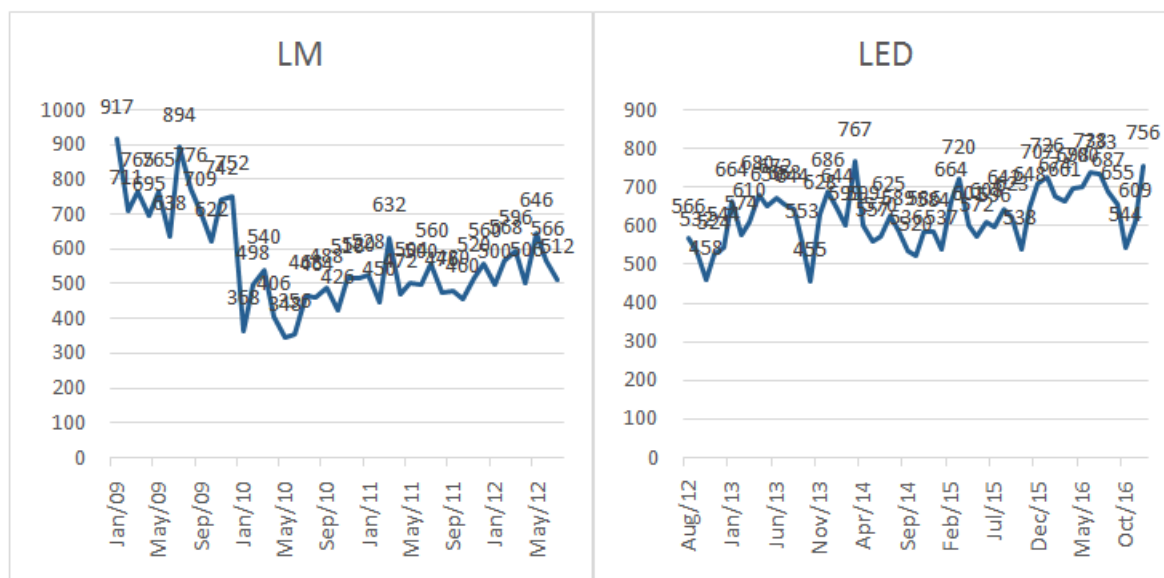


FIG 4. Month wise distribution of total slides examined by Light and LED microscopy

Retrospectively collected data for the study from Januray 2009 to December 2016 is summarised in the Data cohort table (FIG 5).

Procedure	Total TB suspects examined	Total TB suspects found sputum positive	TB suspects underwent repeat sputum examination	TB suspects found sputum positive on repeat examination	Follow-up patients examined	Follow-up Patients found sputum positive	Total slides examined	Total positive slides	Total negative slides
LM	10252	1201	201	26	588	106	24420	2878	21492
LED-FM	15035	1504	909	58	698	221	32906	3380	29526

FIG 5. Data cohort – retrospectively collected

No financial assistance has been taken from any person or institution for this study. As because it is a retrospective, observational study, no conflict of interest exist here.

III. Results:

Average monthly new TB suspect cases examined by light microscopy are 238.42 ± 33.4 (Mean \pm SD) every month and that of LED microscopy are 283.7 ± 36.58 (Mean \pm SD). The difference is statistically very significant at 95% CI (-59.6222 to -30.9378), t-value is -5.13 and p-value is $<.00001$; suggesting that number of new cases examined by LED has gone up significantly. Among the new TB suspect cases, 201 patients of LM group and 909 patients of LED group undergone repeat sputum examination, of which 26 (12.94%) and 58 (6.38%) found to be sputum smear positive respectively. The lesser yield in LED group found to be statistically significant at 95% CI (1.88 to 12.19), p-value of 0.0015 (significant at $p < 0.05$) and z-score of 3.18; which indicate that LED microscopy is probably more accurate than Light microscopy in detecting AFB through sputum smear examination. Monthly average positive yield (sputum smear positive patients) in LM and LED groups are respectively 27.93 ± 5.84 and 28.38 ± 5.99 (Mean \pm SD). There was no statistical difference between both the groups in respect to slide positivity rate (t-value is -0.37, p-value is 0.36 at 95% CI). Average monthly total slides examined in LM and LED groups are 567.91 ± 136.4 and 620.9 ± 72.58 (Mean \pm SD). The increase in mean is also statistically found to be significant at 95% CI (-96.1688 to -9.8112), p-value is 0.0167; which is significant at $p < 0.05$. Slide positivity rate was similar in both the groups with no statistically significant difference as in the case of new TB suspect cases. (FIG.6)

Procedure	Average monthly TB suspects examined for sputum smear (Mean \pm SD)	Statistical analysis	Average monthly TB suspects found positive (Mean \pm SD)	Statistical analysis	Average monthly Total sputum smear slides examined (Mean \pm SD)	Statistical analysis
LM	238.42 ± 33.4	$p <.00001$ 95% CI	27.93 ± 5.84	$p=.7121$ 95% CI	567.91 ± 136.4	$p = .0167$ 95% CI
LED-FM	15035	Significant	1504	Not significant	32906	Significant

Fig 6. Statistical results: LED-FM and LM

IV. Discussion:

According to current TB India report [1], incidence of TB is 217 per lakh per year and mortality is 36 per lakh per year which is considerably significant keeping in mind the length and breadth of RNTCP across the

country. High burden of case load, very high number of MDR-TB and high population density makes it imperative to control spread of TB as early as possible. Sputum smear microscopy is the most decentralised, reliable and cost effective tool to detect TB cases and treat them early. So any improvement in sputum smear microscopy will greatly enhance the fight against TB not only in India but worldwide in this era of globalisation and constant travel. In this respect, LED microscopy has shown significant benefit over light microscopy to detect and find pulmonary TB cases.

Our study showed that, with LED microscope, number of new case detection as well as total number of slides examined for AFB has increased significantly which supports previous studies that demonstrated the superior diagnostic performance of fluorescence microscopy compared with conventional light microscopy [18-26]. Also in case of light Microscopy, lower mean with higher SD suggest a probable higher diagnostic accuracy of LED. This inference is supported by the result shown in our study where there is higher number of sputum positive patients in the Light Microscopy group, who has undergone repeat sputum examination. This corroborates with previous studies which reported increased sensitivity and similar specificity of LED-FM compared with Z-N smear microscopy [25, 26]. Though few other studies have reported no significant difference in diagnostic accuracy between LED-FM and light Microscopy but these studies were conducted in high-resource, low burden countries.

This study was done retrospectively with the aim to determine the diagnostic efficiency of LED microscopy and light Microscopy in a real life practical setting. Analysis done on data collected during routine clinic operation and large cohort of data suggest our study results reflect probably a true difference in diagnostic efficiency between LED-FM and light Microscopy which can be reproducible and comparable in future clinical trials.

Our study was limited by the fact that it was not a prospective study in a controlled environment thereby no option of minimising human error while comparing between the procedures. Again due to high case load, sputum culture for *Mycobacterium tuberculosis*, which is the gold standard reference for determining sensitivity & specificity of sputum smear microscopy for AFB could not be done.

V. Conclusion:

In conclusion, our study adds to the body of evidence that demonstrates that LED fluorescence microscopy provides a better alternative to conventional Light microscopy. Its low cost, sturdiness, energy efficiency, and perceived efficacy in the absence of a darkened environment are highly favorable attributes. Operational advantages makes it a key component in controlling TB in our country by increasing case detection, decreasing case load and minimising human error in years to come.

Acknowledgement:

This is an observational retrospective study, where data collected from TB register of DMC of Medical College, Kolkata. We are really grateful to Mr. Tarun Chowdhuri, laboratory technician (LT) and Mr. Arun Adhikary, tuberculosis health visitor (THV) for their maximum co-operation in data collection. We show our utmost gratitude to the faculty members of Department of Pulmonary Medicine, medical College, Kolkata for their guidance in formulating this study.

Reference:

- [1]. TB India 2017, chapter 2; Central TB Division, DGHS
- [2]. Ellis E, Dawson K, Gallant V, Phipps M, Scholten D (2010) Tuberculosis in Canada 2009 - Pre-release. Ottawa, ON: Public Health Agency of Canada.,LED Microscopy in Low TB Incidence Settings PLoS ONE
- [3]. Small PM, Pai M (2010) Tuberculosis diagnosis--time for a game change. N Engl J Med 363: 1070-1071.
- [4]. Manual for Sputum Smear Fluorescence Microscopy; Central TB Division
- [5]. Ramsay A, Cuevas LE, Mundy CJ, Nathanson CM, Chirambo P, et al. (2009) New policies, new technologies: modelling the potential for improved smear microscopy services in Malawi. PLoS ONE 4: e7760. doi:10.1371/journal.pone.0007760.
- [6]. Hanscheid T (2008) The future looks bright: low-cost fluorescent microscopes for detection of *Mycobacterium tuberculosis* and *Coccidia*. Trans R Soc Trop Med Hyg 102: 520-521.
- [7]. Hanscheid T (2008) The future looks bright: low-cost fluorescent microscopes for detection of *Mycobacterium tuberculosis* and *Coccidia*. Trans R Soc Trop Med Hyg 102: 520-521.
- [8]. Minion J, Sohn H, Pai M (2009) Light-emitting diode technologies for TB diagnosis: what is on the market? Expert Rev Med Devices 6: 341-345.
- [9]. Anthony RM, Kolk AH, Kuijper S, Klatser PR (2006) Light emitting diodes for auramine O fluorescence microscopic screening of *Mycobacterium tuberculosis*. Int J Tuberc Lung Dis 10: 1060-1062.
- [10]. Shenai S, Minion J, Vadwai V, Tipnis T, Shetty S, et al. (2011) Evaluation of light emitting diode-based fluorescence microscopy for the detection of mycobacteria in a tuberculosis-endemic region. Int J Tuberc Lung Dis 15:483-488.
- [11]. Bonnet M, Gagnidze L, Githui W, Guerin PJ, Bonte L, et al. (2011) Performance of LED-Based Fluorescence Microscopy to Diagnose Tuberculosis in a Peripheral Health Centre in Nairobi. PLoS ONE 6: e17214.
- [12]. Albert H, Manabe Y, Lukyamuzi G, Ademun P, Mukkada S, et al. (2010) Performance of three LED-based fluorescence microscopy systems for detection of tuberculosis in Uganda. PLoS ONE 5: e15206.
- [13]. Lehman LG, Ngapmen Yamadji AL, Ngo Sack F, Bilong Bilong CF (2010) The CyScope(R) fluorescence microscope, a reliable tool for tuberculosis diagnosis in resource-limited settings. Am J Trop Med Hyg 83: 906-908.

- [14]. Marais BJ, Brittle W, Painczyk K, Hesselning AC, Beyers N, et al. (2008) Use of light-emitting diode fluorescence microscopy to detect acid-fast bacilli in sputum. *Clin Infect Dis* 47: 203–207.
- [15]. Trusov A, Bumgarner R, Valijev R, Chestnova R, Talevski S, et al. (2009) Comparison of Lumin LED fluorescent attachment, fluorescent microscopy and Ziehl-Neelsen for AFB diagnosis. *Int J Tuberc Lung Dis* 13: 836–841.
- [16]. Van Deun A, Chonde TM, Gumusboga M, Rienthong S (2008) Performance and acceptability of the FluoLED Easy module for tuberculosis fluorescence microscopy. *Int J Tuberc Lung Dis* 12: 1009–1014.
- [17]. Kuhn W, Armstrong D, Atteberry S, Dewbrey E, Smith D, et al. (2010) Usefulness of the paralens fluorescent microscope adaptor for the identification of mycobacteria in both field and laboratory settings. *Open Microbiol J* 4:30–33.
- [18]. Prasanthi K, Kumari AR. Efficacy of fluorochrome stain in the diagnosis of pulmonary tuberculosis co-infected with HIV. *Indian J Med Microbiol* 2005; 23:179–85.
- [19]. Kivihya-Ndugga LE, van Claaff MR, GithuiWA, et al. A comprehensive comparison of Ziehl-Neelsen and fluorescence microscopy for the diagnosis of tuberculosis in a resource poor urban setting. *Int J Tuberc Lung Dis* 2003; 7:1163–71.
- [20]. Singh NP, Parija SC. The value of fluorescence microscopy of auramine stained sputum smears for the diagnosis of pulmonary tuberculosis. *Southeast Asian J Trop Med Public Health* 1998; 29:860–3.
- [21]. Githui W, Kitui F, Juma ES, et al. A comparative study on the reliability of fluorescence microscopy and Ziehl-Neelsen method in the diagnosis of pulmonary tuberculosis. *East Afr Med J* 1993; 70:263–6.
- [22]. Ha`nscheid T, Ribeiro CM, Shapiro HM, Perlmutter NG. Fluorescence microscopy for tuberculosis diagnosis. *Lancet Infect Dis* 2007; 7:236–7.
- [23]. Steingart KR, Henry M, Ng V, et al. Fluorescence versus conventional sputum smear microscopy for tuberculosis: a systematic review. *Lancet Infect Dis* 2006; 6:570–81.
- [24]. Ben J. Marais, Wendy Brittle et al. LED Fluorescence Microscopy to Detect AFB • *CID* 2008;47 (15 July) • 205
- [25]. Mizuno K, Chikamatsu K, Aono A, Azuma Y, Yamada H, et al. (2009) [Clinical evaluation of acid-fast smear examination with light emitting diode fluorescent microscopy.] *Kekkaku* 84: 627–629.
- [26]. Turusov AA, Valiev R, Chesnokova RV (2009) [Comparative study of microscopy by the Ziehl Neelsen method, routine fluorescence microscopy, and fluorescence microscopy using a lumin attachment in the diagnosis of acidresistant mycobacteria.] *Probl Tuberk Bolezn Legk* 4: 41–45.
- [27]. Cuevas LE, Al-Sonboli N, Lawson L, Yassin MA, Arbide I, et al. (2011) LED Fluorescence Microscopy for the Diagnosis of Pulmonary Tuberculosis: A Multi-Country Cross-Sectional Evaluation. *PLoS Med* 8(7): e1001057. doi:10.1371/journal.pmed.1001057
- Minion J, Pai M, Ramsay A, Menzies D, Greenaway C (2011) Comparison of LED and Conventional Fluorescence Microscopy for Detection of Acid Fast Bacilli in a Low-Incidence Setting. *PLoS ONE* 6(7): e22495. doi:10.1371/journal.pone.0022495

*Dr. Debabrata Saha. "Comparison between Light microscopy and LED microscopy in a tertiary care teaching institute in Kolkata – a pilot study." *IOSR Journal of Dental and Medical Sciences (IOSR-JDMS)* 16.10 (2017): 01-06