

Histopathological Study of Endometrial Biopsies in Dysfunctional Uterine Bleeding

B Subhashini¹, D Praveen Kumar², E Lakshman³

1) Assistant Prof, Dept Of Pathology Kims Narketpally,

2) Resident, General Medicine, Kmc Warangal, 3) Resident, General Medicine, Kmc Warangal

Corresponding Author- D Praveen Kumar,

Abstract: Dysfunctional uterine bleeding is defined as bleeding not associated with an organic cause in women of child-bearing age. Histopathological evaluation of endometrial samples is essential in the workup of abnormal uterine bleeding. This study was carried out to evaluate patterns of endometrial histological findings in women with abnormal uterine bleeding and to correlate histopathological findings with clinical features.

Materials And Methods: One hundred and eighty five patients (185) with diagnosis of abnormal uterine bleeding who underwent endometrial sampling were studied. The slides were stained with Hematoxylin and Eosin stain.

Results: The predominant endometrial histopathological finding was proliferative endometrium seen in 99 cases (53.52%) followed by secretory endometrium in 41 cases (22.16%) and simple hyperplasia without atypia 21 cases (11.35%). Atrophic endometrium was most common finding in postmenopausal bleeding in 13 cases (7.3%) followed by endometrial carcinoma in 2 cases (1.08%).

Conclusion: Histopathological examination of endometrium should be done in women presenting with abnormal uterine bleeding especially after the age of 40 years to rule out malignancy.

Keywords: Dysfunctional uterine bleeding, endometrium, endometrial carcinoma.

Date of Submission: 10-08-2017

Date of acceptance: 24-09-2017

I. Introduction

Normal menstruation is defined as bleeding from the secretory endometrium associated with ovulatory cycle not exceeding a length of 5 days. Any bleeding not fulfilling these criteria is referred to as abnormal uterine bleeding. Dysfunctional uterine bleeding is defined as bleeding not associated with an organic cause in women of child-bearing age. The most common presentations are menorrhagia, metrorrhagia, polymenorrhoea, intermenstrual bleeding or continuous bleeding. Abnormal uterine bleeding is the commonest presenting symptom in gynaecology department^{1,2,3}. Endometrial biopsies or curettage can be done in patients of abnormal uterine bleeding after ruling out medical causes. The present study was done to evaluate the specific pathology and endometrial causes in different age groups in abnormal uterine bleeding^{11,12,13}.

II. Materials And Methods

The present study is a retrospective study done on endometrial biopsies received to pathology department from patients of abnormal uterine bleeding from July 2016 to July 2017 at KIMS Narketpally. The study material consisted of 185 endometrial biopsies. Patients with known causes of abnormal uterine bleeding like polyps, leiomyoma, endometriosis, cervical carcinoma were excluded from the study. Only cases where no organic cause of abnormal uterine bleeding was found were included in the study. The biopsies received were fixed in 10% formalin and processed and paraffin blocks were prepared. Tissue sections were cut and stained with Hematoxylin and eosin stain.

III. Results

The present study included 185 endometrial biopsies received to the department of pathology from July 2016 to July 2017 at KIMS Narketpally. The age of the patients ranged from 21-65 yrs. The majority of patients were in the age group of 31-50 yrs. The commonest finding seen in the patients was proliferative endometrium seen in 99 cases (53.52%), followed by secretory endometrium seen in 41 cases (22.16%). Atrophic endometrium was noted in 13 cases (7.03%) in postmenopausal age group. 3 cases (1.62%) of chronic endometritis were noted in the study. Endometrial hyperplasias were noted in the age group of more than 30 yrs. Simple endometrial hyperplasia without atypia was noted in 21 cases (11.35%) and simple endometrial hyperplasia with atypia was noted in 2 cases (1.08%). Complex endometrial hyperplasia without atypia was noted in 1 case (0.54%) and complex endometrial hyperplasia with atypia was noted in 3 cases (1.62%). In our

study 2 cases(1.08%) of endometrial carcinoma were noted in the age groups more than 40yrs. Age wise distribution of cases is shown in **Table-1**. Different endometrial patterns in different age groups is shown in **Table-2**.

Table 1:Relationship of DUB with different age groups.

Age(years)	No. of patients	%
21-30	19	10.27
31-40	82	44.32
41-50	69	37.30
51-60	11	05.95
>60	04	02.16
Total	185	100.00

Table 2: Different Endometrial patterns in Different Age Groups

Endometrial pattern	21-30 years	31-40 years	41-50 years	51-60 years	>60 years	Total	Percentage
Proliferative endometrium	14	43	39	03	-	99	53.52%
Secretory endometrium	05	20	15	01	-	41	22.16%
Chronic endometritis	-	02	-	01	-	03	01.62%
Atrophic endometrium	-	-	05	06	02	13	07.03%
Simple endometrial hyperplasia without atypia	-	15	06	-	-	21	11.35%
Simple endometrial hyperplasia with atypia	-	-	01	-	01	02	01.08%
Complex endometrial hyperplasia without atypia	-	-	01	-	-	01	0.54%
Complex endometrial hyperplasia with atypia	-	02	01	-	-	03	01.62%
Endometrial carcinoma	-	-	01	-	01	02	01.08%
TOTAL	19	82	69	11	04	185	100%

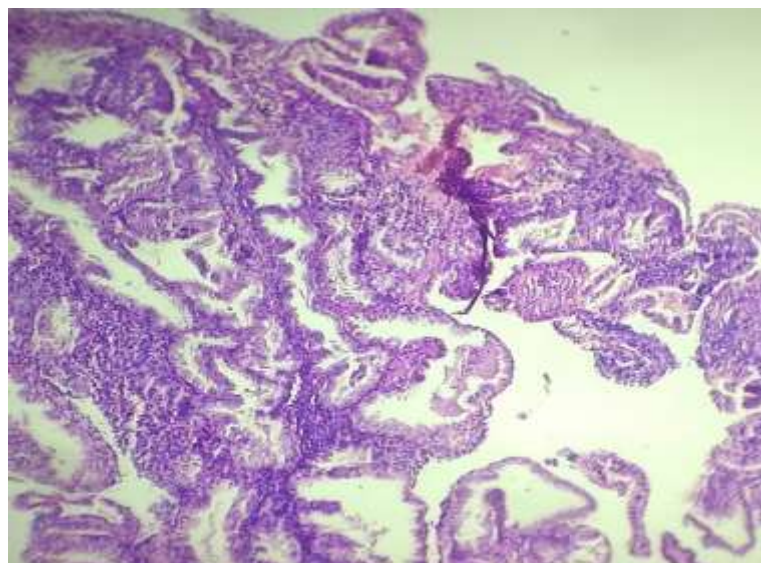


Fig-1)Simple Hyperplasiaendometrium

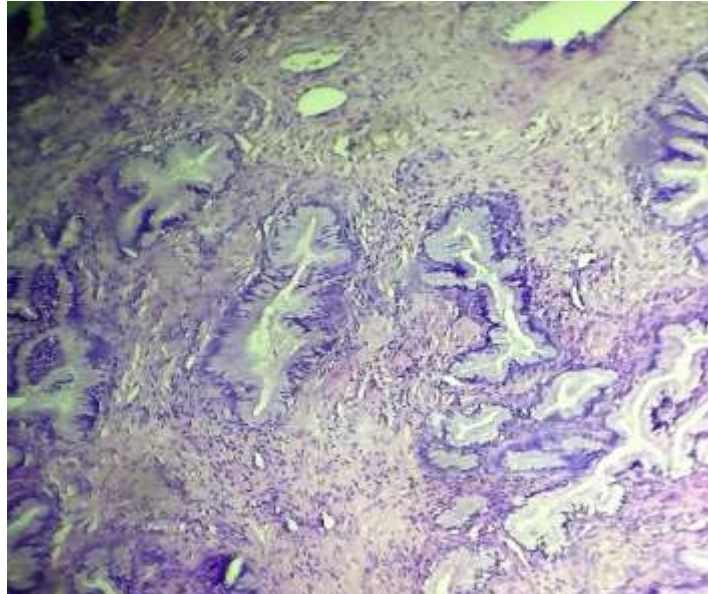


Fig-2)Secretory Endometrium

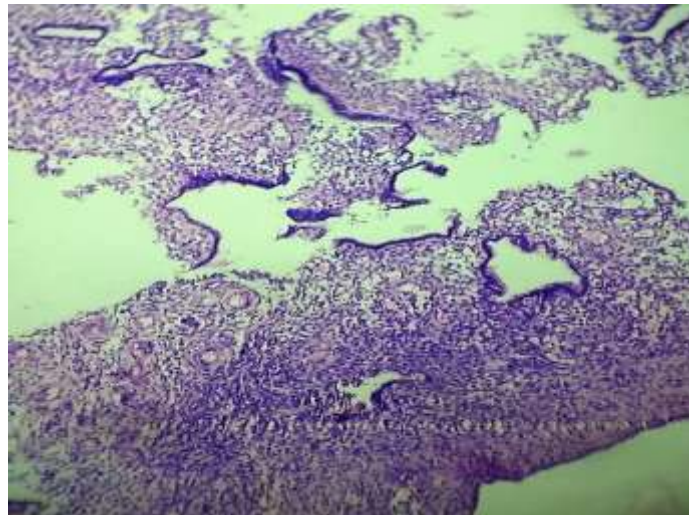


Fig-3)Chronic Endometritis

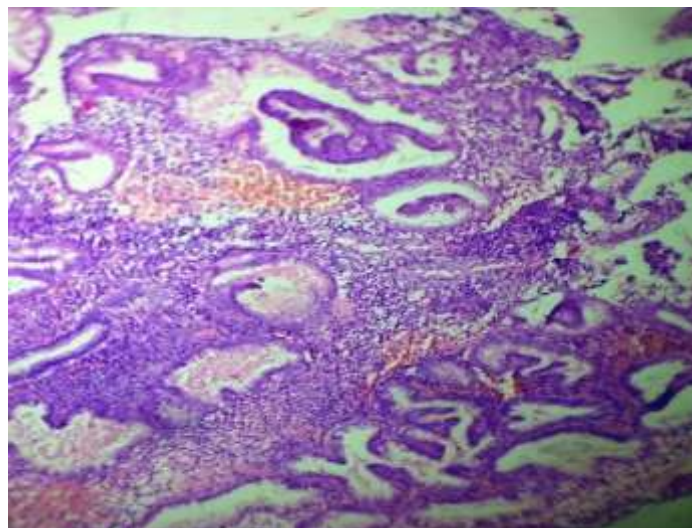


Fig-4)Complex Hyperplasia Endometrium

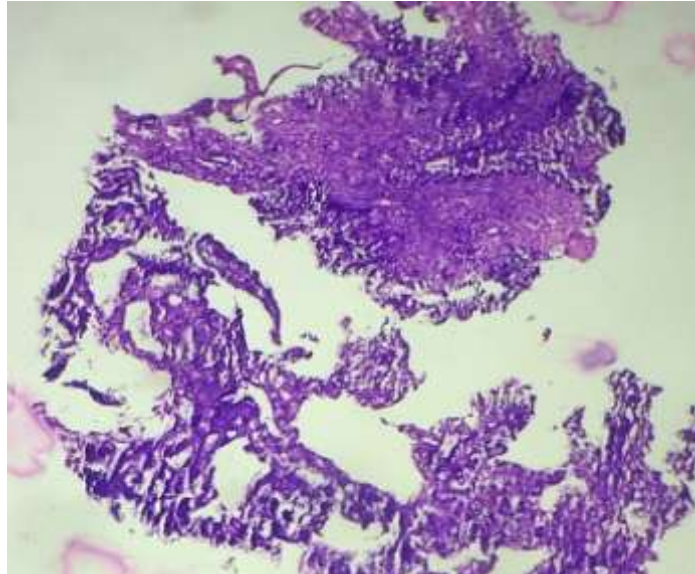


Fig-5)Adeno Carcinoma Endometrium

IV. Discussion

Interpretation of endometrial biopsies requires complete clinical history, age of patients, last menstrual period, any history of exogenous hormones or drugs. In our present study 185 specimens of endometrial biopsies were analysed retrospectively. The age group of the patients ranged between 21-65yrs of age. The maximum number of patients belonged to the age group of 31-40yrs ie 82 patients(44.32%) followed by 41-50yrs ie 69 patients(37.30%). In majority of patients there was proliferative endometrium in 53.52% of cases followed by secretory endometrium in 22.16% of cases which were similar to studies conducted by Singh A et al⁵ and Doraiswami S et al⁶. The bleeding in proliferative endometrium was due to anovulatory cycles and in secretory endometrium due to ovulatory dysfunctional uterine bleeding.

Endometrial hyperplasia was the common pathology diagnosed in our study seen in 11.35% of cases which was similar to studies conducted by Afgan S et al⁴ and Singh A et al⁵. Simple hyperplasia without atypia was noted in 11.35% cases. Simple hyperplasia is important because they are thought to be precursors of endometrial carcinomas. Complex hyperplasia was noted in 2% of cases which was similar to studies conducted by Singh A et al⁵. Follow up of cases of simple hyperplasia is important as they progress to carcinoma. Patients with complex hyperplasia may be advised hysterectomy^{12,13,14}.

Endometrial carcinoma was the least common pathology noted in 1% of cases which was similar to other studies⁸. Atrophic endometrium was seen in women over 40yrs of age and accounted for 7% of cases. The exact cause for bleeding in Atrophic endometrium is not known. Anatomical variations like thin wall veins, superficial to expanding cystic glands making the vessel vulnerable to injury as well as abnormal local hemostatic mechanisms in the uterus have been proposed to be underlying cause^{9,10,11}.

Chronic endometritis was seen in 1.62% of cases in our study which was similar to studies conducted by Singh A et al⁵. Chronic endometritis may follow pregnancy, IUCD insertion, abortion and it may be viral, chlamydial, gonococcal, TB etc^{7,8,9}.

V. Conclusion

Endometrial biopsy is safe and effective diagnostic step in evaluation of abnormal uterine bleeding. Histopathological pattern or finding of endometrium is important for the management of patients with Abnormal uterine bleeding in particular with endometrial hyperplasias and endometrial carcinomas. Young patients with normal endometrium can be treated conservatively.

References

- [1]. Yusuf NW, Nadeem R, Yusuf AW. Dysfunctional Uterine Bleeding: A Retrospective Clinicomorphological Study over Two Years. *Pak J ObstetGynaecol*1996; 9(1): 27-30.
- [2]. Brenner PF. Differential diagnosis of AUB. *Am J Obstet Gynecol.* 1996;175:766-9.
- [3]. Albers JR, Hull SK, Wesley RM. Abnormal uterine bleeding. *Am Fam Phys.* 2004;69:1915-26.
- [4]. Afgan S, Yasmeen A. Abnormal uterine bleeding a clinicopathological study of 150 cases. *Ann Pak Inst Med Sci.* 2013;9(4):201-4.
- [5]. Singh A, Bai RPV. Study of histopathological pattern of endometrium in abnormal uterine bleeding and its management. *Int J Reprod Contracept ObstetGynecol*2016;5:432-6.
- [6]. Doraiswami S, Johnson T, Rao S, Rajkumar A, Vijayaraghavan J, Panicker VK. Study of endometrial pathology in Abnormal uterine bleeding. *J ObstetGynecol India.* 2011;61:426-30.

- [7]. Dahlenbach-Hellweg G. Histopathology of endometrium. 4. New York: Springer-Verlag; 1993.
- [8]. Steven SG. Problems in the differential diagnosis of endometrial hyperplasia and carcinoma. *Mod Pathol.* 2000;13:309–327. doi: 10.1038/modpathol.3880053.
- [9]. Gredmark T, Kvint S, Havel G, et al. Histopathological findings in women with postmenopausal bleeding. *B J ObstetGynaecol.* 1998;102:133–136. doi: 10.1111/j.1471-0528.1995.tb09066
- [10]. Dangal G. A study of endometrium of patients with abnormal uterine bleeding at chitwan valley. *Kathmandu Univ Med J.* 2003;1:110–112.
- [11]. Nam-Hoon C, Chan-II P, In-Joon C. Clinicopathologic study of the endometrium. Dysfunctional uterine bleeding. *Korean J Pathol.* 1989;23:65–74.
- [12]. Livingstone M, Fraser IS. Mechanisms of abnormal uterine bleeding. *Hum Reprod Update* 2002;8(1):60-67.
- [13]. Dadhania B, Dhruva G, Agravat A et al. Histopathological study of endometrium in dysfunctional uterine bleeding. *Int J Res Med* 2013;2(1):20-24.
- [14]. Abdullah LS, Bondagji NS. Histopathological pattern of endometrial sampling performed for abnormal uterine bleeding. *Bahrain Med Bull* 2011;33(4):1-6.

*D Praveen Kumar. "Histopathological Study of Endometrial Biopsies in Dysfunctional Uterine Bleeding." *IOSR Journal of Dental and Medical Sciences (IOSR-JDMS)* 16.10 (2017): 07-11