

Reliability and accuracy of Centographic analysis in comparison with other superimposition techniques – A Cephalometric study

Dr.Lakshmpulagam¹, Dr.Ratna Parameswaran², *Dr.Nagachandran.K.S³,
Dr.Devaki Vijayalakshmi⁴, Dr.Ravanth Kumar⁵

¹(Former Post-Graduate student, Department of Orthodontics & Dentofacial Orthopedics, Meenakshi Ammal Dental College & Hospital, Chennai, Tamilnadu, India)

²Professor, Department of Orthodontics & Dentofacial Orthopedics, Meenakshi Ammal Dental College & Hospital, Chennai, Tamilnadu, India)

³Associate Professor, Department of Orthodontics & Dentofacial Orthopedics, Meenakshi Ammal Dental College & Hospital, Chennai, Tamilnadu, India)

⁴Professor & Head, Department of Orthodontics & Dentofacial Orthopedics, Meenakshi Ammal Dental College & Hospital, Chennai, Tamilnadu, India)

⁵(Assistant Professor, Department of Orthodontics & Dentofacial Orthopedics, Meenakshi Ammal Dental College & Hospital Chennai, Tamilnadu, India)

Corresponding Author: Dr.Nagachandran.K.S

Abstract: The main objective of the study is to assess and compare the three superimposition methods (Ricketts, Pancherz and Centographic analysis) and to evaluate the validity of the most reliable and reproducible technique and statistically compare the centographic analysis with the other two methods to ascertain its relative accuracy. Pre and post treatment lateral cephalograms of thirty non-growing patients with class I malocclusion and first premolar extraction who had been treated successfully with the pre adjusted edgewise appliance were obtained. Pre and post treatment hard and soft tissue measurements were assessed by superimposing the lateral cephalograms on a grid by using Ricketts, Pancherz and Centographic analysis. The results showed that all the three superimposition methods (Ricketts, Pancherz and Centographic analysis) compared were reliable. Moreover, no significant difference between the three methods was found in the investigation in all the parameters except for hard tissue pogonion which showed a mild significance which can be explained by the principles of centroid orientation. The study concludes that Centographic analysis is as reliable as the other superimposition methods like the Ricketts and Pancherz. Centroid remains unchanged during growth or treatment and hence Centographic analysis is consistently reproducible and simply adopted in daily clinical practice.

Keywords: Centographic analysis, Cephalometric analysis, Superimposition

Date of Submission: 22-09-2017

Date of acceptance: 10-10-2017

I. Introduction

Cephalometric superimposition is performed on lateral cephalograms of the same patient taken at different time period to comprehend the changes in the dentoalveolar and basal relationships due to growth as well as orthodontic or surgical treatment.^[1,2] However, if such superimpositions are to be significant, technically accurate and stable reference areas for registration should be used.

Centographic analysis was created to evaluate the facial form graphically without the need for potentially invalid numerical standards of reference.^[3] The centographic analysis is unique for each patient and the location of the centroids do not change during growth or treatment. Ricketts and Pancherz analysis are the commonly employed superimposition methods as they were formulated for the assessment of changes in individual patient rather than group of patients.^[1,4] Studies have been done to compare the reliability and validity of these existing methods.^[2,5-8]

The purpose of the study was to evaluate the pre and post treatment changes in patients with Class I malocclusion by using Ricketts, Pancherz and Centographic analysis.

II. Materials and Methods

This retrospective study was conducted on the patients who were treated at our Orthodontic center. Pre and post treatment lateral cephalograms of 30 patients who underwent orthodontic treatment, within the age group of 18 to 25 years, satisfying the inclusion criteria were selected.

Criteria for selection of patients:

- 1) Absence of relevant medical history
- 2) No previous orthodontic treatment
- 3) Patients indicated for maxillary and mandibular first premolar extraction
- 4) Class I molar relationship
- 5) All patients treated with Preadjusted Edgewise Appliance MBT prescription.

As a routine procedure the lateral cephalograms of patients are standardized with a set of norms to reduce magnification errors. The pre treatment and post treatment lateral cephalograms of all patients were taken using cephalostat machine (Planmeca Promax, Finland). The film distance to the X-ray tube was fixed at 5 feet and was taken in natural head position (NHP).^[3,9] Films were exposed at 60-72KV, 1-16 mA and a filter of 2.5mm aluminium equivalent was used. The pre and post treatment radiographs were traced digitally using FACAD cephalometric software (Ilexis, Sweden, Version 3.8.0.0). The centrographic analysis was written as a customized analysis to the software whereas the Ricketts and Pancherz were selected from the standard menu of the analysis available in the software.

The following landmarks were used and the measurements were done and tabulated.

2.1 Hard tissue landmarks:

- 1) Anterior Nasal Spine (ANS): The anterior tip of the sharp bony process of the maxilla at the lower margin of the anterior nasal opening.
- 2) Point A (Pt A): The most posterior midline point in the concavity between the ANS and the prosthion (the most inferior point on the alveolar bone overlying the maxillary incisors).
- 3) Pogonion (Pog): The most anterior midpoint of the mandible.
- 4) U1: The tip of the upper central incisor.
- 5) U6: The mesio-buccal cusp tip of the upper first molar.
- 6) L1: The tip of the lower central incisor.
- 7) L6: The mesio-buccal cusp tip of the lower first molar.

2.2 Soft tissue landmarks:

- 1) Labrale superior (Ls): The most anterior point of the upper lip.
- 2) Labrale inferior (Li): The most anterior point of the lower lip.
- 3) Pronasale (Pn): The most protruded point of the nasal tip.
- 4) Pogonion' (Pog'): The most protruding point of the soft tissue chin contour.

2.3 Interpretation of hard and soft tissue changes:

Changes in ANS and Point A indicated the maxillary skeletal changes and changes in Pogonion indicated the mandibular skeletal changes. Changes in U1, U6 would indicate the maxillary dental changes and L1, L6 would indicate the mandibular dental changes. Changes in Labrale superior and Labrale inferior indicated the change in soft tissue profile or facial convexity. Pronasale indicated the nose tip changes and pogonion' indicated the soft tissue changes in the mandible.

Superimposition methods:

2.3.1 Rickett's method:

Ricketts method comprises four steps to evaluate orthodontic treatment changes.^[1] Figure 1, depicts the maxillary, mandibular skeletal changes and the lateral cephalograms are superimposed on Ba-N at CC and N respectively. The perpendicular distance from the CC-GN plane and N-A plane are measured in the pre- and post-operative cephalograms and their difference is taken. The maxillary and mandibular dental changes are observed by the superimpositions made on PP and the corpus axis at Pm, respectively. The parallel distances along the PP plane and corpus axis are measured in pre- and post- operative cephalograms and their difference is taken. The soft tissue changes were superimposed along the esthetic plane at the crossing of the occlusal plane. The perpendicular distance from the esthetic plane was measured and the difference from pre and post-operative cephalograms was taken. All the measurements were done using the digital cephalometric software.

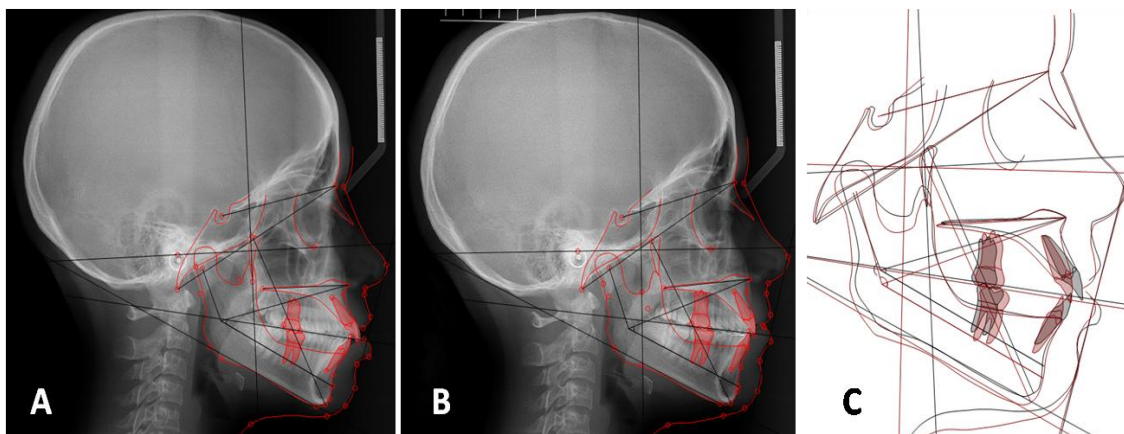


Fig 1: Ricketts Superimposition technique (A) Pre-treatment tracing, (B) Post-treatment tracing and (C) Superimposition tracing.

2.3.2 Pancherz Method:

Pancherz's method could be used to quantitatively evaluate sagittal skeletal and dental changes.^[4] A reference grid was established by the occlusal plane (OP) and its perpendicular plane (OLp) through sella point on the initial cephalogram. Cephalograms were superimposed on SN at S which is shown in Figure 2. Maxillary and mandibular skeletal changes were measured from the movement of the representative landmarks along the initial OP plane to OLp. Maxillary and mandibular dental changes were obtained from the movement of the dental landmarks along OP plane to OLp and subtracting the movement from their related skeletal bases.

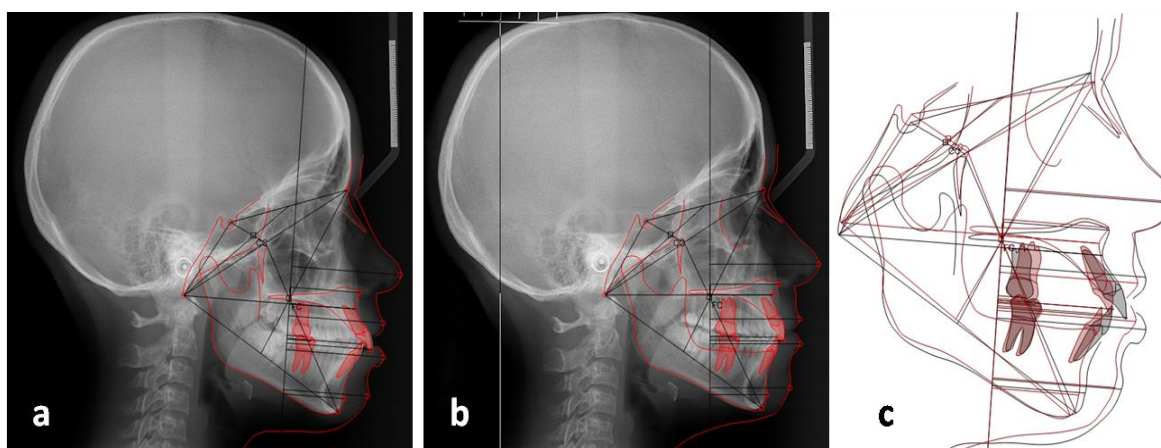


Fig 2: Pancherz Superimposition technique (1) Pre-treatment tracing, (2) Post-treatment tracing and (3) Superimposition tracing.

2.3.3 Centrographic analysis:

Centrographic analysis established the location of centroids within four anatomically determined triangular areas. Cranial Centroid (CC): triangle (Ba-S-Na), Upper Centroid (UC): triangle (Ba-Na-A), Lower Centroid (LC): triangle (Ba-A-Gn), Facial Centroid: triangle (Ba-Na-Gn). Only four lines were required to be drawn on the x-ray tracing (S-Na, Na-Ba, Ba-A, Ba-Gn).^[3] The centroid plane was constructed as a perpendicular to Ba-N through the facial centroid (FC). Superimposition was made on centroid plane at FC which is depicted in Figure 3.

Maxillary, mandibular hard and soft tissue changes were measured from the movement of the representative landmarks along the Ba-A plane to centroid plane. Even though it was a non-numerical analysis all the findings were converted to numerical values for ease of comparison with the other two methods and the evaluation was possible with the software. The linear distance between two points was measured using the software.

On the pre-treatment and post treatment tracings, all the landmarks and the structures for all the three methods were marked. The post treatment tracings were then superimposed on the pre-treatment tracings according to the three different methods using the software. The horizontal difference between the pre and post treatment tracings was measured and the difference was evaluated using the software.

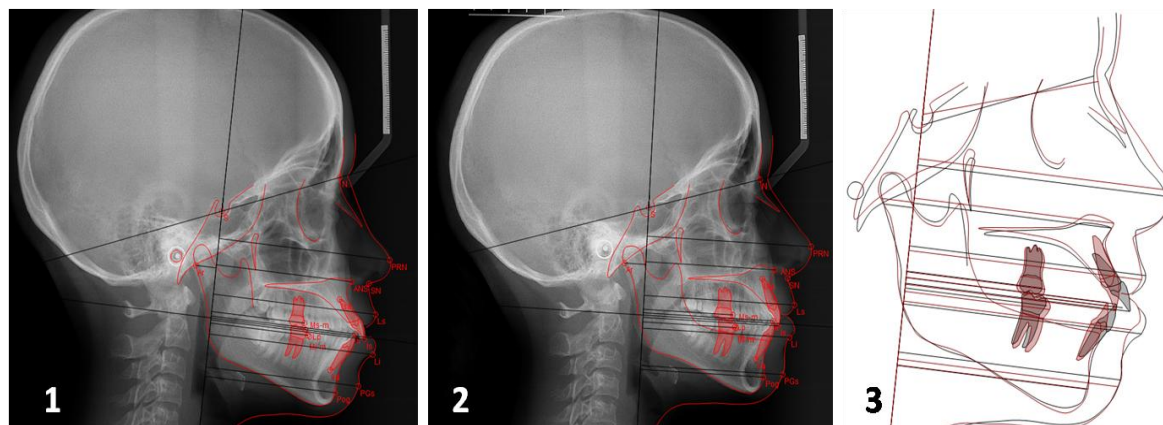


Fig 3: Centographic Superimposition technique (a) Pre-treatment tracing, (b) Post-treatment tracing and (c) Superimposition tracing

2.4 Statistical analysis:

All the measurements were noted and tabulated. Statistical analyses were performed with the one-way analysis ANOVA and Kruskal-Wallis Test.

III. Results

In the present study, $P < 0.05$ was considered as the level of significance. The obtained mean values, standard deviations and level of significance for the three methods were tabulated and shown in Table 1.

The results showed that there was no statistically significant difference found between hard and soft tissue parameters in the Ricketts, Pancherz and Centographic superimposition methods except for skeletal pogonion which showed a very mild significant difference ($p = 0.034$).

Table 1: Mean Values of the Parameters assessed for the Superimposition analyses

Parameters		Ricketts Analysis		Pancherz Analysis		Centrographic Analysis		Significance
		Mean	SD	Mean	SD	Mean	SD	
Hard Tissue	ANS	1.517	0.9048	1.250	0.9804	1.417	1.0914	0.553
	Point A	1.883	1.1117	1.550	1.1169	1.317	1.0462	0.119
	Pogonion	1.967	1.5588	2.100	1.8071	1.200	1.2429	0.034*
	U1	4.900	2.2758	5.050	1.8352	5.433	2.2001	0.603
	U6	3.167	1.6730	3.117	1.9900	2.567	1.3799	0.319
	L1	4.067	1.7847	3.633	1.9737	3.767	1.9597	0.738
	L6	2.467	1.3386	3.233	2.0415	2.667	1.3412	0.340
Soft Tissue	Ls	2.450	1.2272	2.567	1.6955	2.767	1.5354	0.738
	Li	2.367	1.4559	2.633	2.0040	2.483	1.6054	0.968
	Pn	1.317	1.5674	1.167	1.0450	0.950	0.8025	0.810
	Pog [*]	1.983	1.6993	2.183	1.9364	1.450	1.4041	0.296

* $p < 0.05$ significant

IV. Discussion

Even though several cephalometric studies have been reported, only few research is evident in the field of cephalometric superimposition.^[10,11] Perhaps the reason for this is due to the difficulty involved in objectively interpreting and comparing various methods of orientation.^[12] Since current methods were untested for reliability, it seemed that any results acquired which were dependent upon these methods are of questionable significance.^[13] Three different superimposition methods have been considered for the present study, which included Ricketts analysis, Pancherz and Centographic analysis.

According to Ricketts, if the superimposition area was the Ba-Na line with the registration at CC point, it was possible to evaluate changes in the facial axis, in the direction of chin growth and in the upper molar position. Melsen on the other hand, had observed that the position of Basion was influenced by the remodelling processes on the surface of the clivus and the anterior border of the foramen magnum, as well as the displacement of the occipital bone.^[10] Because nasion, sella and basion moved during growth, the methods of overall superimposition on S-Naor Ba-Na lines have a low degree of validity, although they have high degree of reproducibility.^[13,14]

Pancherz's method could be used to quantitatively evaluate sagittal skeletal and dental changes.^[4,15] The main disadvantage of these methods of superimposition was that they incorporate areas of the cranial base that continue to change. Sella turcica underwent eccentric remodelling during adolescence and beyond, and

this resulted in significant changes in the configuration of fossa.^[9] As a result, the position of the midpoint of the sella turcica moved either downward and backward or straight downward. Similarly, Bolton point was frequently obscured by the mastoid process in the teenage years.

Centrographic analysis was unique to each patient; it supplied independent identification of anteroposterior positions of the maxilla and the mandible, vertical facial proportion differences, and a stable reference plane, which could be used for longitudinal cephalometric superimposition.^[11] An important characteristic of centroids was that they change minimally in position as a triangle increased in size and shape. The triangles thus created were simpler to construct than actual anatomic representations. With the help of computer-aided software, an objective and accurate determination of each anatomic variant could be easily accomplished. The establishment of the reference plane by centroid development was a useful tool in determining the relative positions of variable landmarks. Growth changes could also be identified by this stable axis.^[7,16] The reference point CC could be assumed to be stable, and changes in the slope of the reference axis would reflect facial changes resulting from maxillary and mandibular changes.

The results of the present study showed no statistically significant differences between the three groups and also within the three groups. When multiple comparisons were made between groups they also showed non-significant results. Moreover Kruskal Wallis tests also showed non-significant values except for hard tissue pogonion which showed a mild significant value.

In Centographic analysis, hard tissue Pogonion had less mean and standard deviation when compared to other superimposition methods. This can be explained by the principles of centroid variation.^[3] A centroid represented the centre of mass or gravity of a two-dimensional area or a three-dimensional volume. It was a precise point representing the mean of innumerable small variations. An important characteristic of centroids was that they change minimally in position as a triangle increased in size and shape. Points located on the periphery of an enlarged area, such as traditionally used cephalometric landmarks, alter their position more than their representative centroids. All the other parameters were measured either horizontally or vertically whereas hard tissue pogonion was a measure of horizontal and vertical displacement. So the difference between pre and post treatment values was quantitatively minimal when compared to other parameters and other analysis which were superimposed on anatomic landmarks. Hence, there was least statistical difference between pogonion changes in centographic analysis compared to the other two analyses. All the other hard tissue parameters like ANS, U1, U6, L1, and L6 showed no significance statistically. This is in concordance with the study conducted by You and Hagg et al.^[8]

When soft tissue parameters are taken into account, pog' also showed similar results as the hard tissue pogonion but they were non-significant statistically. In Centographic analysis the values were less which can be explained by the same principles of centroid orientation which is dependent on the movement of teeth and point B as these values changed, pog' also changed accordingly. So the values were non-significant although they followed the same trend like hard tissue pogonion which does not depend on these factors. All the other soft tissue parameters like labrale superior, labrale inferior and pronasale showed no significance statistically between the Ricketts, Pancherz and Centographic analysis. The results of the present study showed that all the three superimposition methods compared were reliable and exhibited considerable accuracy. Moreover, no significant difference between the three methods was found in the investigation. Although the dental and skeletal mean changes expressed numerically were small, especially compared with the standard deviations, the results based on one-way ANOVA test, showed that there was no statistically significant systemic error for any of the individual methods. So far no study has been reported comparing Centographic analysis with the conventional superimposition methods and the present study is a modest attempt in analyzing the lacunae which will provide a reliable insight in the techniques of superimposition.

V. Limitations of the study

All the landmarks used in this study for the evaluation of the dental and skeletal changes during orthodontic treatment were the same for all the three superimposition methods. Consequently, the errors related to the identification of those landmarks were the same for all the three methods, thus the outcome of the assessment of the three superimposition methods was solely based on the errors related to the various reference structures and planes used.

Recent trend in using three dimensional data has opened new venues in diagnosis and treatment planning. The applicability of centerographic analysis in 3D cephalometry needs to be implied and future studies should be performed to assess its reliability.

VI. Conclusions

The null hypothesis stays accepted that Centographic analysis is as accurate as the other two conventional superimposition methods such as Ricketts and Pancherz analysis. However the hard tissue pogonion showed a mild significant difference as change in this landmark was a measure of horizontal and vertical displacement and the centroids displayed minimal change between pre and post treatment assessments in Centographic analysis.

References

- [1]. Ricketts RM. A four step method to distinguish orthodontic changes from natural growth. J Clin Orthod. 1975; 4:208-28.
- [2]. Yan Gu, James A. McNamara Jr. Cephalometric Superimpositions. A Comparison of Anatomical and Metallic Implant Methods. Angle Orthod. 2008; 78: 967-976.
- [3]. Leonard S. Fishman. Individualized evaluation of facial form. Am J Orthod Dentofac Orthop 1997; 111: 510-7
- [4]. Pancherz H. The mechanism of Class II correction in Herbst appliance treatment. A cephalometric investigation. Am J Orthod 1982; 82:104-13.
- [5]. Allison H. Cook. The variability and reliability of two maxillary and mandibular superimposition techniques. Part II. Am J Orthod Dento fac Orthop 1994;106:463-71
- [6]. Z. MirzenArat, MelihaRubenduz, Ayca Arman Akgul. The Displacement of Craniofacial Reference Landmarks During Puberty: A Comparison of Three Superimposition Methods. Angle Orthod. 2003; 73: 374-380.
- [7]. Stephen D. Springate. The validity of two methods of mandibular superimposition: A comparison with tantalum implants. Am J Orthod Dento facial Orthop1998;113:263-70.
- [8]. Q.U.You and U.Hagg. A comparison of three superimposition methods. European journal of orthodontics. 1999;21: 717-725.
- [9]. Baumrind S, Miller D, Molthen R. The reliability of head film measurements.3. Tracing superimposition. American journal of orthodontics. 1976;70: 617-644.
- [10]. Melsen. The cranial base. Actaodontscand. 1974: 32(suppl 62).
- [11]. Calogero Dolce, Gainesville, Fla Randolph E. Schader, Susan P. McGorray, and Timothy T. Wheeler. Centographic analysis of 1-phase versus 2-phase treatment for Class II malocclusion. Am J Orthod Dento facial Orthop 2005;128:195-200.
- [12]. Moorrees CFA. Natural head position- a revival. Am J Orthod Dentofacial Orthop. 1994;105: 512-513.
- [13]. SumantGoel, Manu Bansal, Amit Kalra. A preliminary assessment of cephalometric orthodontic superimposition. European journal of orthodontics. 2004; 26:217-222.
- [14]. Zuleyha Mirzen Arat, Hakan Turkkahraman, Jeryl D. English, Ronald L. Gallerano, Jim C.Boley. Longitudinal growth changes of the cranial base from puberty to adulthood. A comparison of different superimposition methods. Angle Orthod. 2010; 80: 725-732.
- [15]. John Yung Chuan Wu, Urban Hagg, Hans Pancherz, Ricky Wing Kit Wong, and Colman McGrath. Sagittal and vertical occlusal cephalometric analyses of Pancherz: Norms for Chinese children. Am J Orthod Dento facial Orthop 2010;137:816-24.
- [16]. Stella S. Efstratiadis, Gwen Cohen, Joseph Ghafari. Evaluation of differential growth and orthodontic treatment outcome by regional cephalometric superpositions. The Angle Orthodontist. 1999; 69: 225-230.

*Dr.Nagachandran.K.S. "Reliability and accuracy of Centographic analysis in comparisonwith other superimposition techniques – A Cephalometric study." IOSR Journal of Dental and Medical Sciences (IOSR-JDMS) 16.10 (2017): 81-86