

## Atypical, Late Presentation of Juvenile Huntington Disease: Cognitive Impairment, Dementia and Tremors.

\*Dr. Manjiri Naik<sup>1</sup>, Dr. Vinit Sarode<sup>2</sup>, Dr. Suraj Vyawahare<sup>2</sup>,  
Dr. Sushant Yadav<sup>2</sup>, Dr. Gaurav Tamboli<sup>2</sup>, Dr. Sachin Chate<sup>2</sup>

(<sup>1</sup>Professor, <sup>2</sup>Junior Resident, Department of Medicine, MGM Medical College and Hospital, Aurangabad, India)

Corresponding Author: Dr. Manjiri Naik

### ABSTRACT

**Introduction:** Huntington's disease (HD) is a dominantly progressive, inherited neurodegenerative disorder characterized clinically by a combination of abnormal involuntary movements mainly chorea, neuropsychiatric manifestations, and dementia. It is caused by an unstable CAG repeat expansion in the gene IT15 which encodes a Huntingtin protein. The characteristics of Juvenile Huntington's Disease (JHD) differ from those of adult-onset HD, as chorea does not occur in JHD although bradykinesia, dystonia, and signs of cerebellar disorder such as rigidity are present frequently in association with convulsive episodes and psychotic manifestation.

**Case report:** A 25 years old male was admitted with major complains of tremor, depression and dementia.

**Findings:** History, clinical examination and laboratory findings suggestive of JHD, a form of HD. A diagnosis was confirmed by contrast enhanced magnetic resonance imaging of brain and Huntington Disease-DNA PCR.

**Conclusion:** Tremor is an uncommon initial presentation of Huntington disease and Juvenile Huntington's disease.

**Keywords:** CAG, Huntington Disease-DNA PCR, Juvenile Huntington's disease (JHD), Magnetic Resonance Imaging, tremors

Date of Submission: 25-09-2017

Date of acceptance: 12-10-2017

### I. Introduction

Huntington's disease (HD) is a dominantly progressive, inherited neurodegenerative disorder characterized clinically by a combination of abnormal involuntary (choreic) movements, neuropsychiatric manifestations, and dementia.<sup>1</sup> Its prevalence in various areas of the world ranges from 5 to 10 per 100,000.<sup>1</sup> Symptoms usually present with slow progression leading to dementia and death approximately 15-20 years after disease onset.<sup>2</sup> HD results from an expanded and unstable trinucleotide repeat CAG in the IT15 gene on chromosome 4 (4p16.3) that encodes a large protein called huntingtin (Htt) with more than 3000 amino acids.<sup>3</sup> Healthy individuals typically have fewer than 35 CAG repeats, and repeats of 40 or above cause HD with complete penetrance.<sup>4</sup> Tremor as an initial presenting feature of Huntington disease is rare. The onset of disease <20 years of age is classified as Juvenile HD (JHD) and those with disease onset <10 years are described as having "Childhood-onset HD."<sup>5</sup> The characteristics of JHD differ from those of adult-onset HD, as chorea does not occur in JHD although bradykinesia, dystonia, and signs of cerebellar disorder such as rigidity are present frequently in association with convulsive episodes and psychotic manifestation.<sup>6</sup>

### CASE REPORT

A 25 year-old male was admitted with history of complains of tremor, anxiety and depression. On detailed history from patient's parents, from the age of 10 years the patient began to have complain of forgetfulness and not attentive in school and studies, suggestive of cognitive impairment and dementia. Later he left his school. He did his daily routine simple activities but was not able to perform complex activities. At the age of 23 years patient began to have complains of tremors which was gradually in onset and progressive in nature. Anxiety and symptoms suggestive of depression since last 1 year. No complain of any other movement disorder and neurological complains. No other members of the family have similar above complains. The remaining history was insignificant.

On his General examination the patient was conscious, his pulse rate was 74/min. regular, blood pressure was 130/80 mmHg and respiratory rate was 17/min. On systemic examination of central nervous system

patient has intentional tremors, hyperreflexia in deep tendon reflex and planter reflex bilateral flexor. Patient has no cerebellar sign and the remaining of CNS findings and other systemic examination were normal.

**Diagnostic Workup**

On routine laboratory investigations, apart from mild anaemia there was no other significant findings. Patient’s Laboratory investigation on admission were as follows

PARAMETER	RESULT	REFERENCE RANGE
Hemoglobin	11.2 gm/dl	12-16.2 gm/dl
TLC	5550 /cmm	4000-10000 /cmm
Platelets	326000 /cmm	165000 – 415000/ cmm
Urea	18 mg/dl	7-20 mg/dl
Serum Creatinine	0.9 mg /dl	0.5 -1.2 mg/ dl
Serum Sodium	139 meq/L	135-145 meq/L
Serum Potassium	4.6 meq/L	3.5-5.5 meq/L
Free T3	6.33 pg/ml	2.77-5.77pg/ml
Free T4	1.49 ng/dl	0.78-2.19 ng/dl
TSH	1.44 uIU/ml	0.4-4.6 uIU/ml

Table 1-Laboratory Investigations

Magnetic Resonance Imaging of Brain suggestive of atrophy of bilateral caudate nuclei with mild dilatation of frontal horns of bilateral lateral ventricles and hyper intensities in bilateral caudate nuclei and putamen.

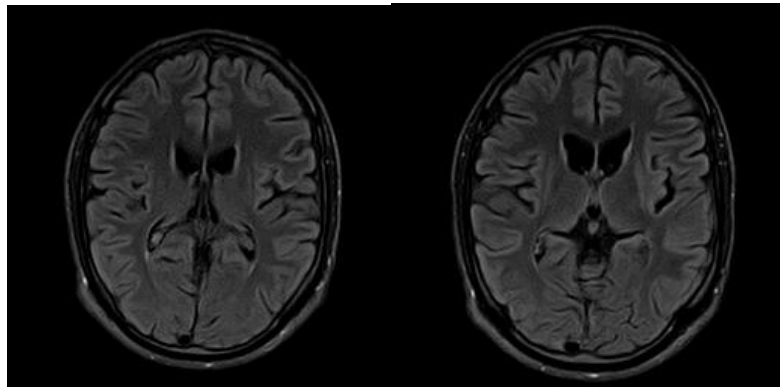


Figure 1: MRI Brain- atrophy of bilateral caudate nuclei

Huntington Disease-DNA PCR was suggestive of showed 55 expanded trinucleotide CAG repeat sequences, with clinical implication of Huntington Disease (full penetrance)

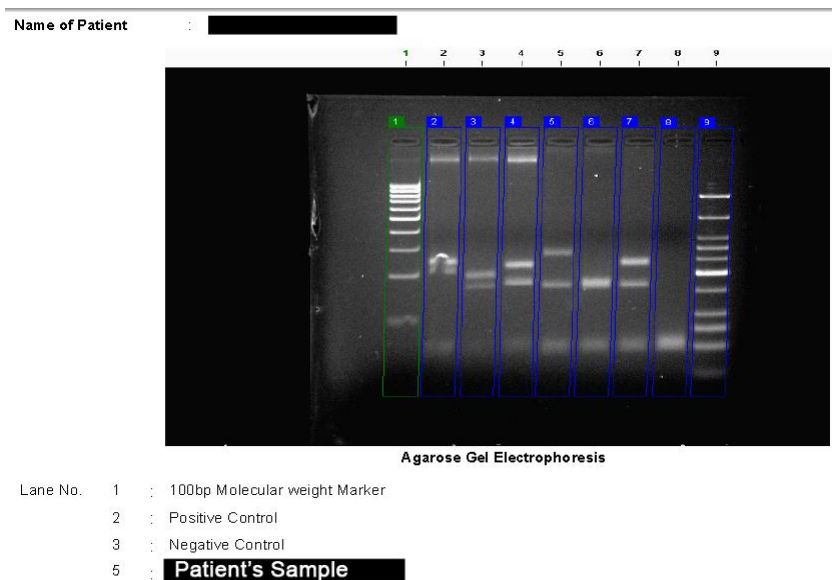


Figure 2: Huntington’s Disease-DNA PCR by Agarose Gel Electrophoresis

The diagnosis of Huntington's disease was confirmed. Patient was initially started propranolol for tremors, but later tetrabenazine was added for control of tremors. Patient's family members were counselled about the patient's disease and progress.

## II. Discussion

Huntington disease (HD), described by George Huntington in 1872. HD is a devastating neuropsychiatric disorder for which therapeutic interventions, other than providing mild symptomatic relief, have been rather fruitless to date.<sup>7,8</sup> HD has long been recognized to be due to a monohybrid autosomal gene mutation transmitted by Mendelian dominant inheritance with complete penetrance. It is caused by a loss of GABAergic neurons of the basal ganglia, especially of the caudate nucleus and putamen, where decreased glucose metabolism has been shown by positron emission tomography. The diagnosis of HD in an adult is usually made in a person who has memory or cognitive changes (dementia), and chorea (dance-like movements), often with behavioral or psychiatric problems such as depression, irritability, or mood swings, and usually with a family history of HD in a parent. Atypical presentations exist, which are more frequent in juvenile-onset HD, in which chorea is absent but bradykinesia, dystonia and signs of cerebellar alterations such as rigidity do appear, with a more frequent association with seizures and progressive myoclonic epilepsy<sup>9,10</sup> and psychotic clinical manifestations. When the condition appears in childhood, manifestations of autism, major behavior disorders, learning difficulties<sup>11</sup> and spasticity<sup>12</sup> are frequent. Tremor is defined as rhythmic oscillations of a body part produced by alternating or synchronous contractions of reciprocal muscles that may occur at rest or action (postural and/or intentional). A review of the literature yielded initial symptoms and DNA analysis in 33 JHD patients when Cui et al.<sup>13</sup> used "juvenile Huntington's disease", "juvenile Huntington's chorea", "Huntington's disease", "Huntington's chorea" and "case report", "clinical Study" for searching in PubMed, Embase, Cochrane Library, Web of Knowledge, CINAHL and ProQuest databases, did not mention tremors as a initial presenting symptom of JHD. However, study by Emilia Mabel Gatto et al.<sup>14</sup> showed tremors as presenting feature in 1 patient along with other constitutional features of JHD. As the motor and cognitive clinical manifestations worsen, patients die from complications of falls, inanition, dysphagia, or aspiration;<sup>15</sup> delirium is common.<sup>9,16</sup> Pharmacologic therapy is limited to symptomatic treatment. Choreic movements can be partially suppressed by neuroleptics. Anti-Parkinsonian agents may ameliorate hypokinesia and rigidity. Psychiatric disturbances such as depression, psychotic symptoms, and outbursts of aggression may respond to psychotropic drugs. Cognitive impairment is not amenable to treatment. Supportive care with attention to nursing, speech and swallowing, diet, ambulation, special equipment, environmental adaptations, social services, and eligibility for state and federal benefits is important for individuals with HD and their families.

## III. Conclusion

By observing our JHD case, it illustrates that early symptoms may be present long before the classical diagnostic features are present. Early diagnosis can be done by obtaining a good medical history, including the family history and the necessary complementary tests which reduces the probability of diagnostic errors. We believe that a case of JHD having tremors as involuntary movement is a rare phenomenon that warrants mention.

## Reference

- [1] Gonzalez- Alegre P, Afifi AK. Clinical characteristics of childhood- onset (Juvenile) Huntington disease: Report of 12 patients and review of the literature. *J Child Neurol* 2006;21:223- 9.
- [2] Ross CA, Margolis RL. Huntington's disease. *Clin Neurosci Res* 2001; 1:142-152.
- [3] The Huntington's Disease Collaborative Research Group. A novel gene containing a trinucleotide repeat that is expanded and unstable on Huntington's disease chromosomes. *Cell* 1993;72:971-983.
- [4] Cardoso F, Seppi K, Mair KJ, Wenning GK, Poewe W. Seminar on choreas. *Lancet Neurol.* 2006 Jul;5(7):589-602.
- [5] Quarrell OW, Nance MA, Nopoulos P, Paulsen JS, Smith JA, Squitieri F. Managing Juvenile Huntington's disease. *Neurodegener Dis Manag* 2013;3:267-76.
- [6] Reyes Molón L, Yáñez Sáez RM, López- Ibor Alcocer MI. Juvenile Huntington's disease: A case report and literature review. *Actas Esp Psiquiatr* 2010;38:285- 94.
- [7] Bonelli RM, Wenning GK, Kapfhammer HP. Huntington's disease: present treatments and future therapeutic modalities. *Int Clin Psychopharmacol* 2004;19:51-62.
- [8] Leegwater-Kim J, Cha JHJ. The paradigm of Huntington's disease: therapeutic opportunities in neurodegeneration. *NeuroRx* 2004;1:128-138.
- [9] Rosenblatt A, Leroy I. Neuropsychiatry of Huntington's disease and other basal ganglia disorders. *Psychosomatics* 2000;41:24-30.
- [10] Oliver JE. Huntington's chorea in Northamptonshire. *Br J Psychiatry* 1970;116:241-53.
- [11] De Diego-Balaguer R, Couette M, Dolbeau G, Durr A, Youssov K, Bachoud-Levi AC. Striatal degeneration impairs language learning: evidence from Huntington's disease. *Brain* 2008;131(Pt 11):2870-81.
- [12] Rasmussen A, Macias R, Yescas P, Ochoa A, Davila G, Alonso E. Huntington disease in children: genotype-phenotype correlation. *Neuropediatrics* 2000;31(4):190-4.
- [13] Cui et al. *BMC Neurology* (2017) 17:152 DOI 10.1186/s12883-017-0923-1.

- [14] Emilia Mabel Gatto et al. Juvenile Huntington disease; DOI: 10.1590/0004-282X20150192
- [15] Walker FO. Huntington's disease. *Lancet* 2007;369:218–28.
- [16] Watts R, Koller W. *Movement disorders: neurologic principles and practice*. New York: McGraw-Hill, 1997.

\*Dr.Manjiri Naik. “Atypical, Late Presentation of Juvenile Huntington Disease: Cognitive Impairment, Dementia and Tremors.” *IOSR Journal of Dental and Medical Sciences (IOSR-JDMS)* , vol. 16, no. 10, 2017, pp. 09–12.