

Risk of Facial Nerve Palsy Following Parotidectomy And Outcome of Facial Nerve Monitoring Using Nerve Mapper

¹Dr. Maragathamani Elangovan, *²Dr. P. Saravanakumar MS

¹Professor of General Surgery, Department of General Surgery, Dhanalakshmi Srinivasan medical college & Hospital, Perambalur, Tamilnadu, India

²Assistant Professor of General Surgery, Department of General Surgery, Government MohanKumaramangalam Medical College Hospital, Salem, Tamilnadu, India

Corresponding Author: *²Dr. P. Saravanakumar MS

Abstract

Introduction: Intra operative facial nerve monitoring using nerve mapper during parotid surgery has shown to decrease the incidence of post operative facial nerve palsy.

Aims and objectives:

- To assess the incidence of facial nerve palsy following parotidectomy.
- To assess the role of intraoperative facial nerve monitors (mapper) in preventing facial palsy.

Materials And Methods

Study design

Longitudinal study - Prospective.

Study period

Aug 2015 to Aug 2017

Sample size

36

Inclusion criteria: All cases of parotid swellings who underwent parotid surgery at Dhanalakshmi Srinivasan Medical College & Hospital Perambalur

Exclusion criteria

- 1) Cases <13 years of age
- 2) Cases with inflammatory and post traumatic parotid swellings.

Conclusion:

1. Intraoperative facial nerve monitoring has shown to decrease the incidence of facial nerve palsy by 22%, even though not statistically significant.
2. Usage of intraoperative facial nerve mapper during parotidectomy is helpful for easy identification of the facial nerve trunk and branches, especially for the upcoming surgeons.
3. Intraoperative facial nerve monitoring is significantly associated with decrease in the duration of surgery.

Keywords: parotid swelling, facial nerve, nerve mapper.

Date of Submission: 28 -09-2017

Date of acceptance: 12-10-2017

I. Introduction

Salivary gland tumors form 3-4% of the head and neck neoplasms. 70% of these occur in the parotid gland & of these parotid tumors, 80% are benign. Most of them arise from the superficial lobe of parotid. It presents as slow growing painless swelling either below the ear or upper part of neck. Rarely, those arising from deep lobe present as parapharyngeal mass. The most common parotid tumor is Pleomorphic adenoma followed by Warthin's tumor. The most common malignant tumor is Mucoepidermoid carcinoma. Treatment of parotid tumor is either by surgery alone or surgery followed by radiotherapy in certain cases. The major complications of parotid gland surgery reported in the literature are Facial nerve injury, salivary fistula and Frey's syndrome. Despite recent advances in operative techniques, a significant proportion of patients' undergoing parotidectomy develop facial palsy. The incidence of facial nerve paralysis is about 30-65% for transient weakness and 3-6% for permanent dysfunction. Permanent facial palsy means facial nerve palsy persisting even after 6 months. The thought that they may wake up with a paralysed face is probably a major concern for most patients who have been advised to undergo surgeries on parotid. Such paralysis may occur in 3 ways.

- 1) Although the surgeon preserves the nerve anatomically, patient may develop a functional facial paralysis after surgery which is transient.
- 2) The surgeon may deliberately sacrifice the nerve as a necessary step in removing the pathological process.

3) The surgeon may inadvertently cut or grossly interrupt the anatomical continuity of facial nerve. The intra operative use of Nerve Integrity Monitor has been advocated to reduce the incidence of facial nerve paralysis.

In this present study we used Nerve Locator–Mapper (fig.1) to monitor facial nerve during parotid surgery .It is very useful in peripheral motor nerve like facial nerve. The aim is to stimulate nerve using nerve locator-mapper by which we can observe facial muscle twitching which supplied by facial nerve.




Fig : 1 Nerve mapper

II. Method

First we have to fix the remote electrode (positive) in the shoulder on the same side of parotid lesion. The set current is delivered between the tip of the nerve mapper (negative) and the remote electrode. Lesser the current required to stimulate the muscle more close is the nerve to the locator tip. All the branches of the facial nerve are located separately in similar fashion and preserved.

Aims And Objectives

- To assess the incidence of facial nerve palsy following parotidectomy.
- To assess the role of intraoperative facial nerve monitor (**NERVE MAPPER**) in preventing facial palsy.

Operative Steps

- General endotracheal anaesthesia Without The Use Of Muscle Relaxant is preferred so that facial nerve function can be monitored during the surgery.
- The patient is placed supine, with the head at the top of the table and the ipsilateral shoulder as close to the edge of the operating table as possible.

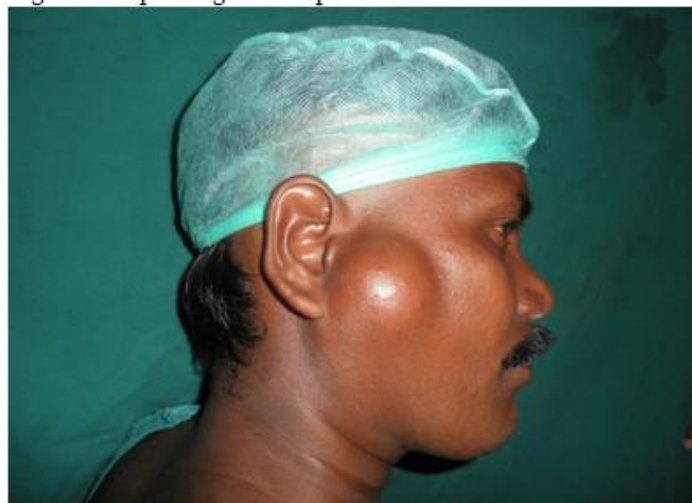

Fig.2 : Right sided parotid swelling FNAC showed pleomorphic

Adenoma

- A shoulder roll is used to extend the neck, and the head is supported with a foam rubber doughnut-shaped ring.
- The ear, neck, parotid gland, corner of mouth, and corner of eye are exposed so that facial nerve function can be monitored.
- A modified Blair incision (standard parotidectomy incision) is outlined using a sterile marking pen.
- The incision is made in a relaxed preauricular skin crease, curves around the lobule toward the mastoid tip and then anteriorly along a natural skin crease, curving approximately 2 fingerbreadths below the angle of mandible .
- The only visible portion of the skin incision after healing occurs is along the upper neck incision. If a neck dissection or mastoidectomy is required for malignant tumors, the incision must be modified accordingly.
- The anterior skin flap is raised sharply in a subplatysmal plane(Fig 3a), above the parotid fascia, to the anterior border of the gland. The subcutaneous fat is elevated with the skin flap.
- The posterior skin flap is then elevated, exposing the anterior border of the SCM muscle and the mastoid process.
- The lobule is retracted posteriorly using a 2-0 silk suture to visualize the mastoid tip and cartilaginous ear canal.

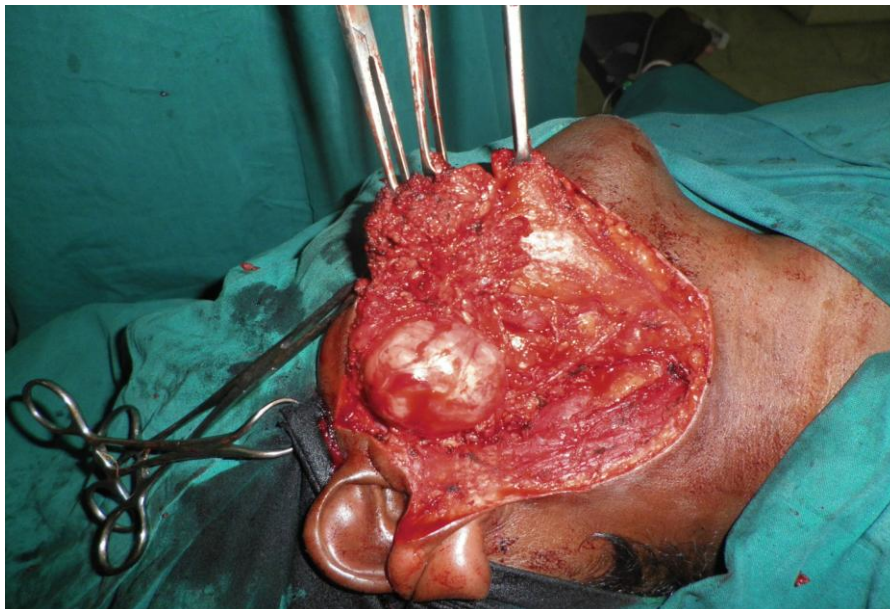

Fig 3a : Elevation Of Anterior Flap During Superficial Parotidectomy In Case Of Right Sided Parotid Swelling

III. Dissection

- For a parotidectomy to be performed safely, wide exposure and knowledge of important anatomic landmarks are key.
- The operation begins in the plane deep to the tail of the parotid. The fascia along the anterior border of the SCM muscle is incised, exposing the muscle toward the level of the mastoid process. Electrocautery can be used in this dissection .
- The greater auricular nerve and external jugular vein are identified at this time. If the nerve has multiple branches, the posterior branch is preserved to maintain sensation to the external ear. Maximal nerve length is dissected in the event that it is needed for a facial nerve graft .
- As the dissection proceeds anteriorly, the tail of the parotid is dissected from the SCM muscle and mastoid process, and the posterior belly of the digastric muscle is exposed. The gland is retracted using an Allis clamp or a hemostat .
- The posterior belly of the digastric muscle is further exposed toward its origin by retracting the SCM muscle posteriorly and both sharply and bluntly dissecting the tissue overlying the muscle .The posterior aspect of the gland is now dissected from the external auditory canal. The parotid tissue is carefully bluntly and sharply dissected from the ear canal using a fine curved hemostat or scissors and bipolar cautery to maintain hemostasis. It is critical to maintain absolute hemostasis in order to identify the facial nerve trunk to avoid injury .

- Once the parotid gland is freed from its fibrous attachments, blunt dissection along the ear canal perichondrium using a finger will allow the surgeon to palpate the bony-cartilaginous junction of the ear canal, the tympanomastoid fissure, and the tragal pointer .
- The main trunk of the facial nerve is now close by. It is approximately 1 cm deep to the tip of tragal pointer (anterior and inferior), 6 to 8 mm below the end of the tympanomastoid fissure (groove palpated separating the mastoid tip from the tympanic portion of the temporal bone), and just above and on the same plane as the attachment of the digastric muscle in the digastric groove.
- The remaining bridge of parotid tissue located between the superior border of the posterior belly of the digastric muscle and the external auditory canal is now dissected.
- The mobilized portions of the parotid gland are retracted anteriorly, putting the residual parotid tissue on stretch. A retractor is placed so that the posterior belly of the digastric muscle is also exposed during this dissection.
- This tissue is bluntly and sharply dissected, layer by layer, to expose the junction of the superior aspect of the posterior belly of the digastric muscle and the tympanomastoid fissure. The tips of the dissecting instrument face upward and dissection is done along a broad front .
- Once the temporoparotid fascia, which runs from the tympanomastoid fissure to the gland is transected, parotid tissue is released and the facial nerve will be easily identified,
- The *nerve stimulator(mapper)* should be used only if there is a question as to the identity of the main trunk of the facial nerve (Fig.3b)

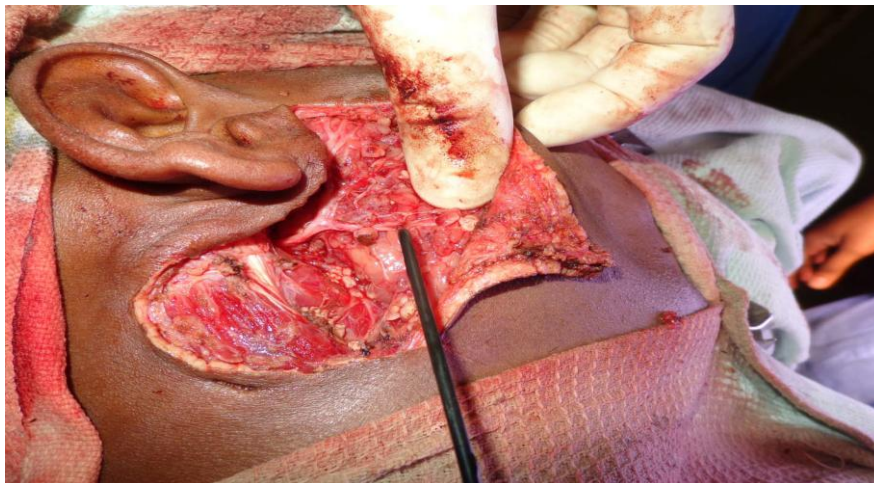


Fig 3b : Using Nerve Mapper And Tracing Cervico-Facial

Branch Of Facial Nerve During Superficial Parotidectomy In Case Of Right Sided –Pleomorphic Adenoma

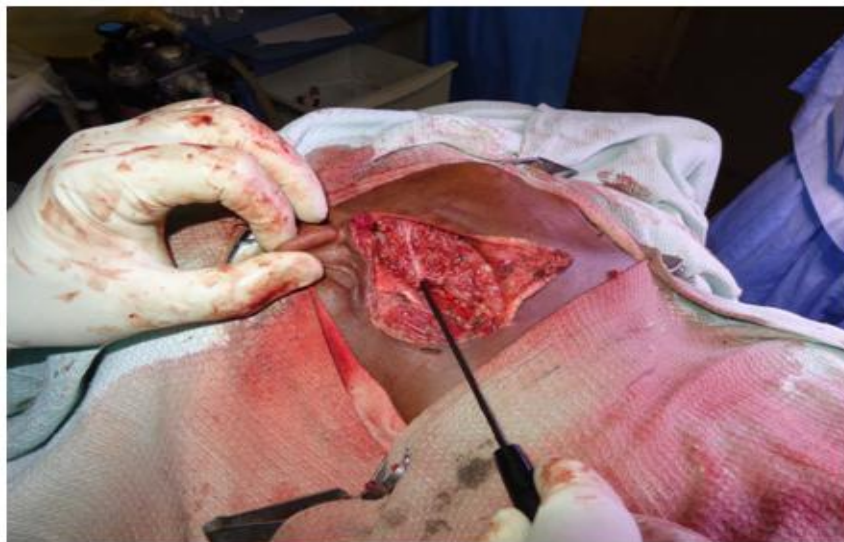

Fig 4: Using nerve mapper and confirming that all Branches are intact by keeping mapper over root/trunk of facial nerve and observing twitching of facial muscles during superficial Parotidectomy

Following identification of the main trunk, dissection proceeds in a plane superficial to the nerve. A curved hemostat or scissors, with tips facing upward, is used to spread the tissue immediately superficial to the nerve, keeping the nerve under direct vision at all times. The main trunk is dissected anteriorly until the pes anserinus is reached. The upper (zygomaticotemporal) and lower (cervicofacial) divisions are identified. Dissection of individual facial nerve branches to the periphery of the gland is performed in an orderly fashion. Dissection can proceed from inferior to superior or superior to inferior, depending on tumor location.

A fine curved hemostat or scissors is used to dissect just on top of the nerve, elevating the parotid tissue off the nerve. The instrument is opened, spreading the parotid tissue and exposing the nerve. The tissue is cut in a horizontal plane parallel to the nerve. **If the nerve is not visualized, do not cut the tissue!** Once a nerve branch is completely exposed, the surgeon again returns to the major division where he or she was working and the next nerve branch in sequence is exposed. This is done until all the branches are exposed and the gland is removed. The parotid tissue is retracted forward using Allis clamps and other retractors during the dissection. In this example, the benign tumor is located in the tail of the parotid. The branches of the lower division are dissected and the tumor is removed with a large cuff of parotid tissue. Care should be taken to avoid injury to the marginal mandibular branch while ligating the posterior facial vein. In addition, the “flanking maneuver” (swinging around the tail of the parotid) should also be avoided because it may also result in injury to the marginal mandibular branch (most common site of injury).

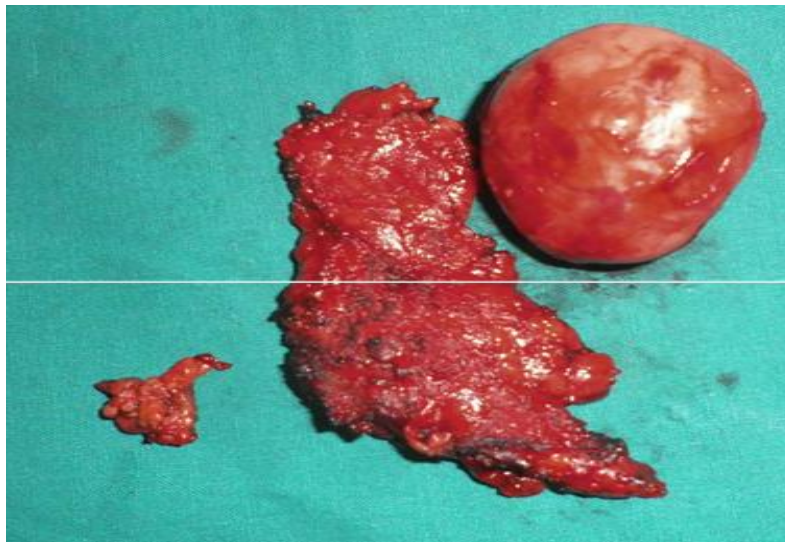


Fig 5: Specimen Following Superficial Parotidectomy

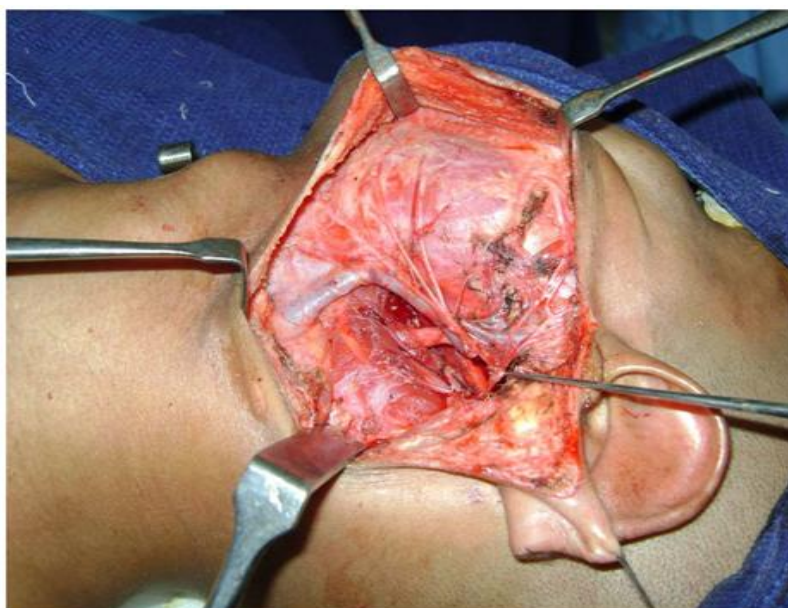


Fig 6 : Parotid Bed Following Total Parotidectomy In Case Of Mucoepidermoid Carcinoma Of Parotid On Left Side

Intraoperative Facial Nerve Monitoring

Intraoperative neurophysiological monitoring has been used with an increasing frequency in thyroid gland surgery as well as in cerebellopontine angle surgery. Some authors also recommend the regular use of neuromonitoring in middle ear surgery for protection of the facial nerve. Electrophysiological monitoring of the Facial Nerve helps us easy identification by which it prevents injury during surgery. In 1961 Dr Thomas W Kavanagh described about this technique. Concerning parotid gland surgery there are still many divergent opinions.

Whereas many authors consider the intraoperative monitoring of the facial nerve using nerve mapper helpful in difficult conditions such as revisional surgery there is still a lot of discussion about its necessity in routine parotid gland surgery. The risk factors of postoperative facial nerve palsy previously reported includes type of surgery, malignancy, size of tumour, inflammation, patient's age, h/o previous parotid surgery and duration of surgery. Of these, surgical factors, ischemia were thought to be the most important factors rather than oedema and stretching of facial nerve branches. Even temporary paresis carries - not to mention the esthetic disfigurement of the patient - the risk of permanent corneal damage due to insufficient eyelid closure and ought to be avoided if possible. The intraoperative neuromonitoring of the facial nerve facilitates the identification of the nerve and allows a constant supervision of neural function. Arguments frequently mentioned against the routine use of neuromonitoring are the additional time required and the possible lack of accuracy. Some fear that the routine use of neuromonitoring may lead to a situation where younger surgeons would not be able anymore to perform parotid surgery without monitoring or where surgeons not using a monitoring device may expose themselves to possible legal problems. Others are afraid that the surgeon, due to a false sense of security, might be tempted to work faster and will not be careful enough. Facial nerve monitoring may be performed with different electromyography devices. The Neurosign100 and the Nerve Integrity Monitor2 are frequently used systems.

In this present study we used nerve locator–mapper to monitor facial

nerve during parotid surgery. It is very useful in locating peripheral motor nerve like facial nerve. The aim is to stimulate the nerve using nerve locator-mapper by which twitching of the facial muscles supplied by facial nerve, can be observed.

Nerve Locator –Mapper

Electrical nerve locator–mapper is used as an aid to peripheral nerve blockade and localization of nerve trunks. It delivers currents in the range of 0.1 -0.3mA which will not damage the nerve.

Precautions

It cannot be used after paralysis with neuromuscular blocking drugs. Because of this we put on the patient under ETGA using inhalational anaesthetic agents like Halothane, sevoflurane etc and keeping the patient on spontaneous respiration.

Mechanism of action Electrophysiology Energy

The amount of electrical energy required to propagate a nerve impulse is a product of the stimulus strength (mAmps) and current duration (msecs). For any nerve type there is a minimum current strength required, to generate an impulse – the rheobase. Below this level, an impulse will not be generated; no matter for how long the current is applied. Chronaxie is the length of time the current must be applied to the nerve to initiate an impulse when the current level is twice the rheobase.

Distance

According to Coulomb's law minimum current required to stimulate the nerve is directly proportional to square of the distance from the nerve. so more the distance of the nerve from the locator more will be the current required.

Polarity

Most modern peripheral nerve block stimulators have the cathode being as the needle. ie; the needle is negative. It is better to have the needle as the cathode because if the needle is positive (the anode) then the nerve will get hyperpolarised and a larger current will be needed to depolarise the nerve and obtain a response.

Frequency

The ideal electric parameters for comfortable stimulation is 1 to 2 Hz. A higher frequency will give more frequent feedback to the operator, but often causes greater discomfort to the patient. If too low a frequency is used then there is a risk of nerve impalement between current impulses.

IV. Method

First we have to fix the remote electrode(positive) over the shoulder on the same side of the parotid lesion. The set current is delivered between the tip of the nerve mapper(negative) and the remote electrode. The maximum and minimum current delivered by most electrical nerve locator mapper is 5mA and 0.1mA respectively. All the branches of the facial nerve are located separately in similar fashion and

preserved.

Advantages

- Easier to locate the nerve,
- Not totally depended on the anatomy,
- Better localization of nerve trunk in difficult situation,
- Less chance of nerve damage,
- Can be used on anaesthetized non paralyzed patients,
- Valuable tool for training purpose.

Disadvantages

- It is only applicable to peripheral motor nerves and not to mixed or sensory nerves,
- It cannot be used after paralysis with neuromuscular blocking agents.

House Brackmann Scoring⁵⁴

The House-Brackmann score used to grade the degree of nerve injury in facial nerve paralysis. The measurement is determined by measuring the upward (superior) movement of the mid-portion of the top of the eyebrow, and the outward(lateral) movement of the angle of the mouth. Each reference point scores 1 point for each 0.25 cm movement, upto a maximum of 1cm. The scores are then added together, to give a number out of 8.

Grade	Description	Measurement	Function %	Estimated function %
I	Normal	8/8	100	100
II	Slight	7/8	76 to 99	80
III	Moderate	5/8 to 6/8	51 to 75	60
IV	Moderately severe	3/8 to 4/8	26 to 50	40
V	Severe	1/8 to 2/8	1 to 25	20
VI	Total	0/8	0	0

V. Materials And Methods

This was an observational and interventional study for checking the risk of facial nerve palsy following parotidectomy and to assess the outcome of facial nerve monitoring. Facial nerve damage was assessed by using House-Brackmann score on 1st postoperative day, after a week, after a month and if still persisting after a month, again reassessed after 6 months.

House-Brackmann Score - Calculated by measuring the upward movement of midportion of top of eyebrow and outward movement of angle of mouth. 1 point was given for each 0.25cm movement upto a maximum of 1 cm. Scores are added to give a number out of 8.

Grade Facial palsy Score

Grade	Facial palsy	Score
I	Normal	8
II	Slight	7
III	Moderate	5-6
IV	Moderately severe	3-4
	Severe	1-2
VI	Total	0

Study material

Longitudinal study - Prospective.

Study period

1 ½ years.

Sample size

36

Inclusion criteria

All cases of parotid swellings who underwent parotid surgery at **Dhanalakshmi Srinivasan Medical College & Hospital**Perambalur TAMILNADU INDIA

Exclusion criteria

- 1) Cases <13 years of age
- 2) Cases with inflammatory and post traumatic parotid swellings.

VI. Observations

Table 1

	Age	Preoperative House Brackmann score	Postop Day 1	Postop Day 7	At The End Of 1month
Number	36	36	36	36	36
Mean	48.14	7.94	6.78	7.56	7.81
Standard deviation	13.87	0.333	1.124	1.107	0.822
Minimum	24	6	3	3	4
Maximum	80	8	8	8	8

In this study, 36 cases of parotid tumours were analysed who underwent surgery at Dhanalakshmi Srinivasan Medical College & Hospital Perambalur. Parotid tumors were observed in the age group of 24-80 years. The mean age was found to be 48.14 with a standard deviation of 13.87. The mean House Brackmann score preoperatively, 1st postoperative day, after 7 days and after 1 month were found to be 7.94, 6.78, 7.56 and 7.81 respectively.

Table 2: Sex distribution

Sex	Frequency	Percentage
Male	22	61.1
Female	14	38.9

The study population included 22 males (61.1%) and 14 females (38.9%).

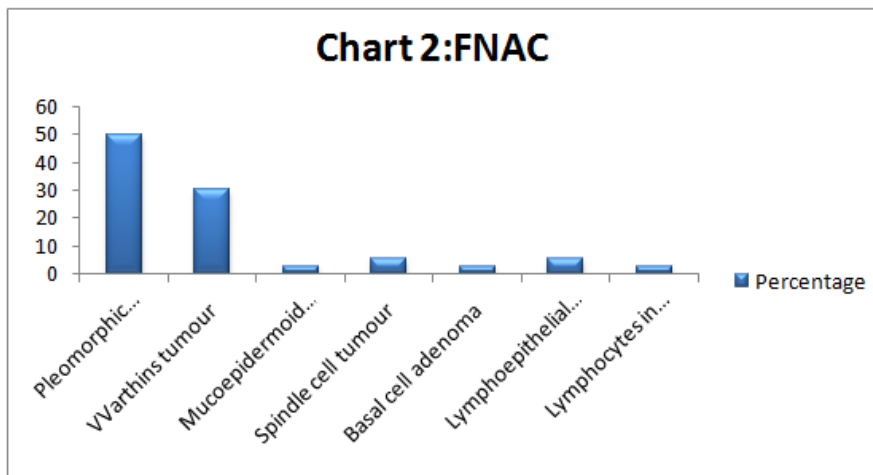
Table 3: Presenting complaints

Presenting Complaints	Frequency	Percentage
Swelling left cheek	17	47.2
Swelling right Cheek	19	52.8

All 36 cases presented with swelling on their cheek, of which 17 were on the left side and 19 on the right.

Table 4: Fnac

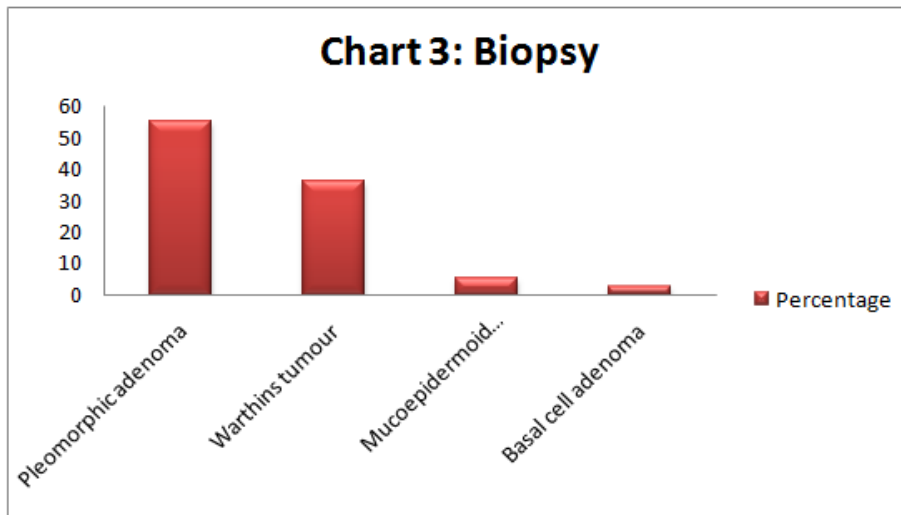
FNAC	Frequency	Percentage
Pleomorphic adenoma	18	50
Warthin's tumour	11	30.6
Mucoepidermoid carcinoma	1	2.8
Spindle cell tumour	2	5.6
Basal cell adenoma	1	2.8
Lymphoepithelial cyst	2	5.6
Lymphocytes in fluid background	1	2.8



Out of the 36 cases, 18 cases (50%) were found to be pleomorphic adenoma by FNAC study. Only one case of malignant parotid tumour was identified and it was mucoepidermoid carcinoma.

Table 5: Biopsy

Biopsy	Frequency	Percentage
Pleomorphic adenoma	20	55.6
Warthins tumour	13	36.1
Mucoepidermoid carcinoma	2	5.6
Basal cell adenoma	1	2.8



Pleomorphic adenoma was the commonest tumour and constituted 55.6% of all the tumours. Malignant parotid tumours comprised 5.6% of the tumours

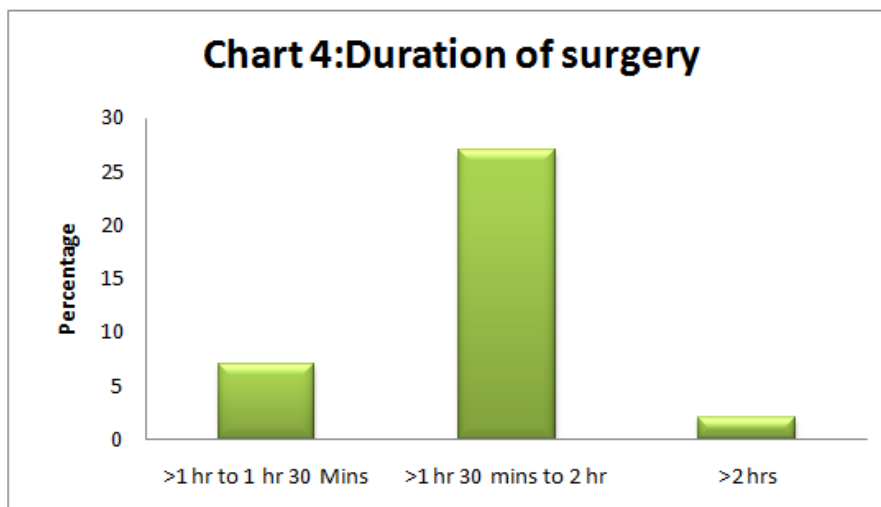
Table 6: Surgery

Surgery	Frequency	Percentage
Superficial parotidectomy	34	34.4
Total Parotidectomy	2	5.6

Of the total cases, superficial parotidectomy was done for 34 cases (94.4%) and total parotidectomy for 2 cases (5.6%)

Table 7: Duration of Surgery

Duration of surgery	Frequency	Percentage
>1 hr to ≤ 1 hr 30 Mins	7	19.4
>1 hr 30 mins to ≤2 hr	27	75
>2 hrs	2	5.6



75% of the surgeries were done in the time frame of >1 hr 30 mins to ≤2 hours.

Table 8: Preoperative assessment of facial nerve

	Frequency	Percentage
No facial palsy	35	97.2
Facial palsy	1	2.8

Out of 36 cases, 1 case had preoperative facial nerve palsy.

Table 9: Whether facial nerve monitor use

	Frequency	Percentage
Used	18	50
Not used	18	50

Intraoperative facial nerve monitoring was done for 18 cases (50%)

Table 10: Postoperative facial nerve palsy

	Frequency	Percentage
Present	26	72.2
Absent	10	27.8

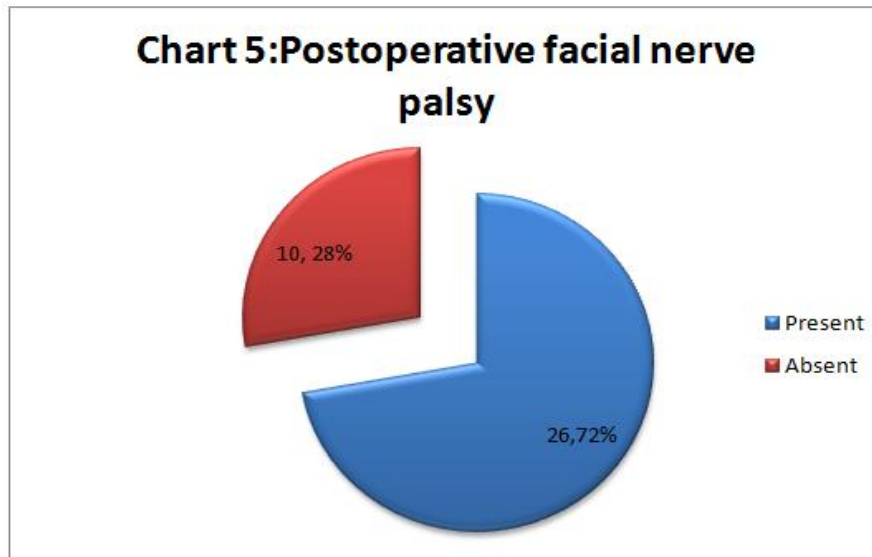


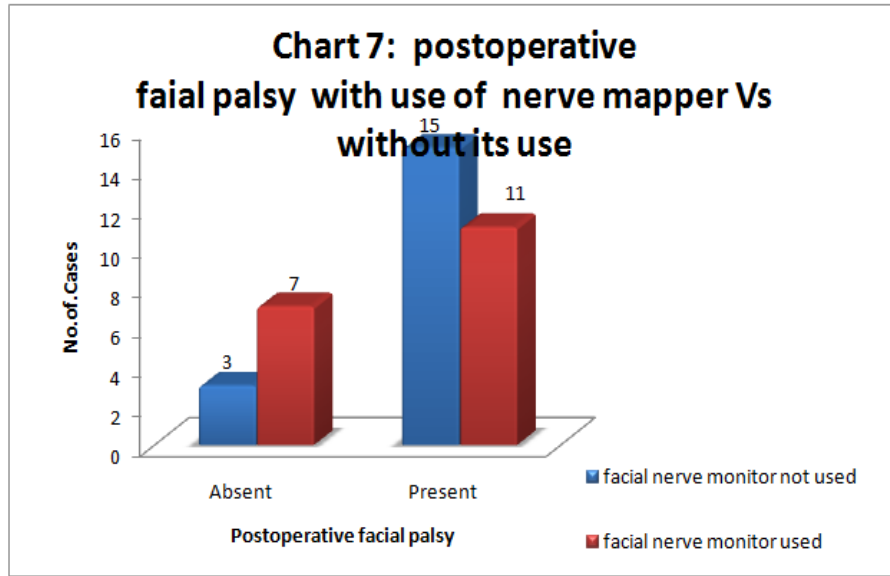
Table 11: Type of facial nerve palsy

	Frequency	Percentage
No palsy	10	27.8
Transient palsy	24	66.7
Permanent palsy	2	5.6

72% of the cases were found to have postoperative facial palsy. 24 cases (66.7%) developed transient facial palsy while 2 cases (5.6%) developed permanent facial palsy. Of the 2 cases, who developed permanent facial palsy, 1 had preoperative facial nerve palsy.

Table 12: Postoperative facial palsy with use of nerve mapper Vs without its use

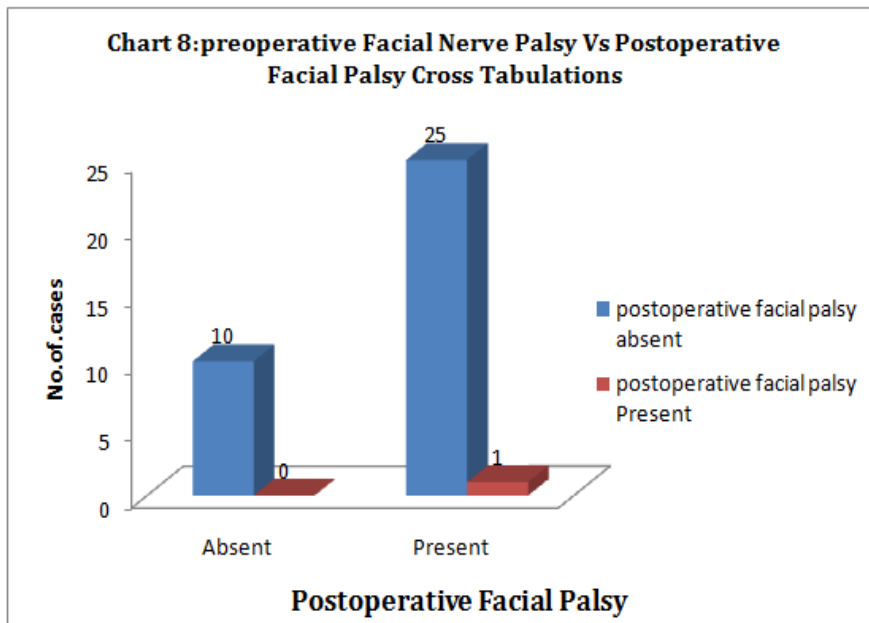
Use of nerve mapper	Postoperative facial palsy				Total	
	Absent		Present		No	%
	No	%	No	%		
No	3	16.7	15	83.3	18	100
Yes	7	38.9	11	61.1	18	100
Total	10	27.8	26	72.2	36	100



Among the population in which facial nerve monitor was not used, 83.3% developed postoperative facial palsy .Among the monitored cases, only 61.1% developed facial palsy postoperatively . So we can observe that there has been a 22% decrease in the incidence of postoperative facial palsy in the study population where intraoperative facial nerve monitor was used .p value was found to be 0.137, hence it is not statistically significant.

Table 13: Preoperative facial nerve palsy Vs postoperative facial palsy cross tabulations

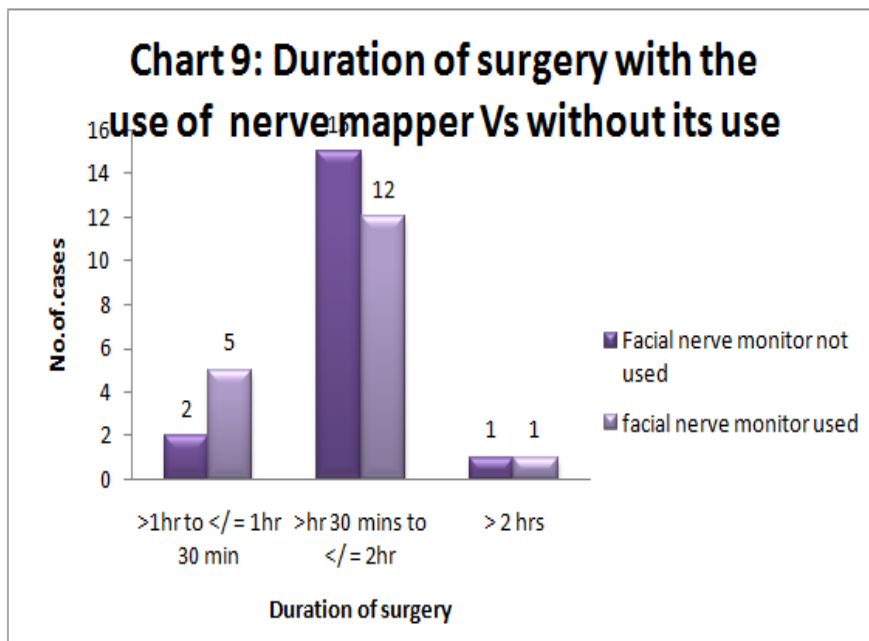
Preoperative Palsy	Facial	Postoperative Facial Palsy				Total	
		Absent		Present		No	%
		No	%	No	%		
Absent		10	28.6	25	71.4	35	100
Yes		0	0	1	100	1	100
Total		10	27.8	26	72.2	36	100



26 out of 36 cases (72.2%) developed postoperative facial palsy.66.7% were found to have only transient facial nerve palsy. By t-test, p value was found to be <0.001 and hence the risk of facial nerve palsy after parotidectomy was found to be statistically significant.

Table 14: Duration of surgery with the use of nerve mapper Vs without its use Independent sample t – test

Usage of facial Nerve Monitor	N	Mean Duration	Std Deviation	Srd.Error Mean
Not used	18	108.89	13.123	3.093
Used	18	94.44	14.337	3.379



An independent sample t-test was conducted to compare the duration of surgery among the cases in which facial nerve monitor was used and those in which it was not used. There was a significant difference in duration (minutes) between the unmonitored subjects (mean – 108.89 mins , SD = 13.123 mins and the monitored subjects)

(mean – 94.44 mins, SD = 14.337 mins); $t(36) = 3.153$, $p = 0.003$, two tailed. The mean difference = 14.44, 95%, confidence interval : 5.134 to 23.75. In the present study, 36 patients were analysed who underwent parotidectomy from Dhanalakshmi Srinivasan Medical College & Hospital Perambalurof of which intraoperative facial nerve monitor was used in 18 cases and not used in the rest.

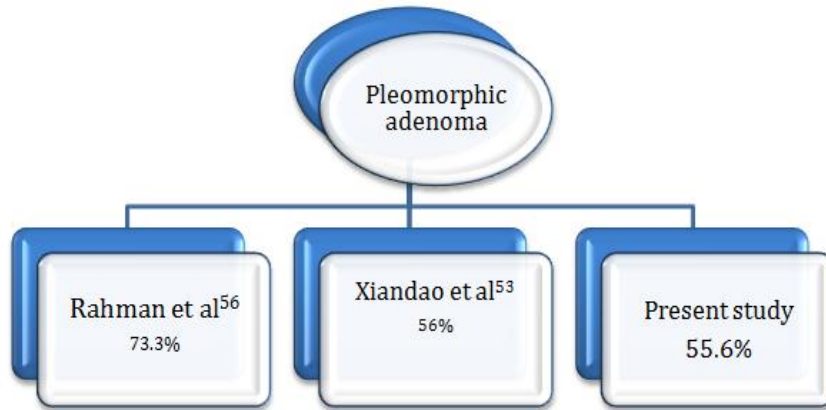
Sex	Preis et al ⁵⁵	Xiandao et al ⁵³	Present study
Male	62.1%	51.5%	61.1%
Female	37.9%	49.5%	38.9%

Parotid tumours were more commonly found in male population. 61.1% of the study population was found to be males. Findings of the present study was similar to the study conducted by Preis et al in which incidence among male population was found to be 62.1%.

Histopathology

Histopathology	Rahman et al ⁵⁶	Tsai HM et al ⁵⁷	Present study
Benign	83.33%	85%	94.4%
Malignant	16.67%	12%	5.6%

Most of the parotid swellings were found to be benign. 94.4% of parotid tumours were found to be benign and 5.6% malignant. Other studies also recorded a high incidence of benign swellings even though the percentage was found to be lower when compared to the present study.



Pleomorphic adenoma was the most common benign parotid tumor which constituted 55.6% of parotid tumors. Its incidence was found to be 73.3% in Rahman et al study. Findings of the present study were comparable with the study conducted by Xiandao et al in which he detected 56% incidence of pleomorphic adenoma.

Postoperative facial palsy

	Henri Laccourreya et al ⁵⁸	Cleveland clinic foundation	Meier et al ⁶⁰	Rahman et al ⁵⁶	Present study
Facial palsy	70.2%	50%	65%	36.6%	72.2%
Transient	64.6%	46.1%	43%	26.6%	66.7%
Permanent	5.6%	3.9%	22%	10%	5.6%

72.2% of the patients developed postoperative facial palsy of which 66.7% was transient and 5.6% permanent. These findings were comparative to the study conducted by Henri Laccourreya et al in which 70.2% developed postoperative facial palsy, of which 64.6% were transient and 5.6% permanent. Most patients regained normal facial nerve function by 1 month after surgery. This observation has an important implication for the management of post parotidectomy facial nerve palsy. Transient facial palsy is a cosmetic problem and patients should be assured that their appearance would return to normal with time.

Risk of permanent facial palsy was 5.6% in the present study. The incidence of permanent facial palsy was found to be much higher in studies conducted by Meier et al and Rahman et al.

Intraoperative facial nerve monitoring

Facial nerve monitor	Postoperative facial palsy					
	Terrell et al ⁶¹		Witt RL ⁵		Present study	
	Yes	No	Yes	No	Yes	No
Used	43.6%	56.4%	20%	80%	61.1%	38.9%
Not used	62.3%	37.7%	15%	85%	83.3%	16.7%

Only very few studies have been conducted worldwide for assessing the role of intraoperative facial nerve monitors in reducing postoperative facial palsy. In the present study, 83.3% of the cases in which facial nerve monitor was not used developed postoperative facial palsy whereas 61.1% of the population in which monitoring was done developed facial palsy. P value was found to be 0.137, hence not statistically significant. When we look back into the literature, we get conflicting ideas regarding the usage of intraoperative facial nerve monitoring in parotidectomy. Study conducted by Terrell et al showed a better prognosis for facial function among the study population in which intraoperative facial monitoring was done. But a study by Witt RL showed a deterioration in facial nerve prognosis among the monitored population. Grosheva et al⁶² conducted a study of 100 parotidectomies of which for 50 cases, he used intraoperative facial nerve monitoring and no monitoring was done in the other 50. He got a p value of 0.23 stating that use of intraoperative facial nerve monitors had no statistically significant effect in postoperative facial palsy. But he found that, the duration of surgery was significantly reduced in the monitored group with a p value of 0.02. In the present study also, usage of intraoperative facial nerve monitor was found to have a statistically significant relation in reducing the duration of surgery (p value -

0.003). In difficult parotidectomies, especially in malignancies it was found that, usage of intraoperative facial nerve monitor eases the identification of facial nerve and thereby significantly reduces the duration of surgery

VII. Conclusions

1. Parotid tumours are more commonly seen in male population (61.1%).
2. Mean age of parotid tumours were found to be 48.14 years.
3. All patients presented with a swelling or palpable mass.
4. Most of the parotid tumours were benign (94.4%).
5. Pleomorphic adenoma was the commonest tumour (55.6%).
6. Postoperative facial palsy was significantly associated with parotidectomy.
7. Most of the cases developed transient facial palsy (66.7%) while only very few developed permanent palsy (5.6%).
8. Most patients regained normal facial function by 1 month after surgery.
9. Intraoperative facial nerve monitoring has shown to decrease the incidence of postoperative facial nerve palsy by 22%, even though not statistically significant.
10. Usage of intraoperative facial nerve monitors during parotidectomy is helpful for easy identification of the facial nerve trunk and branches, especially for the upcoming surgeons.
11. Intraoperative facial nerve monitoring is significantly associated with decrease in the duration of surgery.

References

- [1]. Sabiston text book of surgery; 19th edition; 2012.
- [2]. Kerawala CJ, McAloney N, Stassen LFA. Prospective randomized trial of the benefits of a sternocleidomastoid flap after superficial parotidectomy. *Br J Oral Maxillofacial surgery* 2002; 40: 468-472
- [3]. Marchese-Ragona R, Filippis C De, Marioni G, Staffieri A. Treatment of complications of parotid gland surgery. *ActaOtorhinolaryngol Ital* 2005; 25(3): 174-178.
- [4]. Patey DH. Risk of facial paralysis after parotidectomy. *Br MedJ*1963; 2(5365): 1100-1102.
- [5]. Witt RL. Facial nerve monitoring in parotid surgery: the standard of care? *Otolaryngological Head Neck Surgery* 1999; 121(6): 846.
- [6]. www.indesignscripts.ucoz.ru/PortFolio/Glands-New-60-84-8-.pdf
- [7]. Arey LB (1974) Developmental anatomy; a textbook and laboratory manual of embryology. Revised 7th ed. W.B. Saunders, Inc., Philadelphia.
- [8]. Gibson MH. The prenatal human submandibular gland: a histological, histochemical and ultrastructural study. *AnatAnz*1983; 153:91-105.
- [9]. Bernfield M, Banerjee S, Cohn R. Dependence of salivary epithelial morphology and branching morphogenesis upon acid muco polysaccharide-protein (proteoglycan) at the epithelial surface. *J Cell Biol*1972; 52:674-689.
- [10]. Johns M. The salivary glands: anatomy and embryology. *OtolaryngolClin North Am* 1977; 10(2): 261-71.
- [11]. Jaskoll T, Melnick M. Submandibular gland orphogenesis: stage- specific expression of TGF-alpha/EGF, IGF, TGF-beta, TNF, and IL-6 signal transduction in normal embryonic mice and the phenotypic effects of TGFbeta2, TGF-beta3, and EGF-r null mutations. *Anat Rec* 1999; 256:252-268.
- [12]. Davis RA, Anson BJ, Budinger JM, et al. Surgical anatomy of the facial nerve and parotid gland based upon a study of 350 cervicofacial halves. *SurgGynecolObstet*1956; 102: 385-412.
- [13]. Grant J (1972). *An Atlas of Anatomy*, Sixth edn. Williams & Wilkins, Baltimore.
- [14]. Frommer J. The human accessory parotid gland: its incidence, nature, and significance. *Oral Surg Oral Med Oral Pathol*1977; 43: 671-676.
- [15]. Orabi AA, Riad MA, O'Regan MB. Stylomandibular tenotomy in the transcervical removal of large benign parapharyngeal tumours. *Br J Oral MaxillofacSurg*2002; 40: 313-316.
- [16]. Pogrel M, Schmidt B, Ammar A. The relationship of the buccal branch of the facial nerve to the parotid duct. *I Oral MaxillofacSurg*1996; 54:71-73.
- [17]. Myers EN, Conley J. Gustatory sweating after radical neck dissection. *Arch Otolaryngol*1970; 91: 534-542.
- [18]. Roark DT, Sessions RB, Alford BR. Frey's syndrome technical remedy. *Ann OtolRhinolLaryngol*1975; 84:734-73.
- [19]. Bhattacharyya N, Varvares M. Anomalous relationship of the facial nerve and the retromandibular vein: a case report. *J Oral MaxillofacSurg*1999; 57: 75-76.
- [20]. Garatea-Crelgo J, Gay-Escoda C, Bermejo B, et al. Morphological study of the parotid lymph nodes. *J CraniomaxillofacSurg*1993; 21:207-209.
- [21]. Carrau RL, Johnson JT, Myers EN. Management of tumors of the parapharyngeal space. *Oncology (Williston Park)* 1997; 11: 633-- 640.
- [22]. *A manual on clinical surgery* by S. Das; 6th edition; 2008.
- [23]. Gritzmann N. Ultrasound of the salivary glands. *Laryngorhinootologie*. 2009; 88(1): 48-56.
- [24]. Cheung RL, Russell AC, Freeman J. Does routine preoperative imaging of parotid tumours affect surgical management decision making? *J Otolaryngol Head Neck Surg*2008; 37(3): 430-4.
- [25]. Bartels S, Talbot JM, DiTomasso J, et al. The relative value of fine-needle aspiration and imaging in the preoperative evaluation of parotid masses. *Head Neck* 2000; 22(8): 781-6.
- [26]. Wong DS, Li GK. The role of fine-needle aspiration cytology in the management of parotid tumors: a critical clinical appraisal. *Head Neck* 2000; 22(5): 469-73.
- [27]. Patel AA. Facial Nerve Anatomy. <http://emedicine.medscape.com>. 2012.
- [28]. Lohuis PJFM, Tab ML, Bonte K et al. Superficial parotidectomy via facelift incision. *Annals of Otolology, Rhinology and Lagngology*2009;118(4): 276-280.

Risk Of Facial Nerve Palsy Following Parotidectomy And Outcome Of Facial Nerve Monitoring

- [29]. Spiro JD, Spiro RH. Cancer of the parotid gland: role of 7th nerve preservation. *World J Surg*2003; 27: 863-867.
- [30]. Spiro RH, Huvos AG, Strong EW. Cancer of the parotid gland: a clinicopathologic study of 288 primary cases. *AmJSurg*1975; 130: 452-459.
- [31]. Spiro RH. Salivary neoplasms: overview of a 35 year experience with 2,807 patients. *Head Neck Surg*1986; 8: 77-84.
- [32]. Schwartz's Surgery Part II. Disorders of the Head and Neck. Specific Considerations. Chapter 17.
- [33]. Emerick KS, Fabian RL, Deschler DG. Clinical presentation, management, and outcome of high-grade mucoepidermoidcarcinoma of the parotid gland. *Otolaryngol Head Neck Surg.* 2007; 136(5): 783-7.
- [34]. Grosheva M, Klussmann JP, Grimminger C, Wittekindt C, Beutner D, Pante' M, et al. Electromyographic facial nerve monitoring during parotidectomy for benign lesions does not improve the outcome of postoperative facial nerve function: a prospective two-center trial. *Laryngoscope* 2009;119(12):2299-305.
- [35]. Meier JD, Wenig BL, Manders EC, Nenonene EK. Continuous intraoperative facial nerve monitoring in predicting postoperative injury during parotidectomy. *Laryngoscope* 2006;116(9): 1569-72.
- [36]. O'Brien CJ. Current management of benign parotid tumours - the role of limited superficial parotidectomy. *Head Neck* 2003; 25: 946-952.
- [37]. Cesteleyn L, Helman J, King S, Van de Vyvere G. Temperopareital fascia flaps and superficial musculoaponeurotic system placcation in parotid surgery reduces Frey's syndrome. *J Oral MaxillofacSurg*2002; 60: 1284-1297.
- [38]. Kuttner C, Berens A, Troger M, Keil C, Eckardt A. Frey- syndrome nachlateralerparotidektomie, Nachuntersuchung und therapeutischerAusblick. *Mund Kiefer Gesichtschir*2001; 5: 144- 149.
- [39]. Linder TE, Huber A, Schmid S. Frey's syndrome after parotidectomy: a retrospective and prospective analysis. *Laryngoscope* 1997; 107: 1496-1501.
- [40]. Biglioli F, D'Orto O, Bozzetti A, Brusati R. Function of the great auricular nerve following surgery for benign parotid disorders. *J CraniomaxillofacSurg*2002; 30: 318-321.
- [41]. Fee WE Jr, Tran LE. Functional outcome after totalparotidectomy reconstruction. *Laryngoscope* 2004; 114: 223-226.
- [42]. Hui Y, Wong DSY, Wong L-Y, Ho W-K, Wei WI. A prospective controlled double-blind trial of great auricular nerve preservation at parotidectomy. *Am J Surg*2003; 185: 574-579.
- [43]. Leverstein H, Van Der Wal JE, Tiwari RM, Van Der Waal I, Snow GB. Surgical management of 246 previously untreated pleomorphic adenomas of the parotid gland. *Br J Surg*1997; 84: 399-403.
- [44]. Patel N, Har-el G, Rosenfeld R. Quality of life after great auricular nerve sacrifice during parotidectomy. *Arch OtolaryngolHead Neck Surg*2001; 127: 884-888.
- [45]. Vieira MB, Maia AF, RibeiroJc. Randomized prospective study of the validity of the great auricular nerve preservation in parotidectomy. *Arch Otolaryngol Head Neck Surg*2002; 128: 1191- 1195.
- [46]. Brown AM, Wake MJ. Accidental full thickness burn of the earlobe following division of the great auricular nerve at parotidectomy. *Br J Oral MaxillofacSurg*1990; 28: 178-179.
- [47]. *Mastery of Surgery*. 5thedn. Vat III - Head and Neck, Chapter 21, Parotid gland.
- [48]. Devita, Hellman & Rosenberg's *Cancer Principles & Practice of Oncology*, 8th Edition, Volume 1, Part 3 - Practice of Oncology, Chapter 36. Cancer of the Head and Neck.
- [49]. Lathrop F. Management of the facial nerve during operations on the parotid gland. *Ann Otol Rhino! Laryngol*1963; 72: 780-801.
- [50]. Pillsbury HC, Fisch U. Extratemporal facial nerve grafting and radiotherapy. *Arch Otolaryngol*1979; 105: 441-446.
- [51]. Conley JJ. Facial nerve grafting. *Arch Otolaryngol*1961; 73: 322- 327.
- [52]. McGuirt WF, Welling B, McCabe BF. Facial nerve function following irradiated cable grafts. *Laryngoscope* 1989; 99: 27-34.
- [53]. Yuan X, Gao Z, Jiang H, Yang H, Wei Lv, Wang Z, Niu Y, Feng G. Predictors of facial palsy after surgery for benign parotid disease: Multivariate analysis of 626 operations. *Head and Neck* 2009; 31(12): 1588-1592.
- [54]. House JW, Brackmann DE. "Facial nerve grading system". *Otolaryngol Head Neck Surg*1985; 93: 146-147.
- [55]. Preis M, Soundry E, Bachar G, Shufel H, Feinmesser R, ShpitzerT. Predicting facial nerve invasion by parotid gland carcinoma and outcome of facial reanimation. *Eur Arch Otorhinolaryngol*2010; 267: 107-111.
- [56]. Rahman MA, Alam MM, Joarder AH. Nepalese Journal of ENT. *Head and Neck Surgery* Vol.2, No.1 Issue 1. Society of Otolaryngologists of Nepal. Jan-June 2011. Study of Nerve Injury in parotid gland surgery.
- [57]. Lin CC, Tsai MH, Huang CC, Tseng HC, Huang ST. Parotid tumours - a 10 year experience. *Arn J Otolaryngol*2008; 29(2): 94-1000.
- [58]. Laccourreye H, Laccourreye O, Cauchois R, Jouffre V, Menard M, Brasnu D. Total conservative parotidectomy for primary benign pleomorphic adenoma of the parotid gland: A 25 year experience with 229 patients. *The laryngoscope* 1994; 104(12): 1487-1494.
- [59]. Mehle ME, Krans DH, Wood BG, Benminger MS, Eliacher I, Levmett L, Tucker HM, Lavertn P. Facial nerve morbidity following parotid surgery for benign following parotid surgery for benign disease - Cleveland Clinic Foundation Experience. *Laryngoscope* 1993; 103 (4 pt 1): 386-8.
- [60]. Meier JD, Wenig BL, Manders EC, Nenonene EK. Continuous intraoperative facial nerve monitoring in predicting postoperative injury during parotidectomy. *Laryngoscope* 2006; 116(9); 1569-72
- [61]. Ternell JE, Kileny PR, Yian C, Eslamado RM, Bradford CR, Pillsbury MS, Wolf GT. Clinical outcome of continuous facial nerve monitoring during primary parotidectomy. *Arch Otolaryngol Head and Neck Surg*1997; 123(10): 1081-7.
- [62]. Grosheva M, Klussmann JP, Grimminger C, Wittekindt C, Beutner D, Pantel M, Volk CF, Guntinas-Lichins O. Electromyographic facial nerve monitoring during parotidectomy for benign lesions does not improve the outcome of postoperative facial nerve function: a prospective two center trial. *Laryngoscope* 2009; 119(12): 2299-305.

1Dr.Maragathamani Elangovan. "Risk of Facial Nerve Palsy Following Parotidectomy And Outcome of Facial Nerve Monitoring Using Nerve Mapper." *IOSR Journal of Dental and Medical Sciences (IOSR-JDMS)* , vol. 16, no. 10, 2017, pp. 15–29.