

Sealbio: A Novel, Non-Obturation Endodontic Treatment

*Dr. Saima Jamal¹, Dr. Swathi², Dr. Rajaram Naik³

¹(Post graduate student, Department of conservative dentistry and endodontics, A.J Institute of dental sciences, Mangalore, Karnataka, India)

²(Reader, Department of conservative dentistry and endodontics, A.J Institute of dental sciences, Mangalore, Karnataka, India)

³(Professor and HOD, Department of conservative dentistry and endodontics, A.J Institute of dental sciences, Mangalore, Karnataka, India)

Corresponding author: Dr. Saima Jamal

Abstract: SealBio is a novel and innovative endodontic treatment protocol based on the regenerative concept for the treatment of pulpal and periapical involved mature teeth. The basis for success of an endodontic treatment is to remove all the causative debris, bacteria and their by products. Experiments in the past have shown that there was no difference in the healing of apical periodontitis with or without obturation if the root canals were thoroughly cleaned and debrided. This article reports and discusses the treatment of a non vital mature tooth by this novel approach to achieve an apical seal with biological tissues rather than plugging the canal space with root canal obturating materials. Apical clearing, apical foramen widening and overinstrumentation into periapical region were done to induce bleeding near apical foramen. The clot formed at the apex provides a scaffold into which locally residing stem cells gets seeded and the healing process initiate. A seven month follow up reveals that the novel treatment protocol was found to be favourable in resolving periapical infection, both clinically and radiographically. SealBio was found to be a successful non-obturation endodontic treatment which highlights the importance of cleaning and shaping and possibility of healing after non-surgical endodontic therapy.

Keywords: Biological obturation technique, non-obturation root canal treatment, periapical healing, regenerative endodontic treatment, SealBio.

Date of Submission: 23-11-2017

Date of acceptance: 02-12-2017

I. Introduction

Seal bio is a non- obturation “regeneration- based” treatment which was first conceived and developed in 2009 by Nassem shah. This treatment was initiated to evaluate if “biological obturation” can be achieved in a fully mature teeth after the over-instrumentation to induce bleeding in the apical third and formation of clot, instead of using artificial materials such as gutta percha and sealer cement. This novel regeneration-based, nonobturation endodontic treatment protocol “SealBio” was reported in 2012. [1] One of the essential requirement for successful endodontic treatment is achieving sealing of root canal system at both; apical and coronal end of a disinfected root canal. Even with the conventional guttapercha obturation, the ultimate aim is to achieve a cemental/ fibrous barrier at the root apex. Therefore, for achieving a biological seal, “SealBio” should be preferable over an artificial barrier of gutta percha and sealer at the apical end of the root canal. [2]

Interest in “regenerative endodontics” has revived since 2001 when Iwaya et al. introduced “revascularization” as a treatment modality for immature, non-vital teeth. [3] With the success achieved with revascularization technique in the healing of periapical lesions and the deposition of hard tissue at apical and lateral walls of the root canals in immature teeth, [4] the processes involved with the healing mechanism are now better understood. Role of the various stem cells, growth factors, Hertwig’s epithelial root sheath and their interactions in regeneration of tissues have been documented previously. [5] Using this mechanism of stimulating the healing and regeneration of tissues and combining it with thorough cleaning and shaping of the root canal system, a novel treatment approach was conceived to manage non-surgically non-vital mature teeth with periapical pathology. This article is a case report on the treatment of a mature non-vital tooth by a novel, non-obturation endodontic treatment based on the concept of regeneration called SealBio.

II. Case Report

A 21 year old male patient reported to the department of conservative dentistry and endodontics at A.J institute of dental sciences, Mangalore with the chief complaint of pain in lower left back tooth region since two weeks. The pain was short and intermittent which aggravated while having food. The clinical examination revealed a previously initiated root canal treated teeth in relation to 36 (figure 1A). The tooth was also tender on

percussion. A routine intraoral periapical radiograph revealed large periapical radiolucency in relation to 36 (figure 1B). A large periapical radiolucency was also seen in relation to 35 (figure 1B). This led to the clinical examination in relation to tooth #35. The tooth had no caries, showed no pocket depth, no mobility or evident sinus tract. The tooth was not tender to percussion. The patient was also asymptomatic with respect to 35. However, the vitality test showed the tooth as non-vital. Based on the symptoms and the radiographic findings the diagnosis in relation to 35 was made as periapical granuloma. The treatment plan options that we had for tooth #35 were to either do a conventional root canal treatment or SealBio. As SealBio is a novel treatment plan this method was chosen and informed consent from the patient was taken.

Access opening was done in relation to 35 and the working length was determined (figure 1C). Cleaning and shaping of root canal was done by step back technique. The canal was copiously irrigated with 2.5% sodium hypochlorite. The canal was enlarged 3 sizes larger than the initial apical file size to obtain a master apical file. Apical patency was maintained throughout the cleaning and shaping procedure. A two inter-appointment dressing of triple antibiotic paste of metrogyl, ciprofloxacin and clindamycin was given.

In the next visit, enlargement of the apical-third was done with 2-4 file sizes larger than the master apical file (MAF) at working length with the removal of loose debris from the apical region (Apical clearing). Subsequent to this "apical foramen widening" was done with larger K-files used sequentially till size 25-30 to clean the cemental part of the canals. When the infection control was achieved, as evident from a clinically symptom-free tooth, a final wash with betadine was done and the canals were dried. After checking the patency, determined by smooth passage of # 15 file, intentional over-instrumentation into periapical region was done with #20 K-file to induce bleeding near the apical foramen. This was confirmed by placing a paper point in the canal which was wet with blood in its apical third.

Cavit (3M) was then introduced in the access cavity and with a hand plugger, condensed into the cervical third of root canals. This was followed by GIC restoration (GC) and then later also with composite (3M). Immediate post treatment radiograph was taken (Figure 1D). The patient was recalled for follow up at one month in which the decrease in the size of periapical radiolucency was evident in relation to 35 (Figure 2A). The patient failed to turn up for further appointments for the completion of root canal treatment in 36. The patient then turned up for a seven month follow up which revealed complete resolution of the periapical radiolucency and the healing was evident (Figure 2B). Meanwhile the patient had got the extraction of 36 done against our advice.

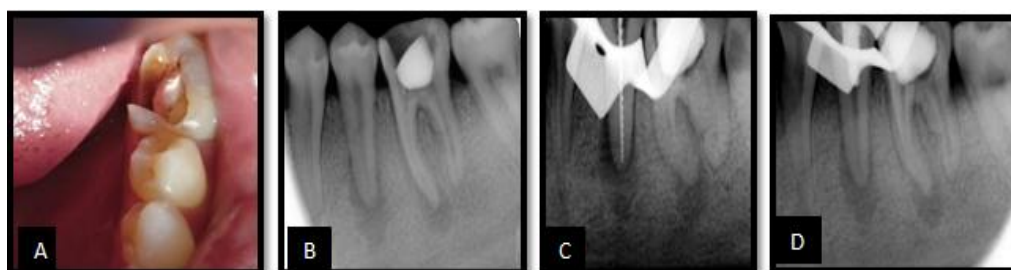

Figure 1: A: Pre- operative intraoral photograph. B: Routine intraoral periapical radiograph showed large periapical radiolucency in 35 and 36. C: Working length determination in 35. D: Immediate post treatment radiograph.

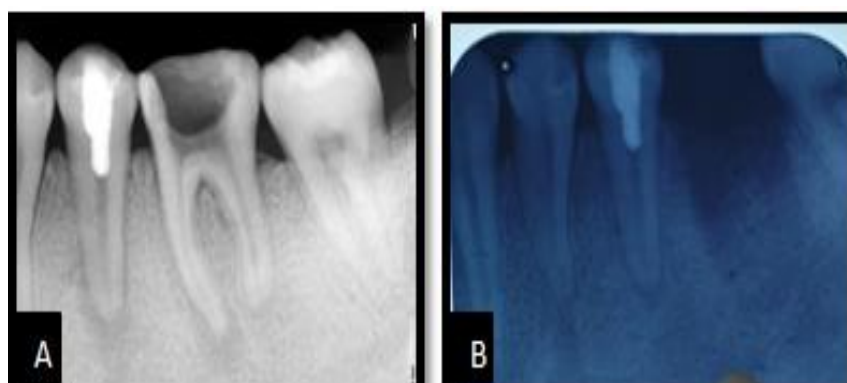


Figure 2: A: One month follow up radiograph which showed decrease in the size of periapical radiolucency B: Seven month follow up radiograph showing complete resolution of the periapical radiolucency

III. Discussion

After the complete debridement and disinfection of root canal system, the peri-radicular lesion had healed even without the obturation of root canal. In 1976 Dubrow had suggested that if canals were thoroughly debrided, healing of periapical tissues would occur and tissue fluid may not enter the canal space, even if it was not obturated.^[6] Dass commenting on the use of calcium hydroxide for apexification had stated that “perhaps filling is unessential and mere eradication of infection may be sufficient for apexification.”^[7] Role of thorough root canal debridement and disinfection in periapical healing with incomplete obturation of root canals has been reported. In an experimental animal study in 2006 on dog’s teeth reported that there was no difference in healing of apical periodontitis with and without obturation, if the root canals were thoroughly instrumented and debrided.^[8] Rickert and Dixon gave a theory based on the observation on experimental animals that when hollow plastic tubes were implanted then inflammation was seen at both the open ends of the tube. The in and out movement of the fluid evoked the inflammation. Therefore, to prevent it both the ends of the tube should be sealed and hence the root canal obturation was considered mandatory.^[9] However, Goldman and Pearson refuted the hollow tube theory. Their results showed no inflammation at the open ends of the implanted tubes when they were sterile and clean.^[10]

In 1953 Grossman had stated that an optimum concentration of necrotic debris was necessary to increase or sustain periapical inflammation. Body’s defense mechanism can take care of residual infection.^[11] Also based on animal studies it has been concluded that sterile necrotic pulp tissue and stagnant tissue fluid do not sustain inflammation at the periapex. Sabeti et al. had documented that there was no difference in periapical healing in teeth with and without obturation following complete disinfection, if the coronal seal of the sterile canal was maintained.^[12]

In sealbio procedure, heavy stress is laid on the thorough disinfection of the root canal space and developing a tight coronal seal. Special care was taken to clean and disinfect the apical third of the canal space. “Apical clearing” and “apical foramen widening” are intended to maximize the debridement and it also results in reduced number of apical ramifications and the presence of bacterial load in the apical third.^[13] It was followed by overinstrumentation into periapical region to induce bleeding near apical foramen. It is hypothesized that the clot formed provides a scaffold into which locally residing stem cells can get seeded and the cascade of healing process can initiate. “Apical clearing” is a technique which helps in removing the loose debris from the apical third, the deltas and accessory canals, which are the area where bacteria hide and escape disinfection process by enlarging the apical canal with instruments 2-4 sizes larger than master apical file. “Apical foramen widening” allowed thorough cleaning of cemental part of canal as well ensure smooth passage of instrument for the overinstrumentation to be performed.

Intentional over-instrumentation past the apical foramen into the periapical tissues contributes towards healing of the lesion as well as towards achieving a biological barrier of hard and soft tissues as seen in cases of revascularization of immature teeth. This method of over-instrumentation was found very effective in non-surgical management of periapical lesions in a prospective clinical study in 1988.^[14]

The healing of periapical radiolucency is seen as a result of the body’s response to the disinfected root canal space and the decreased bacterial burden. Ostby had demonstrated that the healing response with the deposition of cellular cementum and fibrous connective tissue in the apical third of the root canal had better resistance to infection and has more advantage over inert root filling materials.^[15] In the periapical region, the periodontal ligament (PDL) stem cells, PDL progenitor cells (PDLPs), stem cells from the apical papilla, and bone marrow mesenchymal stem cells are commonly present,^[16] which can be recruited by over-instrumentation beyond the apical foramen into the scaffold provided by the blood clot, at the apex of the root.

Organization of blood clot results in the release of various growth factors, which regulate multiple events involved in the wound healing such as chemotaxis, cell adhesion, proliferation, and differentiation.^[17] Of the many growth factors, platelet-derived growth factor, vascular endothelial growth factor, transforming growth factor α and β , fibroblast growth factor, and bone morphogenetic proteins 2, 3, and 7 are important for regeneration of apical tissues. The stem cells then differentiate into various forming cells such as fibroblast, cementoblasts, and osteoblasts which lay down fibrous/mineralized tissue over the apex; hence, the term “SealBio” - sealing with biological tissues.^[18]

The role of CBCT in evaluation of periapical healing has been reported in the study done previously on Sealbio. It provides an objective and non-invasive method to measure the periapical healing and mineralized tissue deposition. CBCT evaluation of the treated teeth shows increased density of bone and cementum which proves that mineralized barrier following this novel technique does take place. CBCT in this case could not be done as the patient was not co-operative. The importance of a tight coronal seal cannot be overemphasized. Without a coronal seal, the bacteria and their by-products can reach the apex through an obturated canal in just 20 days. Cavit, a zinc-sulphate based material is chosen here to seal the canal orifices. It served two purposes: (i) calcium sulphate cement have very good sealing properties (ii) in failed cases if retreatment was required, it would be easier to remove it from canal orifices.

The advantages of seal bio are: (i) posts can be easily used in cases treated by SealBio, as the canals are left empty and only an apical barrier is expected to form at the apical end, unlike in cases of revascularization, where the canal is filled with vital tissues. (ii) Better healing response was observed, even in cases of large cyst-like lesions. (iii) In case where retreatment is required, it is easy to re-enter, as the canal is empty unlike removal of all the obturating materials, as required in conventional endodontic treatment.^[18]

IV. Conclusion

The new technique, as discussed and documented in this case report can prove to be the most simple, easy to perform and cost-effective method of regenerative based endodontic treatment. The result proves the importance of thorough cleaning and shaping and a well-condensed, bacteria-tight coronal seal in endodontic treatment success.

References

- [1]. Shah N, Logani A. SealBio: A novel, nonobturation endodontic treatment based on concept of regeneration. *J Conserv Dent* 2012;15:328-32.
- [2]. Voinovich O, Voinovich J. Periodontal cell migration into the apical pulp during the repair process after pulpectomy in immature teeth: An auto radiographic study. *J Oral Rehabil* 1993;20:637-52.
- [3]. Iwaya SI, Ikawa M, Kubota M. Revascularization of an immature permanent tooth with apical periodontitis and sinus tract. *Dent Traumatol* 2001;17:185-7.
- [4]. Shah N, Logani A, Bhasker U, Aggarwal V. Revascularization for inducing apexogenesis/apexification in non-vital, immature permanent incisors: A pilot study. *J Endod* 2007;34:919-25.
- [5]. Matusow RJ. Acute pulpal-alveolar cellulitis syndrome V. Apical closure of immature teeth by infection control: Case report and a possible microbial-immunologic etiology. Part 1. *Oral Surg Oral Med Oral Pathol* 1991;71:737-42.
- [6]. Dubrow H. Silver points and guttapercha and the role of root canal fillings. *J Am Dent Assoc* 1976;93:976-80.
- [7]. Das S. Apexification in a non-vital tooth by control of infection. *J Am Dent Assoc* 1980;100:880-1.
- [8]. Sabeti MA, Nekofar M, Motabary P, Ghandi M, Simon JH. Healing of apical periodontitis after endodontic treatment with and without obturation in dogs. *J Endod* 2006;32:628-33.
- [9]. Rickert UG, Dixon CM. The Controlling of Root Surgery. 8th International Dental Congress Section 111; 1931. p. 15-22.
- [10]. Goldman M, Pearson AH. A preliminary investigation of the "Hollow tube" theory in endodontics: Studies with neo-tetrazolium. *J Oral Ther Pharmacol* 1965;1:618-26.
- [11]. Grossman LI. Antibiotics vs. instrumentation. A reply. *N Y State Dent J* 1953;19:409.
- [12]. Sabeti MA, Nekofar M, Motahary P, Ghandi M, Simon JH. Healing of apical periodontitis after endodontic treatment with and without obturation in dogs. *J Endod* 2006;32:628-33.
- [13]. Borlina SC, de Souza V, Holland R, Murata SS, Gomes-Filho JE, Dezan Junior E, *et al.* Influence of apical foramen widening and sealer on the healing of chronic periapical lesions induced in dogs' teeth. *Oral Surg Oral Med Oral Pathol Oral Radiol Endod* 2010;109:932-40.
- [14]. Shah N. Non-Surgical management of periapical lesions: A prospective Study. *Oral Surg Oral Med Oral Pathol* 1988;66:3665-371.
- [15]. Ostby BN. The role of the blood clot in endodontic therapy. An experimental histologic study. *Acta Odontol Scand* 1961;19:324-53.
- [16]. Huang GT, Sonoyama W, Liu Y, Liu H, Wang S, Shi S. The hidden treasure in apical papilla: The potential role in pulp/dentin regeneration and bioroot engineering. *J Endod* 2008;34:645-51.
- [17]. Csaki C, Matis U, Mobasheri A, Ye H, Shakibaei M. Chondrogenesis, osteogenesis and adipogenesis of canine mesenchymal stem cells: A biochemical, morphological and ultrastructural study. *Histochem Cell Biol* 2007;128:507-20.
- [18]. Shah N. A regeneration-based, nonobturation root-canal treatment for fully-mature teeth: Six years' experience with "SealBio". *Contemp Clin Dent* 2016;7:296-301.

*Dr. Saima Jamal. "Sealbio: A Novel, Non-Obturation Endodontic Treatment." *IOSR Journal of Dental and Medical Sciences (IOSR-JDMS)*, vol. 16, no. 11, 2017, pp. 42–45.