

Bilateral serous retinal detachment in HELLP syndrome: A case report

*Chelsia Nongtdu¹, Sagarika Majumder¹, Renjano N Okhyopvui¹, Thangjam Amit Singh¹, Insha Aftab¹, C.Lalduhkimi¹, Naphibanroi Kharnaor¹, Elivia N Sangma¹

¹Department of Ophthalmology, RIMS Imphal
Corresponding Author: *ChelsiaNongtdu

Abstract: Preeclampsia is an idiopathic obstetric disease affecting almost 5% of pregnant women with variable visual disability, being retinal detachment a rare complication. This is a case report of 29 years old primigravida with eclampsia and HELLP syndrome (Hypertension, elevated liver enzymes and low platelets) presented with bilateral serous retinal detachment in the puerperium stage in the absence of preexisting hypertensive retinopathy. Under conservative management, bilateral retinal detachment resolved subsequently with good visual improvement. This case showed good clinical outcome of serous retinal detachment in eclampsia with HELLP syndrome clinically managed.

Keywords: Preeclampsia, eclampsia, HELLP syndrome, serous retinal detachment(SRD)

Date of Submission: 30 -10-2017

Date of acceptance: 16-11-2017

I. Case Report

A 29 years old primigravida patient at 31 weeks gestation with eclampsia complained of bilateral blurring of vision since 10 days. Caesarean section for eclampsia on the 6th day was done following the onset of blurring of vision. On postpartum day 2 she developed features consistent of HELLP syndrome for which immediate medical treatment was initiated. She however had no past history of blurring of vision or hypertension. On examination, her visual acuity on postpartum day 3 was 1/60 both eyes. Slit lamp examination of anterior segment was normal. But fundoscopy showed bilateral SRD(Fig 1) with shifting fluid affecting inferotemporal retina. However there were no clinical signs of hypertensive retinopathy changes noted. OCT findings showed elevated inner and outer retinal layers with neurosensory retinal detachment (Fig 2). Spontaneous resorption of subretinal fluid started promptly seven days after delivery with mild mottling of retina secondary to pigment epithelial changes with visual acuity of 4/60 and 6/60. Complete resolution of SRD occurred within 12 weeks of postpartum with good visual acuity. OCT also showed complete regression of SRD(Fig 3).

II. Discussion

Bilateral exudative retinal detachment is associated with HELLP syndrome.¹ Retinal detachment is seven times more common in women with preeclampsia/eclampsia with HELLP syndrome than those without HELLP syndrome.² SRD may be unilateral or bilateral and may appear before birth or after postpartum period.^{3,4} Our case showed bilateral SRD which appeared in postpartum period. Many theories were being proposed for the mechanism of SRD development. One theory is that SRD results from choroidal ischaemia; another is that, it develops due to sub retinal fluid accumulation, secondary to increase vascular permeability.⁵ A study of ocular findings in HELLP syndrome patients reported hypertensive changes in 16%, SRD in 37%.⁶ Whereas our patient was having bilateral SRD with no hypertensive changes. The majority of patients who manifested SRD during pregnancy have with clinical management, complete recovery within weeks after delivery, not needing any surgical intervention.⁷⁻¹¹ Similarly, our case showed complete resorption of SRD 12 weeks after delivery with no surgical intervention required. Visual symptoms in patients of preeclampsia with HELLP syndrome should definitely be regarded as serious and the patients should be referred timely to an ophthalmologist. This will help to reverse any ocular manifestation and thereby avoid long term sequelae.

References

- [1]. Schonfeld CL. Bilateral exudative retinal detachment in HELLP syndrome. Case Rep Ophthalmol 2012 Jan;3(1):35-7.
- [2]. Vigil-De Gracia P, Ortega-Paz L. Retinal detachment in association with preeclampsia, eclampsia and HELLP syndrome. Int J Gynecol Obstet 2011;114:223-5.
- [3]. Sibai BM, Ramadan MK, Usta I, Salama M, Mercer BM, Friedman SA. Maternal morbidity and mortality in 442 pregnancies with haemolysis, elevated liver enzymes, and low platelets (HELLP syndrome). Am J Obstet Gynecol 1993;169:1000-6.

- [4]. Gundlach E, Junker B, Gross N, Hansen LL, Pielen A. Bilateral serous retinal detachment. *Br J Ophthalmol* 2013;97:939-940.
- [5]. Celik G, Eser A, Gunay M, Yenerel NM. Bilateral vision loss after delivery in two cases: severe preeclampsia and HELLP syndrome. *Turk J Ophthalmol* 2015 Dec;45(6):271-3.
- [6]. Erbagci I, KaracazM, Ugur MG, Okumus S, Bekir NA. Ophthalmic manifestations of 107 cases with hemolysis, elevated liver enzymes and low platelet count syndrome. *Saudi Med J* 2008;29:1160-3.
- [7]. Aburymra S. Doençaretinianas da gravidez. In: *Retina e Vítreo. Clínica e Cirurgia. Sociedade Brasileira de Retina e Vítreo e Conselho Brasileiro de Oftalmologia* (Ed). São Paulo: Editora Roca 2000;584-5.
- [8]. Kahhale S, Zugaib M. Síndromes Hipertensivas na Gravidez (Ed). São Paulo: Atheneu 1995;107-21.
- [9]. Lee C, Hsu TY, Ou CY, Chang SY, Soong YK. Retinal detachment in postpartum preeclampsia and eclampsia: report of two cases. *Chang Geng I Hsueh TsaChih* 1999;3:520-4.
- [10]. Netto JA. Fundo de olho. In: Lopes M, Laurentys-Medeiros J (ed). *Semiologia Médica As Bases do Diagnóstico Clínico*. Rio de Janeiro: Revinter 2001;249-65.
- [11]. Bos AM, Van Loon AJ, Ameln JG. Serous retinal detachment in preeclampsia. *Ned Tijdschr Geneesk* 1999;143:2430-2.

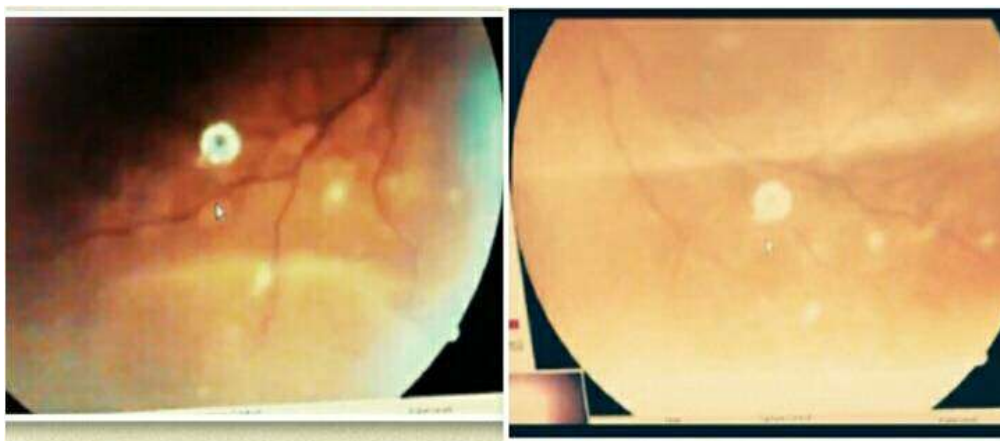


Fig 1: Fundus picture of right and left eye on postpartum Day-3

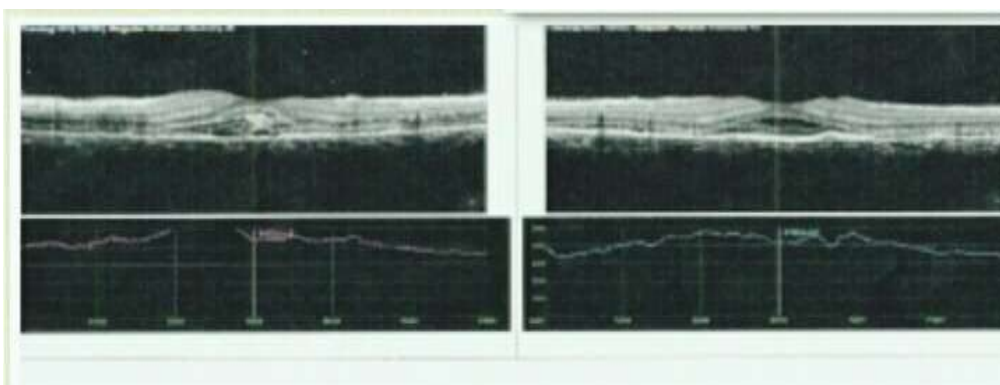


Fig 2: OCT on postpartum Day-3

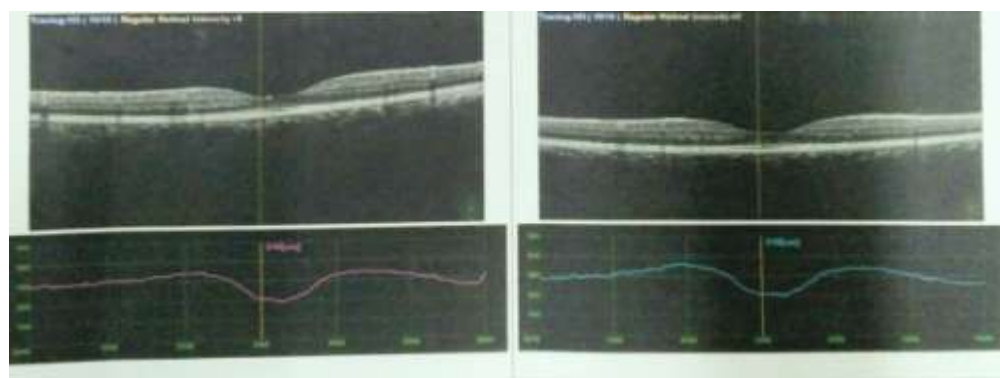


Fig 3: OCT showing complete resolution of SRD

*Chelsia Nongtdu. "Bilateral Serous Retinal Detachment in HELLP Syndrome: A Case Report." *IOSR Journal of Dental and Medical Sciences (IOSR-JDMS)* 16.11 (2017): 28-29