

## Submandibular Swelling: Tubercular or Malignant??

Dr Vaibhav Krishna<sup>1</sup>, Dr Sachin Jain<sup>2</sup>, Dr Alok Chandra<sup>3</sup>

<sup>1</sup>Senior Resident, <sup>2,3</sup>Associate Professor

<sup>1,2</sup>Department of Pulmonary Medicine, Motilal Nehru Medical College, Allahabad (Uttar Pradesh)

<sup>3</sup>Department of ENT, Motilal Nehru Medical College, Allahabad (Uttar Pradesh)

Correspondence Author: Dr Sachin Jain, Associate professor, Department of ENT, MOTILAL NEHRU MEDICAL COLLEGE, ALLAHABAD

**Abstract:** It is a cause of concern for the patient and physician alike even in the absence of symptoms. In India and some other developing countries, tuberculosis (TB) is the first differential diagnosis for a patient who presents with chronic lymph node enlargement. Nonetheless, studies have shown that more than 50% of cases of lymphadenopathy are due to non-TB causes and, in these cases, excision biopsy (EB) with histopathology and/or microbiological examination, is the only way to exclude TB. Malignancies may account for about 1% of cases of Lymphadenopathy. 40yr female presenting to respiratory medicine OPD in Motilal Nehru Medical College, Allahabad with complaints of right sided submandibular swelling since 1.5 yrs with fever with evening rise and weight loss. Montoux test was done which was positive. FNAC of the swelling showed granulomatous lesion suggestive of tubercular nature. Chest X-ray was normal. Sputum for AFB was negative. Patient was discharged on Anti-tubercular regimen. Patient didn't come on due dates of follow-up. After 5 months patient came with no improvement and LN was hard and tender. Then further evaluation was done. CT face and neck revealed neoplastic lesion in Rt submandibular gland. FNAC showed benign epithelial cells within fibro vascular stroma. Further Excisional biopsy was performed and revealed Muco-epidermoid carcinoma of parotid gland.

**Keywords:** Tuberculosis, Lymph node, Submandibular, Muco-epidermoid

Date of Submission: 04-10-2017

Date of acceptance: 16-11-2017

### I. Introduction

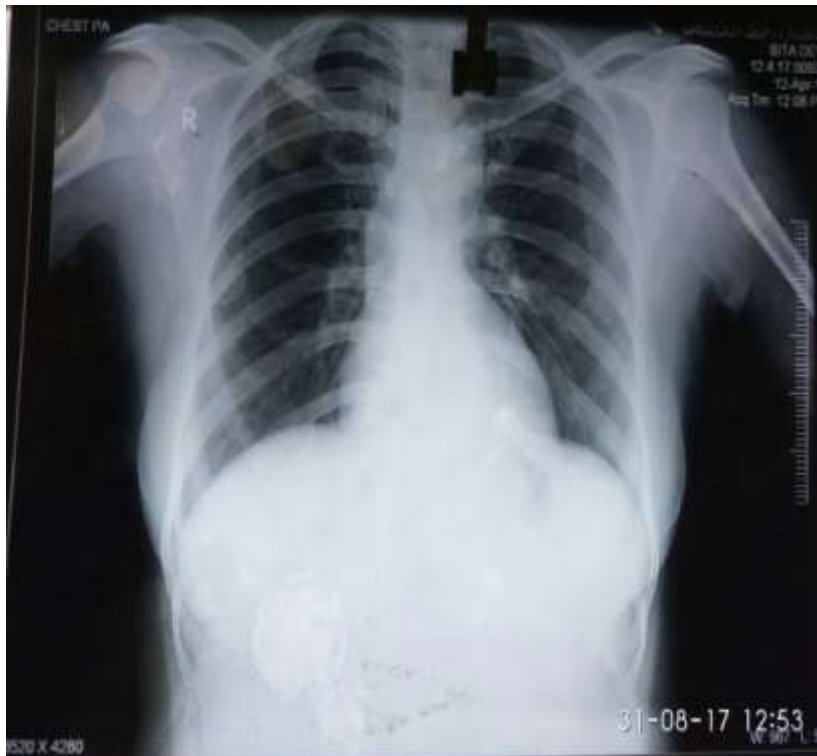Pleomorphic adenoma (PA), also known as benign mixed tumour, is the most common salivary tumour, constituting up to 2/3<sup>rd</sup> of all salivary gland neoplasms<sup>1</sup>. Mostly, PA is located in the parotid glands (85%), minor salivary glands (10%), and the submandibular glands (5%)<sup>2</sup>. Superficial lobe is most common site for this type of tumour. However, occasional cases may involve the deep lobe of the parotid gland<sup>3</sup> and the Para pharyngeal space. Minor salivary gland tumours are frequently encountered on the palate, followed by the lip, cheek, tongue and floor of the mouth<sup>4</sup>. PA usually manifest as a slow progressing asymptomatic, parotid gland swelling without facial nerve involvement<sup>5</sup>. They are best treated by a wide local excision with good safety margins and follow-up for at least 3–4 years<sup>6</sup>.

### II. Case Report

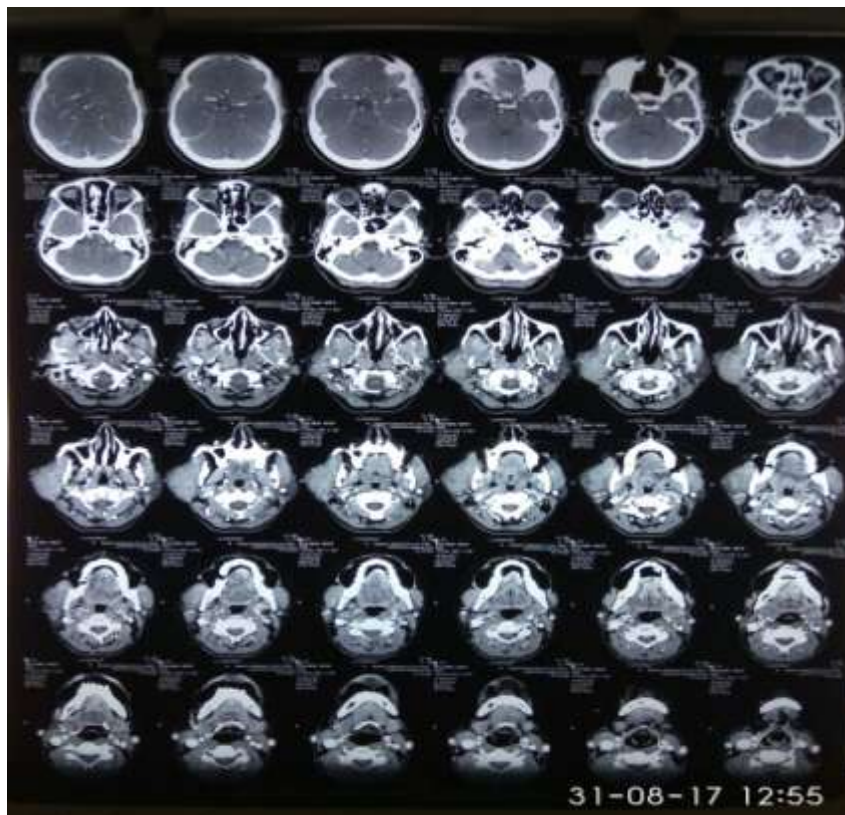
40 yrs female from Allahabad came to OPD of Motilal Nehru Medical College, Allahabad with complains of right submandibular swelling since 1.5 yrs. Swelling was 3.5x 3 cm in size, soft, non-tender, mobile. Patient also had complaint of fever with evening rise, loss of appetite. Breathlessness was also associated complaint which was MMRC grade II. There was no history of difficulty in swallowing, throat pain or any other features of obstruction of airways. Tuberculosis is most prevalent in developing countries like India hence, tuberculosis lymphadenopathy was considered as first differential diagnosis. Montoux Test was done which was positive for tubercular. FNAC was done which revealed tubercular in nature. Chest X-Ray didn't show any significant lesion and sputum for AFB was negative. PFT was done and features were obstructive leading to the diagnosis of Bronchial Asthma. Patient was started on anti-tubercular regimen according to government programme (RNTCP) along with treatment for Asthma and was advised regular follow-up which was not done. The patient turned up after 5 months with symptoms of increase in size of swelling which was painful, immobile, difficulty in opening mouth. Overlying skin was shiny and tense.

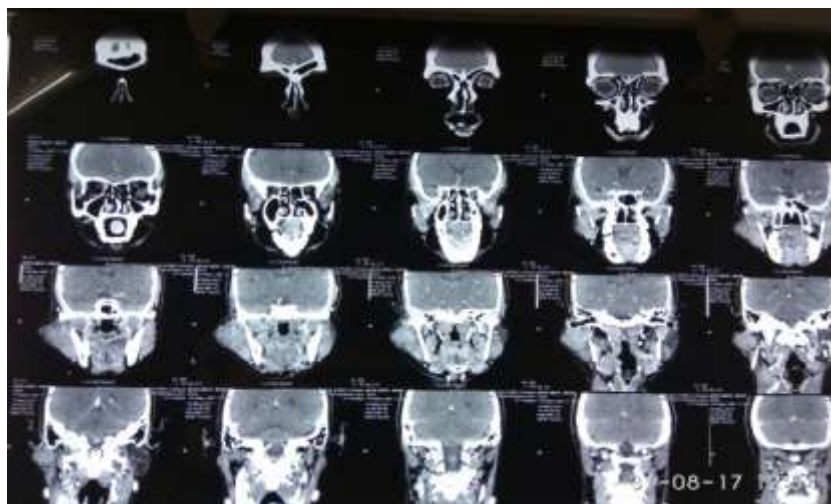
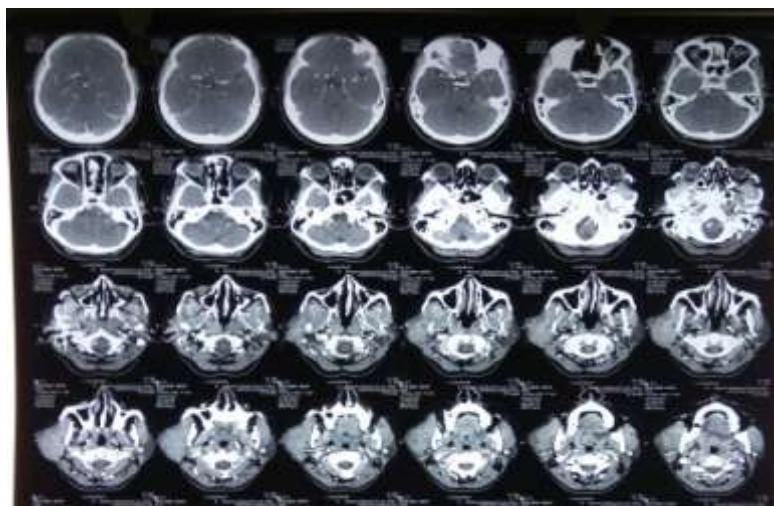
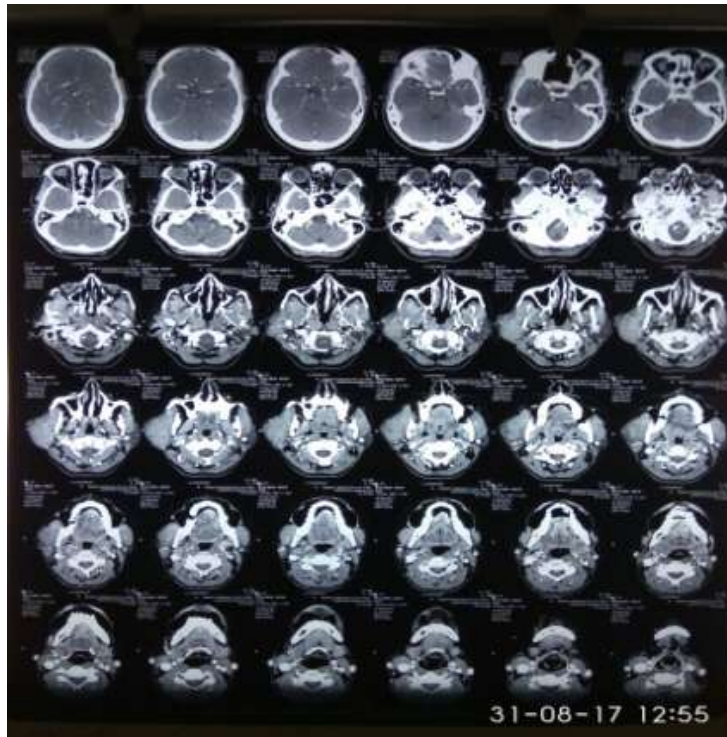
Patient was further evaluated to rule out other possible cause of lymphadenopathy. 128 slice CT face and neck was done which revealed involvement of superficial lobe of the parotid gland, likely benign lesion of size 67X39 mm extending anteriorly posterior border of masseter muscle and also abutting the posterior border of sternocleidomastoid muscle suggesting Pleomorphic Adenoma. Patient was subjected to FNAC which revealed epithelial cells, myoepithelial cells forming chondromyxoid background confirming Pleomorphic Adenoma.

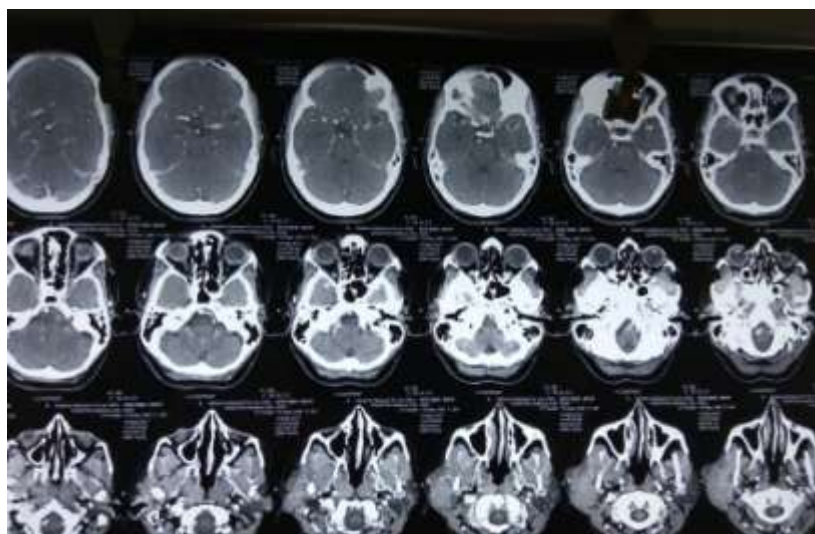
Further confirmation was done by excisional biopsy. Other blood parameters didn't show any significant abnormality. Further patient was managed with combined approach with ENT Surgeons.



**CHEST X-RAY PA VIEW**







### III. Discussion

Pleomorphic adenoma can be defined according to World Health Organization (1972) as a well-defined tumour characterized by its pleomorphic or mixed appearance. There is intermixing of the epithelial component with myxoid, mucoid, and chondroid component <sup>7</sup>

In spite of several histological features due to different tissue elements and cellular components, it is generally considered to be a benign neoplasm. <sup>8,9</sup>

Pleomorphic adenoma is known to be the most common salivary gland neoplasm. It occurs most commonly in the parotid gland. <sup>10,11,12</sup>

Spence reported the first case of giant pleomorphic adenoma published in the English language literature, who described the treatment of a mixed tumour > 1 kg. In 1956, Short and Pullar <sup>13</sup> published an English language review of huge pleomorphic adenomas and a case-report of an adenoma of 2.3kg.

In 1989, Schultz-Coulon <sup>14</sup> reviewed 31 cases of massive pleomorphic adenomas of the parotid gland and found a female preponderance (64.5%), with an age range from 20 to 40 years old, and a tumour weight between 1 to 27 kg.

Buening described the 10 largest pleomorphic adenomas published in the medical literature. The author found a mean tumour weight of 7.8 kg; 9 out of 10 occurred in females, with a mean age of 56 years. The author reported 5th largest pleomorphic adenoma (6.85 kg). In our case the patient was a female of 78 years with a history of 10 years and tumour weight 3.1 kg which agrees with the literature reviews. The incidence of malignant transformation in adenomas ranges from 1.9% to 23.3% <sup>15</sup>. The risk of malignancy increases with longer duration, post-operative recurrence, elderly age group and location in a major salivary gland <sup>16</sup>.

Some authors postulated that the risk of malignant transformation increases from 1.6% in tumours with less than 5 years of evolution, to 9.5% for those presenting for more than 15 years <sup>17</sup>. The classical history of carcinoma ex-pleomorphic adenoma is a slowly-growing mass for many years, with a recent rapid growth phase. This typical history of a case of a giant adenoma with malignant transformation was reported in 2005 by Honda <sup>18</sup> in a 72-year-old female with a long history for 20 years, and a rapid increase in the last 3 months.

Giant Pleomorphic Adenoma of the Parotid Gland: A Rare Case Report and Literature Review DOI: 10.9790/0853-1510068791 www.iosrjournals.org 90 | Page In the review literature of Schultz-Coulon <sup>14</sup>, 3 of 31 cases of giant adenomas showed malignant transformation. In our case, although the patient presented all the characteristics for an increased risk of malignancy, clinically and histologically there was no such evidence. <sup>19</sup>

Two main metastatic variant, carcinoma ex pleomorphic adenoma and metastasizing benign mixed tumours are observed. <sup>19</sup> Macroscopically the tumour show mainly irregular, multinodular lesion with bosselated surface with the complete or incomplete capsule like structure. The surface remain firm in consistency and the softness in nodule suggesting cystic degeneration of the lesion. <sup>20</sup> The radiological findings are essential in diagnosis of pleomorphic adenoma. Mostly the benign tumours shows a hyper dense image on the C.T. scan of the lesion. <sup>21</sup>

In two recent cases of giant PA reported in the English literature, the resection of the tumours were performed with preservation of the facial nerve. <sup>22</sup> Our case was treated by total conservative parotidectomy because of the tumours size, with excellent aesthetic and functional results. Because of the presence of

incomplete and thin capsule, the tumour buds like pseudopods may extend beyond the capsule and is responsible for the high recurrence.<sup>23</sup>

A recurrence rate of up to 40% was noticed in treated cases of pleomorphic adenoma.<sup>24</sup>

#### IV. Conclusion

Pleomorphic adenomas need early diagnosis and diligent management as they have a tendency for recurrence and malignant transformation. Up to 10% cases show malignant transformation. Rupture of the capsule and subsequent tumour spillage during excision are attributable risk factors for recurrence. Features predictive of malignant change include advancing age, massive tumour size, a long duration of the mass, occurrence in submandibular salivary gland, and hyalinised connective tissue.

#### References

- [1] Califano J, Eisele DW. Benign salivary gland neoplasms. *Otolaryngol Clin North Am.* 1999;32:861–873. [PubMed]
- [2] Luna MA. Salivary glands. In: Pilch BZ, editor. *Head and neck surgical pathology.* Philadelphia: Lippincott Williams & Wilkins; 2001. pp. 284–349.
- [3] Morita N, Miyata K, Sakamoto T, Wada T. Pleomorphic adenoma in the parapharyngeal space: report of three cases. *J Oral Maxillofac Surg.* 1995;53:605–610. [PubMed]
- [4] Vicente OP, Marques NA, Aytes LB, Escoda CG. Minor salivary gland tumors: a clinicopathological study of 18 cases. *Med Oral Patol Oral Cir Bucal.* 2008;13(9):582–588. [PubMed]
- [5] Sergi B, Limongelli A, Scarano E, Fetoni AR, Paludetti G. Giant deep lobe parotid gland pleomorphic adenoma involving the parapharyngeal space. Report of three cases and review of the diagnostic and therapeutic approaches. *Acta Otorhinolaryngol Ital.* 2008;28:261–265. [PMC free article] [PubMed]
- [6] Aggarwal A, Singh R, Sheikh S, Pallagatti S, Singla I. Pleomorphic adenoma of minor salivary gland: A case report. *RSBO Revista Sul-Brasileira de Odontologia.* 2012;9:97–101.
- [7] Traiger J, Rosen MB. Mixed tumor of the cheek; report of a case. *Oral Surg Oral Med Oral Pathol.* 1965;19:711–714. [PubMed]
- [8] Berdal P, Hall JG. Parapharyngeal growth of parotid tumours. *Acta Otolaryngol Suppl.* 1969;263:164–166. [PubMed]
- [9] Carr RJ, Bowerman JE. A review of tumors of the deep lobe of the parotid salivary gland. *Br J Oral Maxillofac Surg.* 1986;24:155–168. [PubMed]
- [10] Silva SJ, Costa GT, Filho ACB, Faria PR, Loyola AM. Metachronous bilateral pleomorphic adenoma of the parotid gland. *Oral surgery, Oral Medicine, Oral Pathology, Oral Radiology, and Endodontology.* 2006; 101:333–338
- [11] Jr Takahama A, Perez DEC, Magrin J, Almeida OP, Kowalski LP. Giant pleomorphic adenoma of the parotid gland. *Med Oral Patol Oral Cir Bucal* 2008; 13: E 58–60
- [12] Shashinder S, Tang IP, Velayutham P, Prepageran N, Gopala KG, Kuljit S et al. A review of parotid tumours and their management: A ten-year- experience. *Med J Malaysia* 2009; 64 : 31–33
- [13] Spence J. Case of enormous deep-seated tumour of the face and neck, successfully removed by operation plates. *The Dublin Journal of Medical Science.* 1863;36:272–283. Giant Pleomorphic Adenoma of the Parotid Gland : A Rare Case Report And Literature Review DOI: 10.9790/0853-1510068791 www.iosrjournals.org 91 | Page
- [14] Schultz-Coulon HJ. Pleomorphic giant adenomas of the parotid gland. *Laryngorhinootologie.* 1989;68:445–449. [PubMed]
- [15] Auclair PL, Ellis GL. Atypical features in salivary gland mixed tumors: their relationship to malignant transformation. *Mod Pathol.* 1996;9:652–657.
- [16] Yamamoto Y. Clinical signs and histology of carcinoma in pleomorphic adenoma. *Otologia.* 1994;87:1320–1324.
- [17] Eneroth CM, Zetterberg A. Malignancy in pleomorphic adenoma. A clinical and microspectrophotometric study. *Acta Otolaryngol.* 1974;77:426–432. [PubMed]
- [18] Luna MA. Salivary glands. In: Pilch BZ, editor. *Head and neck surgical pathology.* Philadelphia: Lippincott Williams & Wilkins; 2001. pp. 284–349
- [19] Ellis GL, Auclair PL. Pleomorphic adenoma. In: Ellis GL, Auclair PL. *Tumors of the Salivary Glands (Atlas of Tumor Pathology).* Facicle 17. Washington, DC: Armed Forces Institute of Pathology; 1996:39–57
- [20] Sunil S, Gopakumar D. Pleomorphic Adenoma: A Case Report and Review of Literature. *Int J Odontostomat.* 2013;7:171–174
- [21] Brunese L, Ciccarelli R, Fucili S, Romeo A, Napolitano G, D'Auria V, et al. Pleomorphic adenoma of parotid gland: delayed enhancement on computed tomography. *Dentomaxillofac Radiol.* 2008; 37:464–9. [28]. Laskawi R, Schott T, Mirzaie-Petri M, Schroeder M. Surgical management of pleomorphic adenomas of the parotid gland: a followup study of three methods. *J Oral Maxillofac Surg.* 1996 ;54:1176–9.
- [22] Honda T, Yamamoto Y, Isago T, et al. Giant pleomorphic adenoma of the parotid gland with malignant transformation. *Ann Plast Surg.* 2005;55:524–527. [PubMed]
- [23] Snow G. The surgical approaches to the treatment of parotid pleomorphic adenomas. In: McGurk M, Renehan A, eds. *Controversies in the management of salivary gland disease.* Oxford: Oxford University Press; 2001. p. 57–66
- [24] O'Brien CJ. Current management of benign parotid tumours—the role of limited superficial parotidectomy. *Head Neck.* 2003; 25:946–52