

## Functional Outcome of Acromioclavicular Dislocation Treated By Hook Plate

\*Dr. Muthugukan Raja<sup>1</sup>, Asst prof Dr. Senthil Loganathan<sup>2</sup>,  
Prof. Samuel Chittranjan<sup>3</sup>  
Sri Ramachandra University, Porur.  
Corresponding Author: \*Asst prof Dr. Senthil Loganathan

---

### Abstract

**Background:** Internal fixation with hook plate has been used to treat acromioclavicular joint dislocation. This study aims to evaluate the effect of its use on shoulder function, to further analyze the contributing factors, and provide a basis for selection and design of improved internal fixation treatment of the acromioclavicular joint dislocation in the future.

**Methods:** A prospective analysis was performed on patients treated with a hook plate for acromioclavicular joint dislocation in our hospital from January 2014 to February 2016. There were 15 cases in total, including 9 males and 6 females, with mean age of  $48.27 \pm 8.7$  years. There were 10 cases of Rockwood type IV acromioclavicular dislocation, 5 cases of type V.

**Results:** The PENN Score was Excellent in 13 patients, Good in 1 patient and Fair in 1 patient, and in Constant Shoulder Score was excellent in 14 patients and fair in 1 patient. All patient achieved range of movements equal to that of the contralateral side at 5 weeks.

**Discussion:** The use of hook plate on open reduction and internal fixation of the acromioclavicular joint dislocation had little adverse effect on shoulder function and is an effective method for the treatment of acromioclavicular joint dislocation. Osteoarthritis and osteolysis are the two common complications after hook plate use, which are associated with the impairment of shoulder function. Shoulder function will be improved after removal of the hook plate.

---

Date of Submission: 01 -11-2017

Date of acceptance: 16-11-2017

---

### I. Introduction

Acromioclavicular joint injuries are a common entity with an ever-evolving approach towards management of these injuries from the days of Hippocrates [1] and Galen [2]. The quantum of these injuries is on the rise constituting approximately 9–12 % of all shoulder injuries following fall on an outstretched hand [3–6]. The commonly used classification is Rockwood divides these injuries into six types [7]. Rockwood type III injuries remains controversial, Though we still follow conservative management for Rockwood type I and II injuries and surgical treatment for Rockwood type IV, V and VI injuries [8–11]. Various approaches are described ranging from conservative management with bandages and slings to different surgical options including tension band wiring, fixation with washer and screws, the modified Weaver–Dunn procedure and clavicular hook plates. All of these options have their own specific advantages and disadvantages, but no clearly superior option has been established as yet [12]. Clavicular hook plates are anatomically designed pre contoured plates with varying sizes and depths as well as sides. Post reduction of acromioclavicular joint the hook plate is placed under the acromion process posteriorly and the screws are used to fix the plate to lateral clavicle to maintain reduction. As routine plates are removed after 3 months to avoid complications such as acromial osteolysis, subacromial impingement. Rockwood type 3 acromioclavicular dislocation treated with hook plate has raised the concerns about acromial osteolysis, Subacromial impingement and possibly rotator cuff injuries [13–15]. We used this prospective study to establish the efficacy of clavicular hook plate without reconstructing coracoclavicular/acromioclavicular ligaments in high demand patients

### II. Materials And Methods

A prospective analysis was done in SRMC from January 2014 to February 2016. We treated patients with a hook plate for acromioclavicular joint dislocation. We a total of 15 patients, after obtaining informed consent for the study of publication research and photos including [9 males and 6 females], with mean age of  $48.27 \pm 8.7$  years. We classified acromioclavicular joint dislocation with Rockwood. Apart which 10 cases were type IV and 5 cases were under type V

*Functional Outcome of Acromioclavicular Dislocation Treated By Hook Plate*

The inclusion criteria includes Rockwood type III, IV, V, VI. Acromioclavicular joint disruption associated with injury of lateral end of clavicle

The exclusion criteria includes paediatric acromioclavicular disruption , Grade I and II disruption associated with nerve injuries.

All the 15 patients was radiographically evaluated with a standard anteroposterior view and stress views which was classified by the surgeon. These radiographs was compared with non injured shoulder X rays for coracoclavicular distance. All the patients was operated in a supine position under general anaesthesia/ Regional anaesthesia. Robert approach was used to expose the acromioclavicular joint in all patients . Intra-operative needle was used to demarcate the acromioclavicular joint, Intra-operatively we measured the depth of acromium posteriorly till the tip of supraspinatous using depth gage and accordingly we choosed the depth of hook plates . (Fig:1-6).

Post-operatively , arm sling was used for 10 days to 2 weeks. Pendulum exercise was started after 24 hours assisted with active flexion and extension movements following by light resisting exercise after 6 weeks was started and complete full range of movements was started after 12 weeks. Postoperative functional outcome was assessed by using PENN score and Constant Shoulder Score. Assessed at the regular interval for 1 year ( pre op – immediate post op – 6 weeks – 6 months – 1 year).

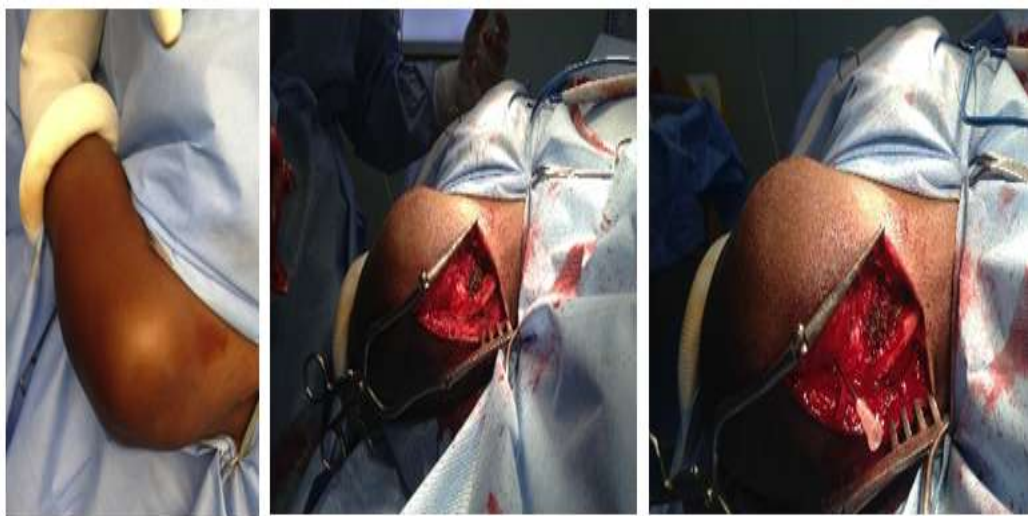

Fig.1. Supine Position

Fig.2. Exposure

Fig.3. Ac Joint Demarcation

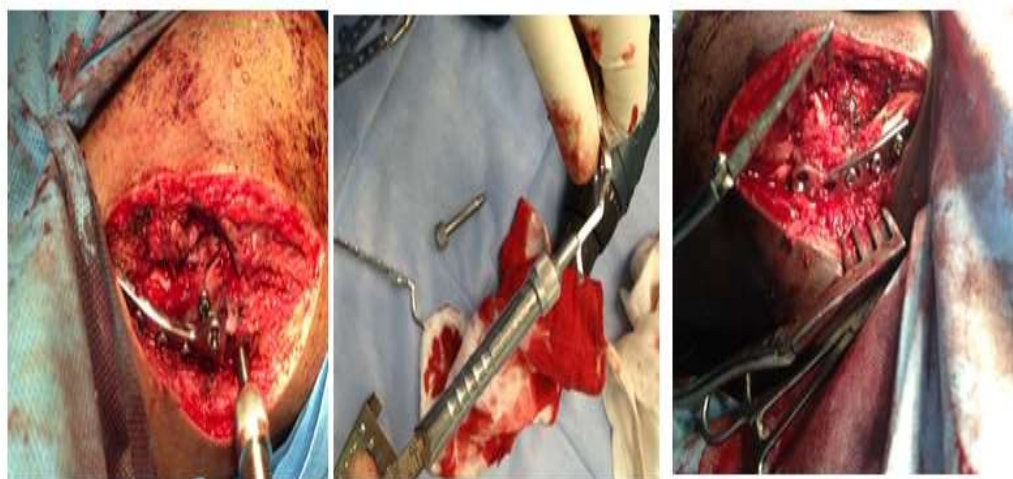
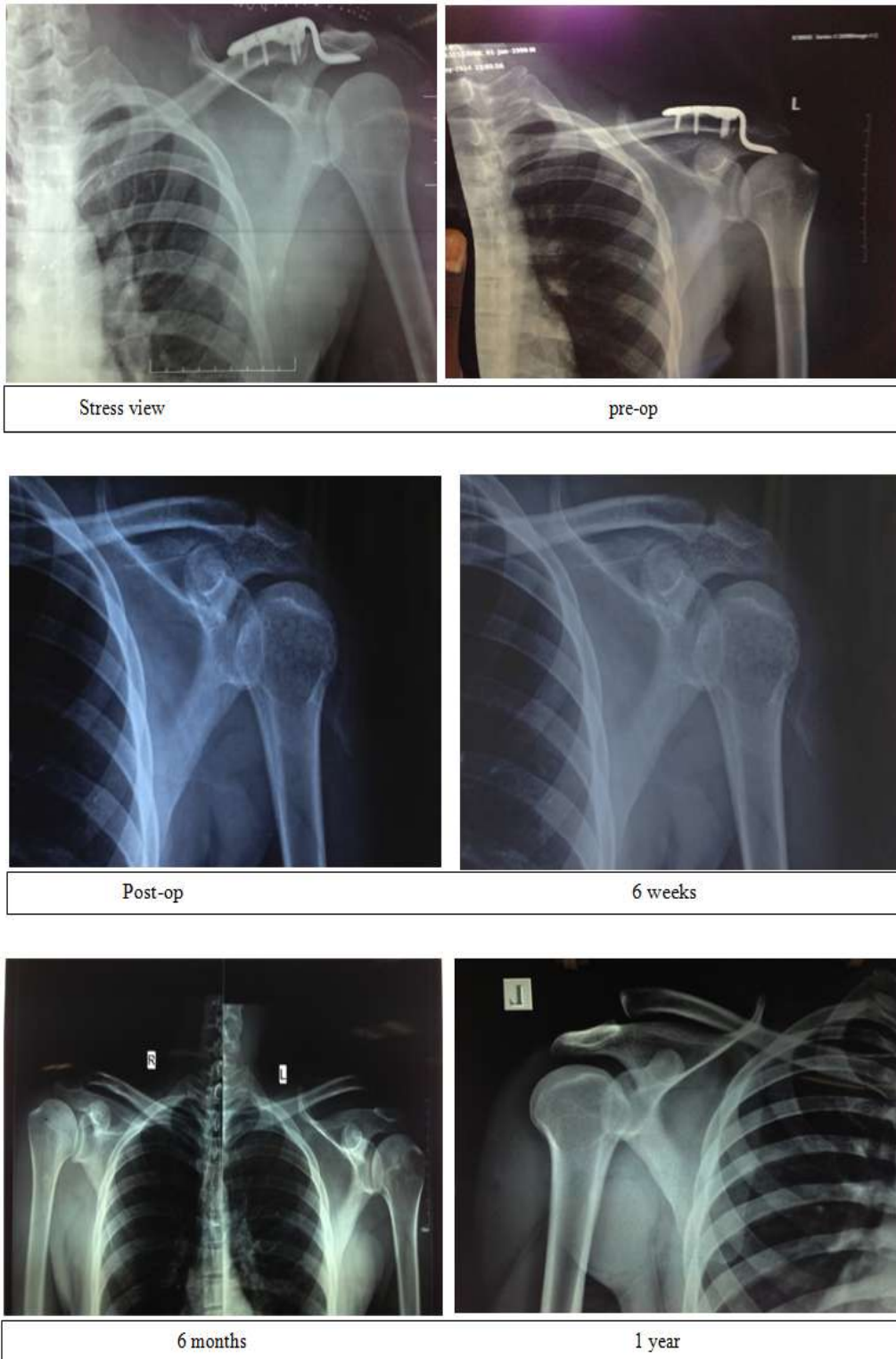


Fig.4. Intra Operative Measurement

Fig.5. Hook Depth

Fig.6. Hook Plate Fixation of Acromion depth



### III. Results

Follow up of 15 patients for a period of 1 year using PENN score and Constant score in which we observed PENN score showed Excellent results in 86.66%(13 Cases) Good in 6.66%(1 Case) , Fair in 6.66%(1 case) and Constant score had excellent results in 93.33%(14 cases) and Fair in 6.66%( 1 case), there was no bad scoring in both PENN score and Constant score. 1 patient had subacromial osteolysis on 6 months post-op. this did not have any clinical implication but implant was removed. 1 patient developed impingement and had restriction of shoulder movements hence implant was removed

#### IV. Conclusion

Acromio-clavicular joint injuries can be effectively treated by hook plate application. Using appropriate size hook can minimise impingement syndrome.

#### V. Discussion

The basic knowledge of shoulder biomechanics is important for diagnosis and treatment of AC joint disorders,[16] Surgical treatment enables restoration of AC joint anatomy such as K- wire fixation ,corococlavicular fixation ,Lateral end plates ,Hook plate fixation ,Weaver dunn procedure, but there may be a complications associated with breakage and / or migration of pins[17].The relative rotatory movements of clavicle during abduction of shoulder cause failure of K-wire fixation and Cancellous screw fixation. The clavicle hook plates is designed to fit anatomically to the Acromion and clavicle,The hook extending from the plate act a lever beneath the acromion. The hook plates allows rotatory movements between acromion and clavicle [18].The main complication with hook plate is that the plate may cause sub-acromial impingement, sub-acromial osteolysis or even rotator cuff tear[19].We sought to determine by measuring the depth between acromion and supra spinatus tendon intra operatively and fixed with appropriate hook plates to prevent sub acromial impingement and sub acromial osteolysis.Few complication was noted in our study with shoulder impingement in 1 patient which got relieved after removal of hook plate ,Superficial infection was occurred in 1 case on 6 months post-op this did not have any clinical implication but implant was removed.1 patient had pain while sleeping on the affected side but it did not interfere with his daily activity of living. In southindian population it has been found that the average length of acromion is relatively small when compared with western population from an on going study in our institute,Hence the depth of the hook of the hook plate should be around 12mm to avoid impingement of the shoulder .When used properly we are getting excellent results.Most of the patients was able to go back to their previous job and activity without any functional disability.

#### Reference

- [1]. Adams FL. The Genuine Works of Hippocrates vols. 1 and 2. New York: William Wood; 1986.
- [2]. Arenas AJ, Pampliega T, Iglesias J. Surgical management of bipolar clavicular dislocation. *Acta Orthop Belg.* 1993;59:202–205.
- [3]. Trainer G, Arciero RA, Mazzocca AD. Practical management of grade III acromioclavicular separations. *Clin J Sport Med.* 2008;18(2):162–166. doi: 10.1097/JSM.0b013e318169f4c1.
- [4]. Motta P, Bruno L, Maderni A, et al. Acromioclavicular motion after surgical reconstruction. *Knee Surg Sports Traumatol Arthrosc.* 2012;20(6):1012–1018. doi: 10.1007/s00167-011-1627-5.
- [5]. Mazzocca AD, Arciero RA, Bicos J. Evaluation and treatment of acromioclavicular joint injuries. *Am J Sports Med.* 2007;35(2):316–329. doi: 10.1177/0363546506298022.
- [6]. Fraser-Moodie JA, Shortt NL, Robinson CM. Injuries to the acromioclavicular joint. *J Bone Joint Surg Br.* 2008;90(6):697–707. doi: 10.1302/0301-620X.90B6.20704.
- [7]. Rockwood CA. Injuries to the acromioclavicular Joint. In: Rockwood CA, Green DP, editors. *Fractures in adults* vols. 1, 2. Philadelphia: JB Lippincott; 1984.
- [8]. Rolf O, Hann von Weyhern A, Ewers A, Boehm TD, Gohlke F. Acromioclavicular dislocation Rockwood III–V: results of early versus delayed surgical treatment. *Arch Orthop Trauma Surg.* 2008;128(10):1153–1157. doi: 10.1007/s00402-007-0524-3.
- [9]. Hootman JM. Acromioclavicular dislocation: conservative or surgical therapy. *J Athl Train.* 2004;39(1):10–11.
- [10]. Tauber M. Management of acute acromioclavicular joint dislocations: current concepts. *Arch Orthop Trauma Surg.* 2013;133(7):985–995. doi: 10.1007/s00402-013-1748-z
- [11]. Rockwood C, Green D, Bucholz R, Heckman J. *Fractures in adults*. 4. Philadelphia: Lippincott-Raven; 1996. pp. 1341–1413.
- [12]. Smith TO, Chester R, Pearse EO, Hing CB. Operative versus non-operative management following Rockwood grade III acromioclavicular separation: a meta-analysis of the current evidence base. *J Orthop Traumatol.* 2011;12:19–27. doi: 10.1007/s10195-011-0127-1.
- [13]. Steinbacher G, Sallent A, Seijas R, Boffa JM, Espinosa W, Cugat R. Clavicular hook plate for grade-III acromioclavicular dislocation. *J Orthop Surg (Hong Kong)* 2014;22(3):329–332.
- [14]. Kashii M, Inui H, Yamamoto K. Surgical treatment of distal clavicle fractures using the clavicular hook plate. *Clin Orthop Relat Res.* 2006;447:158–164. doi: 10.1097/01.blo.0000203469.66055.6a.
- [15]. Yoon JP, Lee BJ, Nam SJ, Chung SW, Jeong WJ, Min WK, Oh JH. Comparison of results between hook plate fixation and ligament reconstruction for acute unstable acromioclavicular joint dislocation. *Clin Orthop Surg.* 2015;7(1):97–103. doi: 10.4055/cios.2015.7.1.97.
- [16]. Mestan MA, Bassano JM. Posttraumatic osteolysis of the distal clavicle: Analysis of 7 cases and a review of the literature. *J Manipulative Physiol Ther* 2001;24:356–61.
- [17]. Larsen E, Bjerg-Nielsen A, Christensen P. Conservative or surgical treatment of acromioclavicular dislocation. A prospective, controlled, randomized study. *J Bone Joint Surg Am* 1986;68:552–5.
- [18]. Senna, A.S.A. (2012) Hook Plate for Displaced Neer Type 2 Lateral End Clavicular
- [19]. Fractures. *AAMJ*, 10, No. 3.
- [20]. 19.Odak, S. and Burton, D. (2010) Early Acromial Erosion with the Syntheshookplate:An Unusual Complication and Its Treatment. *Shoulder and Elbow*.

\* Asst prof Dr. Senthil Loganathan. "Functional Outcome of Acromioclavicular Dislocation Treated By Hook Plate." *IOSR Journal of Dental and Medical Sciences (IOSR-JDMS)* 16.11 (2017): 29-32