

Recurrent Glomus Tumour of Great Toe, a rare site

*Dr. Swamynadh P¹, Dr. Akshay Singh², Dr. Avinash², Dr. Shekar Y. Tati³,

Dr. Mridula S⁴

¹Assistant Professor, ²Post graduate, ³Professor Department of General Surgery,

⁴Professor Department of Pathology. MediCiti Institute of Medical Sciences, Ghanpur,
R.R District, Telangana State, India.

Corresponding Author: *Dr. Swamynadh P¹

Abstract: Glomus tumor is a benign tumour arising from the neuromyoarterial plexus concentrated beneath the nail and arises from digital Glomus body. It is more common in females, however extra digital tumours are common in males. It is common in elderly, but can occur in young individuals. Exact aetiology is not known. Common sites within the nail unit are the nail bed, subungual region, nail root and laterally.

A 60 year old woman presented with slow growing swelling on the dorsal aspect of great toe for 5years. It was 4X3 cm in size, lying over extensor hallucis longus tendon. It was hard in consistency, lobulated surface with a small cystic area where a discharging puncture wound was present and the discharge was scanty and serosanguinous. The swelling was moving freely side to side with restricted vertical mobility and not moving when tendon was made taut. Skin over the swelling was slightly bluish black in colour. Mild tenderness was present over the swelling. Our provisional diagnosis was calcified ganglion or gouty nodule.

The tumour was excised under spinal anaesthesia and specimen sent for histopathological examination (HPE) and it was reported as glomus tumour. We wish to report this case because of its rare site of presentation. On intense search of the literature, no case was found to be reported from great toe that too the tumour lying on extensor hallucis longus tendon. We made a wrong diagnosis because of its rare site.

Keywords: Glomus tumour, Histopathological examination (HPE), ultra sonogram (USG), magnetic resonance Imaging (MRI)

Date of Submission: 29 -08-2017

Date of acceptance: 16-11-2017

I. Introduction

Glomus tumour is a neuromyoarterial tumour arising from Glomus bodies. These plexus are an arteriovenous anastomosis functioning without intermediary capillary bed. Glomus tumor was first described by Wood as early as 1821, but the characteristic histological description was given by Masson [1]. Masson compared the tumour with the normal glomus body and suggested that the lesion is representing hyperplasia or overgrowth of this structure. These tumours are relatively rare, accounting for 5.5% of nail unit tumors [2]. The tumour is more common among women, however, extra digital glomus tumours are more common in males. It is common in elderly people above the age of 50yrs however young people can also be affected. The most common site is the distal extremities, particularly in the subungual digital areas however, extra digital tumours are reported on the bone, tongue, stomach, rectum, mesentery, lung, mediastinum, sacrum, coccyx, and the head and neck. No single imaging technique is helpful in the diagnosis of glomus tumour since plain radiograph, USG or MRI do not cast specific images, however, it has been claimed that MRI is useful in recurrent disease. Excision biopsy is both diagnostic and curative.

II. Case report

A 60 year old woman presented with a slow growing swelling on the dorsal aspect of the great toe for 5years. Patient was complaining of pain at the site of the swelling. Pain was localized, pricking in nature. The patient underwent excision of the swelling 4 years ago, but swelling recurred within 6 months following excision.

The tumour size was 4x3 cm, lying over Extensor Hallucis Longus tendon. Mild tenderness was noted on palpation and no local rise of temperature was noted. It was hard in consistency, with a lobulated surface and a small cystic area where a small discharging wound was present. The discharge was scanty and serosanguinous. The swelling was moving freely side to side with restricted vertical mobility and not moving when the tendon was made taut. Skin over the swelling was little bluish black in colour. No change in colour of the nail or nail bed. Calcified ganglion or gouty nodule was our provisional diagnosis.

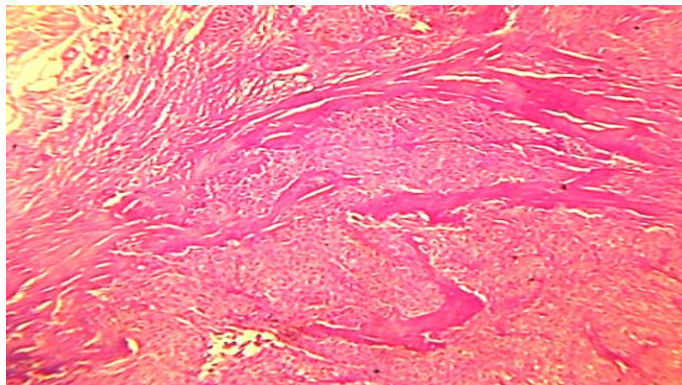
Plane radiograph of the great toe with tumour mass was taken, and showed no bony involvement. Serum Uric acid levels were found to be normal (2.5mg/dl). Other investigation like USG and MRI was not done as the tumour does not carry any specific images to help the diagnosis.

The tumour was excised under spinal anaesthesia. Specimen sent for histopathological examination (HPE) (fig.1).

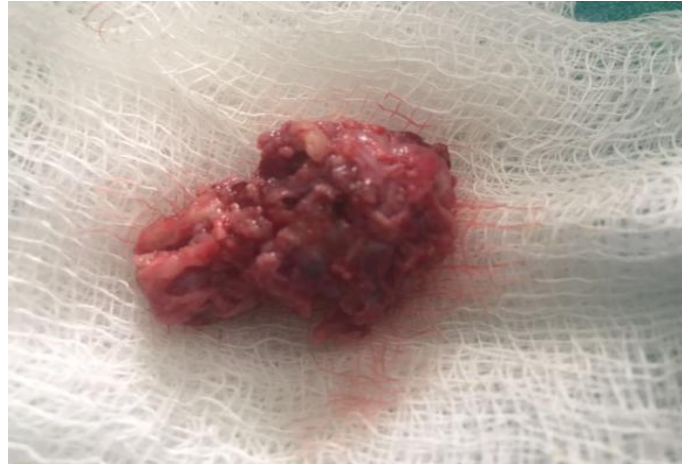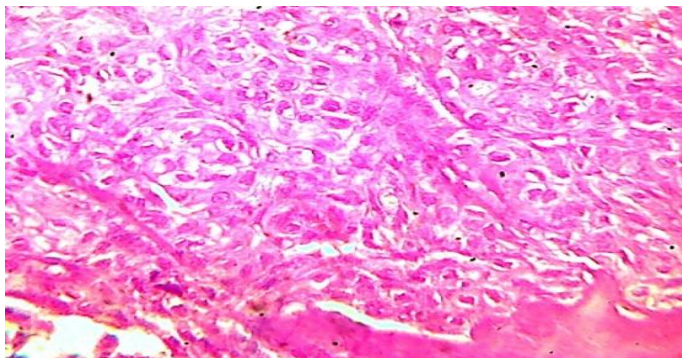


Fig.1.single grey white to grey brown soft tissue mass measuring 3x2x1cms with an irregular surface. Cut section shows grey brown areas. All the tissue was processed.

The gross specimen was measuring 3x2x1cm, surface was irregular, firm to hard in consistency. On cut section the specimen was showing grey white to grey brown areas. Microscopic picture was showing fibrocollagenous and adipose tissue with numerous blood vessels. The tumour cells were arranged in sheets having round to oval vesicular nucleus. Moderate amount of cytoplasm is seen which is pale and eosinophilic. Focal areas show clear cytoplasm without lining of cells. Numerous capillary sized blood vessels were seen with bundles of collagen. Periphery of the tumour was showing numerous blood vessels with perivascular neoplastic cells. No cellular atypia and mitotic figures. The features were suggestive of glomus tumour (fig.2&3).



(Fig. 2) Stained section shows numerous branching vascular channels separated by fibrocollagenous stroma containing glomus cells. No mitotic figures and cytologic atypia noted



(Fig.3) Section in high power field

III. Discussion

Glomus tumour arises from the neuromyoarterial plexus concentrated beneath the nail and nail bed [1]. These plexus are an arteriovenous anastomosis functioning without intermediary capillary bed. Glomus tumour was first described by Wood as early as 1821, but classical histological description was given by Masson [2]. Masson compared the tumour with the normal glomus body and suggested that the lesion is due to hyperplasia or overgrowth of this glomus body [3] which usually occurs at the nail bed located in the subcutaneous tissue, which is responsible for the regulation of temperature and blood pressure. It is a rare tumour representing 5.5% of all nail unit tumours and 1.6% of all soft tissue tumours [4]. They are usually solitary but a multiple glomus tumour syndrome has been described that is transmitted in an autosomal dominant pattern. It is more common in females [5], however extra digital tumours are more common in males [6]. It is common in elderly, in the fourth and fifth decades of life, but can occur in young individuals. Exact etiology of this condition is not known. The common preferred site is the digital glomus body, but it can occur in extra digital areas like hands, feet and forearm, infact it can occur anywhere in the body. 75% of glomus tumours occur in the hand, and 68% are located in the subungual region, nail root and laterally. The most common site in one study was the reticular dermis of nail bed [7].

The glomus tumour classically presents as a triad of symptoms of pain, point tenderness and sensitivity to cold [3]. It is a solitary tumour that clinically presents as a painful nodule with deep blue to purple in colour. Patient feels more pain when exposed to cold water [8,9]. The pain mechanism is not clearly known however, nerve fibres containing immunoreactive Substance P (SP) are identified in glomus tumours, which is a pain-related peptide that acts as the main afferent pain transmitter [10]. In our case it is a less common site, on the medial side of the nail of a great toe. There was mild tenderness noted on manipulation.

It is difficult to diagnose Glomus tumour, located other than common sites. Diagnosis is primarily clinical because it does not yield specific image on plain radiography, magnetic resonance imaging and ultrasonography. MRI is useful in recurrent cases [7]. In our case, it was not advisable to think that it was a ganglion since it was located on the extensor hallucis longus tendon. Treatment involves complete surgical excision. Most commonly, excision biopsy is required due to improper clinical diagnosis and lack of specific images on imaging techniques. Histologically, the tumour is composed of sheets and a nest of uniform and round cells, interrupted by vessels of varying size. Tumour cells exhibit punched-out and hyperchromatic nuclei and pale cytoplasm. Certain areas have an organoid or epithelioid growth pattern. A dense fibrous pseudocapsule surrounds the solid sheet of tumour cells. The tumour cells are immunoreactive for smooth muscle actin (SMA) and vimentin (VMT).

IV. Conclusion

60 year old woman presented with a swelling on the great toe over the Extensor Hallucis Longus. We diagnosed it as Gouty nodule or calcified ganglion. Excision was done. Specimen sent for HPE. HPE reported as Glomus tumour, which is an uncommon site for Glomus tumour. Glomus tumour is a benign tumour arising from the neuromyoarterial plexus concentrated beneath the nail and arises from digital glomus body. It commonly arises from the nail unit. Extra nail unit glomus tumours can arise anywhere in the body. The tumour is more common in elderly woman however, can occur at any age. Extra digital glomus tumours are more common in males. The tumour commonly presents with pain and tenderness having sensitivity to cold. Excision biopsy is curative and diagnostic. Imaging investigations does not help in diagnosis because they do not give any specific image. However, MRI helps in diagnosis of recurrent Glomus Tumours.

Acknowledgements

Reference

- [1]. Banavasi S Girisha, Manjunath M Shenoy, Michelle Mathias, and Rajashekar Mohan; Glomus tumor of the nail unit.
- [2]. Heys SD, Brittenden J, Atkinson P, Eremin, Glomus tumour: an analysis of 43 patients and review of the literature; *O Br J Surg*. 1992 Apr; 79(4):345-7.
- [3]. Weiss SW, Goldblum JR, editors. *Enzinger and Weiss's Soft Tissue Tumors*. 5th edition. Mosby; Maryland Heights, MO:2007. Perivascular tumors; pp. 751-756
- [4]. Domínguez-Cherit J, Chanussot-Deprez C, Maria-Sarti H, Fonte-Avalos V, Vega-Memije E, Luis-Montoya P; Nail unit tumors: a study of 234 patients in the dermatology department of the "Dr Manuel Gea González" General Hospital in Mexico City. *Dermatol Surg*. 2008 Oct; 34(10):1363-71
- [5]. Lee DW, Yang JH, Chang S, Won CH, Lee MW, Choi JH, Moon KC, Clinical and Pathological characteristics of extradigital Glomus tumors: a retrospective comparative study. *J EUR ACAD Dermatol Venereol*. 2011;25:1392-1397
- [6]. Beaton LI, Davis L. Glomus tumor: report of three cases and analysis of 271 recorded cases. *Q Bull Northwest Univ Med School*. 1941;15:245-273.
- [7]. Drapé JL, Idy-Peretti I, Goettmann S, Wolfram-Gabel R, Dion E, Grossin M, Benacerraf R, Guérin-Surville H, Bittoun ; Subungual glomus tumors: evaluation with MR imaging. *J Radiology*. 1995 May; 195(2):507-15

- [8]. Vasisht B, Watson HK, Joseph E, Lionelli GT ; Digital glomus tumors: a 29-year experience with a lateral subperiosteal approach. *Plast Reconstr Surg.* 2004 Nov; 114(6):1486-9.
- [9]. Bhaskaranand K, Navadgi BC; Glomus tumour of the hand. *J Hand Surg Br.* 2002 Jun; 27(3):229-31
- [10]. Kishimoto S, Nagatani H, Miyashita A, Kobayashi K. Immunohistochemical demonstration of substance P-containing nerve fibres in glomus tumors. *Br J Dermatol.* 1985;113:213–218

*Dr. Swamynadh P. "Recurrent Glomus Tumour of Great Toe, a rare site." *IOSR Journal of Dental and Medical Sciences (IOSR-JDMS)* 16.11 (2017): 47-50