

## A Rare Case of Lumbar Hernia – A Case Report

Dr B.K.Sharma<sup>1</sup>, Dr Tushar Bhati<sup>2</sup>

<sup>1</sup>Professor and Head, Department of General Surgery, Mahatma Gandhi Medical College and Hospital, Jaipur.

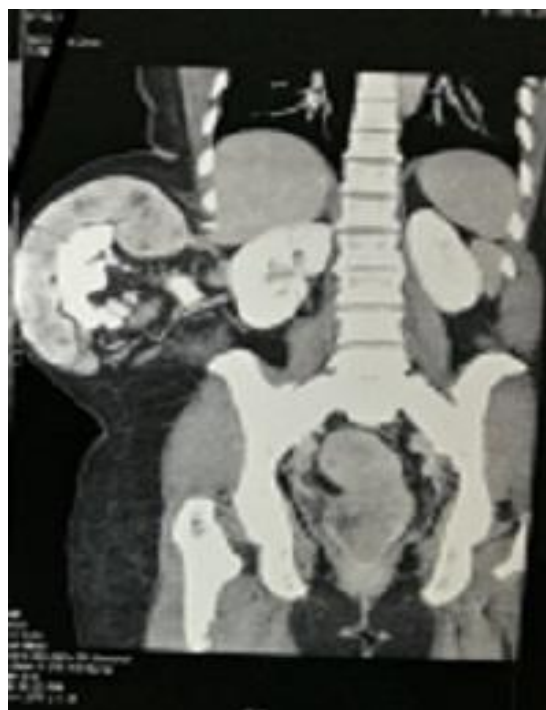<sup>2</sup>P.G Resident, Department of General Surgery, Mahatma Gandhi Medical College and Hospital, Jaipur.  
Corresponding author: Dr Tushar Bhati,

### I. Introduction

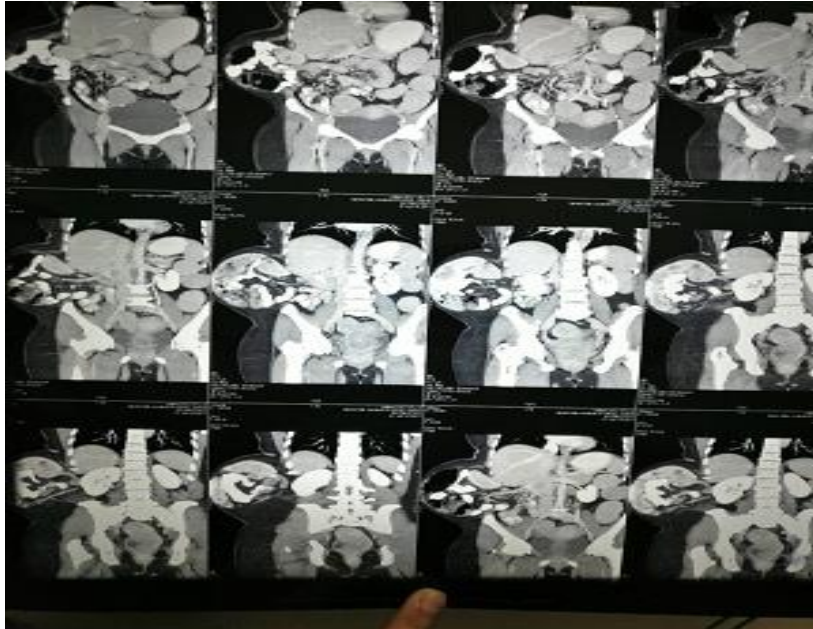Hernia is undoubtedly one of the most common cases dealt by surgeons all over the world. Of the various type of abdominal hernias, the most unique are arguably the lumbar hernias<sup>1</sup>. They are quite uncommon as compared to other ventral abdominal wall hernias, accounting for less than 1.5% of the abdominal hernias with approximately only 300 cases reported in the literature over the past 300 years<sup>2</sup>. First described by Barbet in 1672 and the first case was reported by Garangoet in 1731<sup>3</sup>.

### Case Report

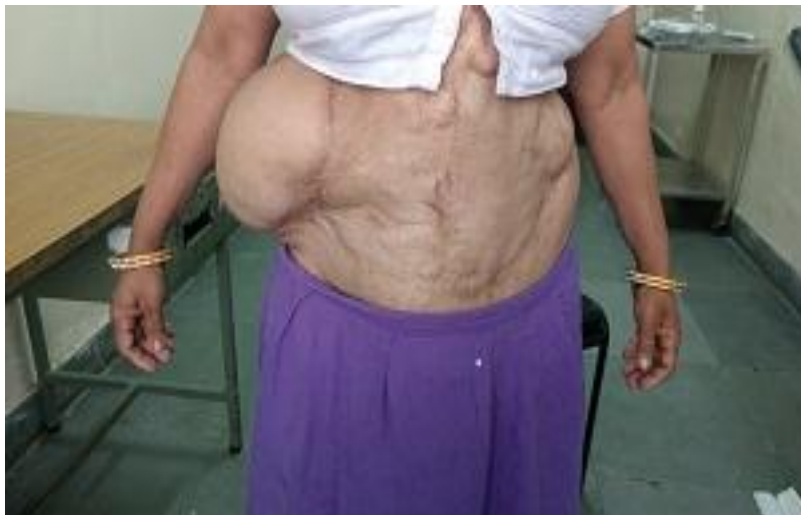A 55 years old female presented in surgery OPD of MGMCH with complaints of pain abdomen with a large swelling on right lumbar region. Patient had history of blunt trauma abdomen 17 years back and had avulsion injury abdomen with hemoperitoneum and posterior dislocation of hip for which she underwent exploratory laparotomy with reduction of hip dislocation and debridement and skin split grafting for avulsion skin of anterior abdominal wall. Clinical examination revealed slight abdominal pain but no guarding and rigidity and a lump was palpable in right lumbar region. Routine haematology came out to be normal. USG abdomen revealed thinning of lateral abdominal wall with protrusion of intestinal contents through it. CECT whole abdomen revealed a large defect of 9 cm in the posterior abdominal wall in right lumbar region with small bowel loops, mesenteric fat, ascending colon and superior mesenteric vessels herniated through it. The patient was taken for open hernia repair. Abdomen was opened by curved incision in left lateral position.. Lumbar hernia was present with defect of size of approx 10 cm. Contents were preperitoneal fat, bowel loops. Lumbar hernia reduced and repaired by polypropylene mesh. Post op was uneventful. There is slight skin flap necrosis present in suture line which was managed conservatively and patient was discharged satisfactorily on 5th post operative day.



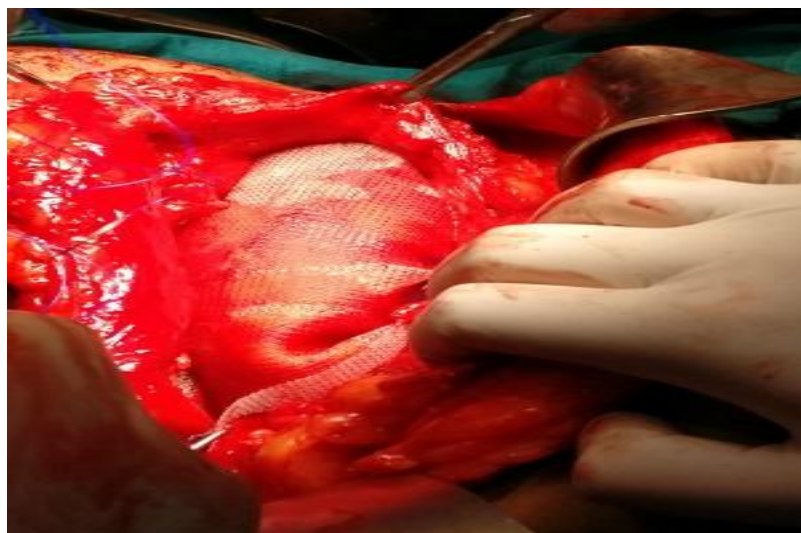
CT Scan showing large defect in Lumbar region.



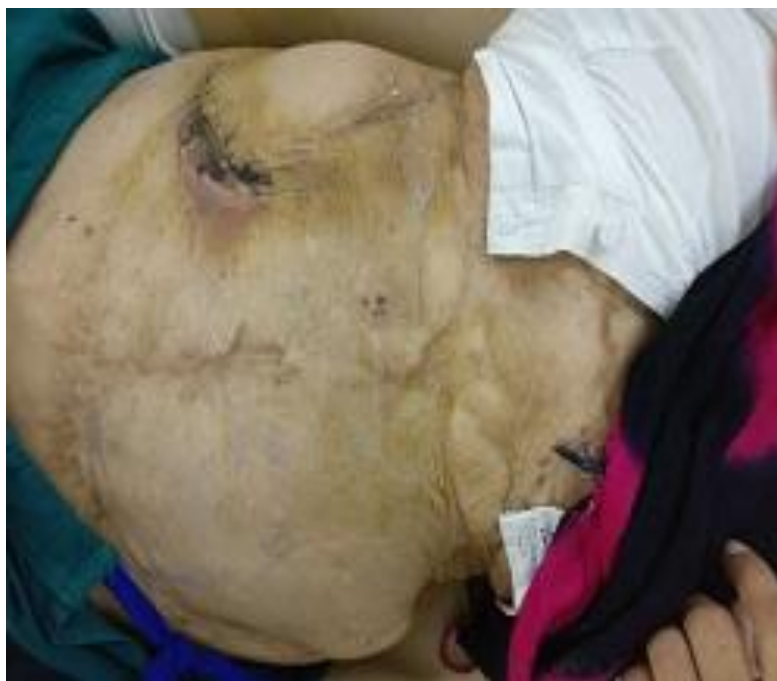**CECT Scan of Abdomen showing lumbar hernia defect**



**Pre Op Image of Patient**



**Intra Op Image showing Mesh replacement**



**Post Op image of Patient**

## **II. Discussion**

Lumbar hernia is a rare type of abdominal hernia due to a defect in the posterolateral abdominal wall through which either intraperitoneal or extraperitoneal contents protrude. A detailed description of historical background of this rare disease is dealt by Alfredo MorenoEgea et al. The two most common anatomical locations of lumbar hernias are the superior and inferior lumbar triangles, whose boundaries have been well described. The superior triangle, which was first described by Joseph Grynfeldt in 1866, is bordered superiorly by the inferior edge of the 12th rib and the serratus posterior inferior muscle, laterally by the internal oblique, and medially by the quadratus lumborum. In 1783 Jean Louis Petit described the inferior lumbar region as bound by the latissimus dorsi, the free margin of the external oblique, and the superior edge of the iliac crest. The floor of the triangle is composed of lumbodorsal fascia and the transversalis abdominus muscle aponeurosis. Lumbar hernias have been classified as congenital (20%) or acquired (80%). An acquired hernia may be primary or secondary. Secondary lumbar hernias are of traumatic or post-surgical (flank incisions, renal surgery, iliac bone harvesting) etiology comprising about 25% of acquired hernias<sup>4</sup>. Another way of classifying lumbar hernia is on the basis of content, they are of two types: extraperitoneal hernia with no sac, containing only fat or sliding retroperitoneal organs (paraperitoneal), and peritoneal hernia that may include intraperitoneal organs such as small bowel, omentum, ovary and stomach.

Diagnosis of Lumbar hernia needs a high clinical suspicion. In most of the times the patients are usually asymptomatic, but sometimes may complain of backache, flank pain or a dragging sensation. It is observed that incidences of bowel incarceration may occur in 25% but strangulation is rare because of wide hernial neck<sup>5</sup>. Computed tomography scan is the diagnostic modality of choice. Computed tomography scan is able to delineate muscular and fascial layers, a defect in one or more of these layers, and the presence of herniated fat and/or viscera.

Surgical repair is the treatment of choice. A wide variety of techniques have been described for repair of lumbar hernia. Repair can be done either open or endoscopically. Synthetic mesh for hernia repair has the complications of infection, bowel obstruction and fistula formation. Recently the use of biosynthetic mesh made of human acellular dermis has been used with good results especially in contaminated wounds.

## **III. Conclusion**

Primary lumbar hernia is a rare clinical entity and needs a high index of suspicion during day to day practice. A good history, general physical and radiological examination can rule out most of the differential diagnosis.

This case-study is presented for

1. It's absolute rarity
2. For documentation of types and discussion of management of this rare entity.

### References

- [1]. Russell RC, Norman S. Bailey and Love's Short Practice of Surgery. 25ed. London: Edward Arnold; 2007. p. 983.
- [2]. Alfredo Moreno-Egea, MD; Enrique G. Baena, MD; Miguel C. Calle, MD; Jose Antonio T. Martinez, MD; Jc Luis A. Albasini, MD Controversies in the Current Management of Lumbar Hernias Arch Surg. 2007;142(1):82-88. doi:10.1001/archsurg.142.1.82. JAMA Surgery
- [3]. Pachani AB, Reza A, Jadhav RV, Mathews S. A primary idiopathic superior lumbar triangle hernia with congenital right scoliosis: A rare clinical presentation and management. Int J Appl Basic Med Res 2011 Jan;1(1):60–2.
- [4]. Zinner MJ, Ashley SW. Maingot's Abdominal Operations, 12ed. united states: McGraw Hill Professional; 2012. p. 148–9.
- [5]. Baker ME, Weinerth JL, Andriani RT, Cohan RH, Dunnick NR. Lumbar hernia: diagnosis by CT. AJR Am J Roentgenol 1987 Mar;148(3):565–7.
- [6]. Thorek M. Modern surgical technique. Philadelphia: J.B. Lippincott; 1950.
- [7]. Geis WP, Hodakowski GT. Lumbar hernia. In: Nyhus L, Condon R eds. Hernia. 5ed. Philadelphia: Lippincott Williams & Wilkins; 2001. p. 425–7.
- [8]. Devlin B, Kingsnorth AN. Management of abdominal hernias. 2ed. London: Edward Arnold; 1998. p. 330– 4.
- [9]. Salameh JRSalloum EJ Lumbar incisional hernias: diagnostic and management dilemma. JLSLS 2004;8391- 394 PubMed
- [10]. Light HG Hernia of the inferior lumbar space: a cause of back pain. Arch surg1983;1181077- 1080 PubMed
- [11]. Hide IGPike EEUberoi R Lumbar hernia: a rare cause of large bowel obstruction. Postgrad Heal .1 1999;75231; 2/33 PubMed
- [12]. Losanoff JEKjossev KT Diagnosis and treatment of primary incarcerated lumbar hernia. Eur Surg 2002;168193- 195 PubMed
- [13]. Horovitz ILSchwarz HADeham A A lumbar hernia presenting as an obstructing lesion of the colon. Dis Colon Rectum 1986;29742- 744 PubMed